



## **4V051 Module 2: Ocular Anatomy and Physiology, Ocular Disorders, and Ophthalmic Pharmacology**

There are four lessons contained in Module 2 to include the answers to all of the self-test questions. In the first module, you reviewed information about the 4V0X1 career field, career progression, clinic administration, and supplies. In this second module, you'll explore the anatomy and physiology of the eye, ocular disorders and conditions, injuries and triage, and ophthalmic pharmacology.

Specifically, lesson 1 covers the ocular adnexa, bony orbit, extraocular muscles, internal eye anatomy, visual and pupillary pathways, visual acuity (VA), and the refractive status of the eye. It finishes with depth perception, color vision, and night vision.

Lesson 2 delves first into the basic parts and combined forms of ocular terminology, then discusses various internal and external ocular disorders and conditions.

Lesson 3 covers numerous ocular injuries, eye irrigation, and patching. It then follows those lessons with a discussion on how to triage and prioritize diverse ocular conditions. This lesson is very important because you never know when you might be called upon to help save a patient's sight.

Finally, lesson 4 is all about ophthalmic pharmacology. It begins with the general principles of pharmacology, followed by some of the complications and actions of ophthalmic medications. This leads into the various categories of ocular medications, such as mydriatics, cycloplegics, intraocular-lowering medications, anesthetics, stains, anti-allergic, anti-inflammatory, and anti-infective medications. It ends with a brief overview of medications, vitamins, minerals, and herbal supplements that can be used to enhance the overall health of the eyes.

In myLearning, under the Resources tab, you will find the acronym and glossary of terms listing as well as the Module 2 transcript that you can download.

To get a response to your questions concerning subject matter in this course, or to point out technical errors in this module, knowledge checks, practice exercises, or course examination, please e-mail Air Force Career Development Academy (AFCDA) Support Services at [2AF.AFCDA.SupportServices@us.af.mil](mailto:2AF.AFCDA.SupportServices@us.af.mil) or call commercial: 228-377-7044/DSN: 597-7044, if you have any issues with AFCDA courseware. Do not contact the myLearning help desk. Support Services Hours are: 0730-1630 CST.

**Lesson 1: Ocular Anatomy and Physiology**

**Lesson 2: Ocular Terminology, Conditions, and Disorders**

**Lesson 3 : Ocular Injuries, Treatment, and Triage of Ocular Conditions**

**Lesson 4: Ophthalmic Pharmacology**

**Module 2: Self-Test Question Answers**



# Lesson 1: Ocular Anatomy and Physiology

---

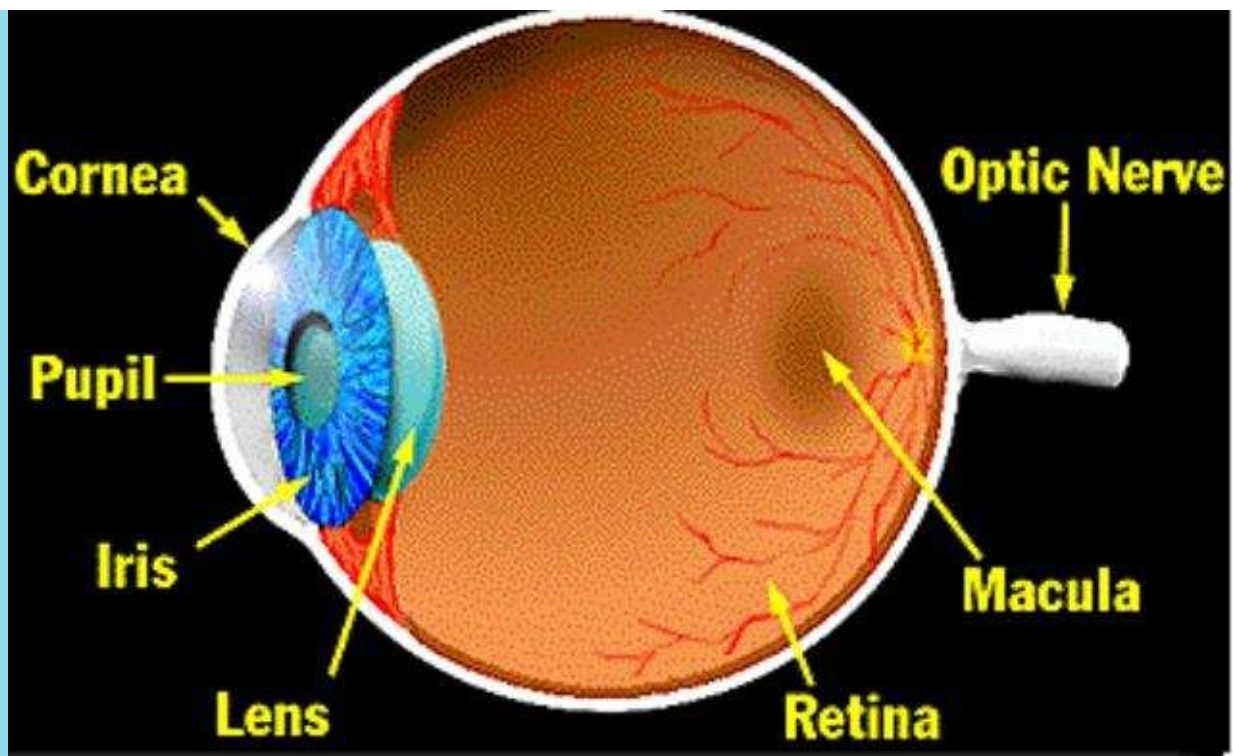
## Main Points

### 1. Ocular anatomy

- a. Ocular adnexa
- b. The bony orbit
- c. Extraocular muscles: origin, insertion, and action
- d. Eyeball anatomy
- e. Visual-pupillary pathway

### 2. Ocular Physiology

- a. Visual acuity and refractive status of the eye
- b. Depth perception, color, and night vision



Anatomy of a normal human eye

CONTINUE

---

They say the eye is the window to the soul. While there is a great deal of debate over the origins of that phrase, there is no debate the eyes truly can reveal many of the body's secrets. Clues to these secrets, such as; premature birth, diabetes, or high blood pressure might be easily overlooked to the untrained eye; however, to the skilled examiner, the clues are there if you know what to look for.

To be a proficient and knowledgeable technician, you owe it to yourself and your patients to understand the anatomy, physiology,

and functionality of the eye. Not only because this information will aid you in identifying abnormalities and diseases, but also because it's pretty interesting too!

[Click here to begin Module 2, Lesson 1.](#)

## Ocular Anatomy

Although you're not authorized to diagnose patients, you'll have many discussions with patients and doctors in which a sound background in ocular anatomy will assist you in being able to relate ocular conditions to symptoms, causes, and treatment. Let's strengthen your ocular anatomy background by starting this section with a discussion of the eyelids and working our way through the eye.

## Ocular Adnexa

The structures surrounding the eyeball fall under the general term ocular adnexa. The ocular adnexa consist of the eyebrows, eyelids, eyelashes, glands, and lacrimal system.

## Eyebrows

The eyebrows are located on the borders of the orbits. They consist of a thickened ridge of skin covered with short hairs. The main purpose of the eyebrow is to divert perspiration from the eye.



## Eyelids

The eyelids are folds of tissue covering the eye itself. Their primary purpose is protection. Eyelids help limit the amount of light entering the eye and aid in keeping out dust, dirt, and other foreign debris. Another important job of the eyelids is to spread tears across the cornea. The blinking action of the eyelids helps to lubricate the cornea and clear it of debris.



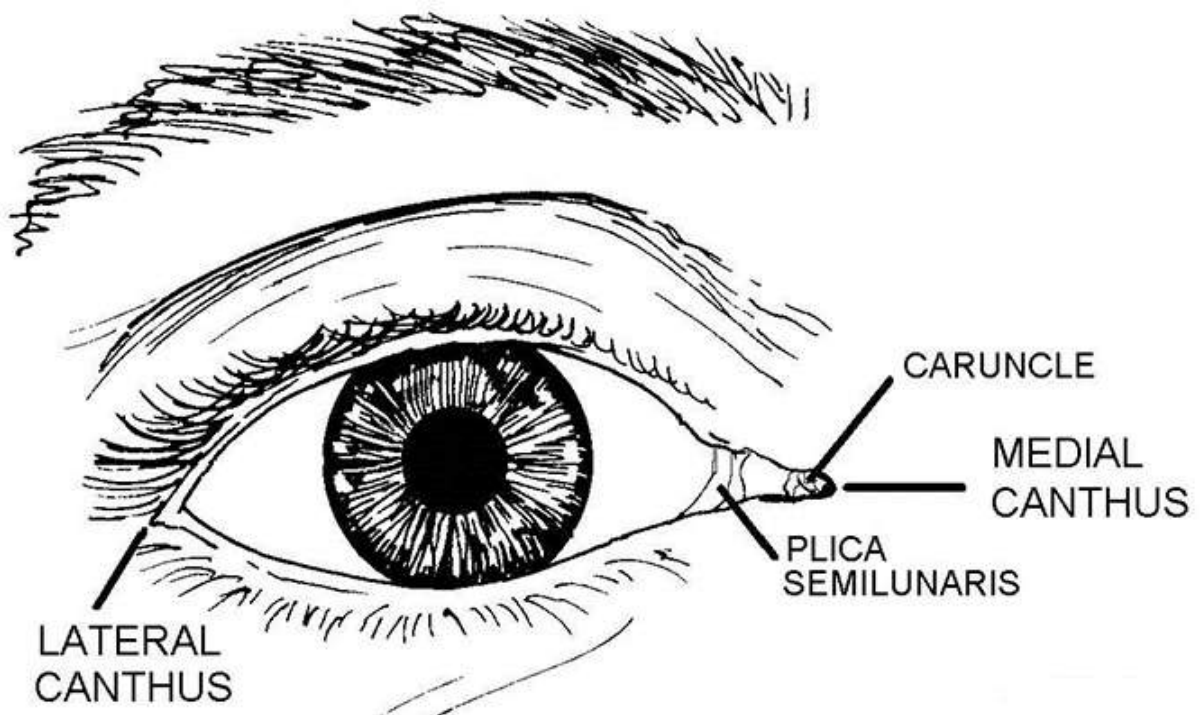
## Landmarks

The lateral canthus, medial canthus, plica semilunaris, and caruncle are the visible anatomical landmarks of the adnexa (see image below). They do not perform any visual function.

The lateral canthus is the meeting point of the upper and lower lids on the temporal side of the eye. The medial canthus is the meeting point on the nasal side. The plica semilunaris and caruncle are located in the medial canthus area, on the sclera.

The plica semilunaris represents the link between the bulbar conjunctiva and muscle tissue. The caruncle is a fleshy mound of tissue located between the plica semilunaris and the medial canthus. It has small hairs (cilia) acting as a trap for debris. The caruncle also contains sebaceous glands producing oil for the tear film.



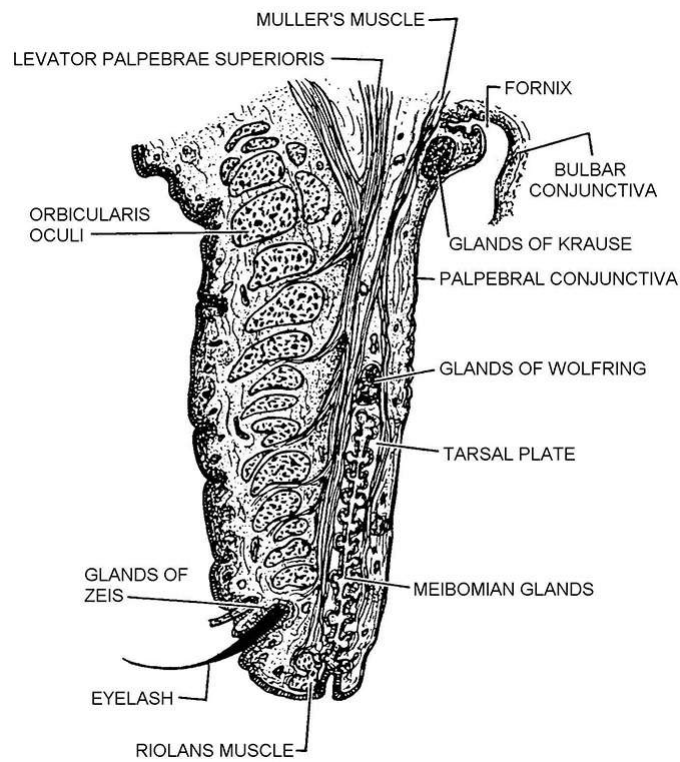


## Muscles —

The eyelids have muscles that open and close them. The levator palpebrae superioris and muscle of Muller open the lids. The levator palpebrae superioris (often just called the levator) originates at the apex (back) of the bony orbit and attaches to the sheath (outer covering) surrounding the superior rectus muscle, and to the tarsal plate (skeleton of the eyelid) and lid margin. The oculomotor (3rd cranial) nerve innervates (activates) the levator. The Muller muscle originates from the levator and attaches to the tarsal plate (see the image below.). This muscle holds the lids open and against the eyeball. It's also the muscle helping to open the lids wider for the surprised look.

The oculomotor (3rd cranial) nerve also innervates the Muller muscle. A way to remember all this is: Muller took the (e) levator to the 3rd floor to work on the (oculo) motor. The orbicularis oculi and Riolan's muscle close the eyelids. The orbicularis oculi originates in the tissue near the medial canthus and lateral canthus. This circular (sphincter) muscle is the primary muscle for closing the eyelids. The facial (7th cranial) nerve innervates the orbicularis oculi and Riolan's muscle.

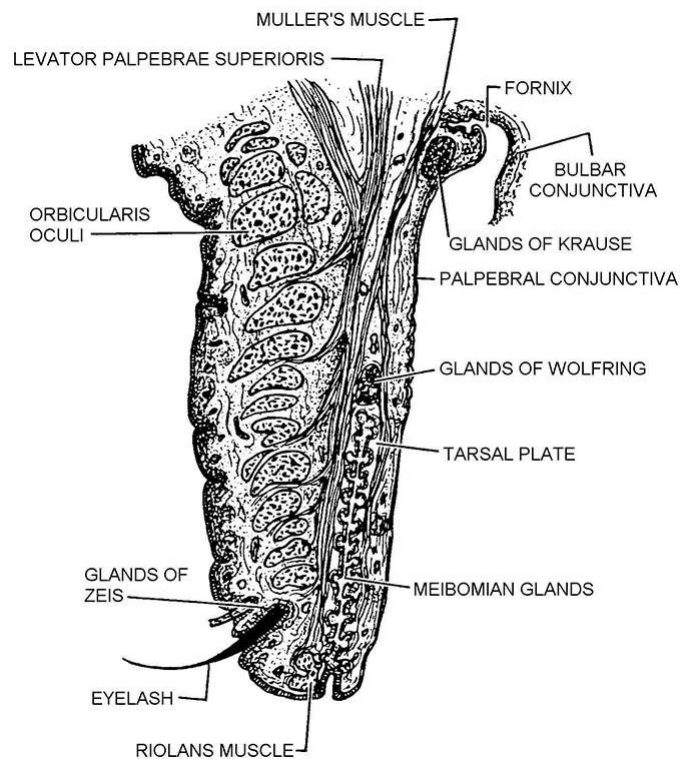
Riolan's muscle is a portion of the orbicularis located at the lid margins between the tarsal plate and lash follicles. Riolan's muscle brings the lid margins together as the lid closes, and holds the lids against the eyeball. A way to remember this is: "If something is suddenly in your face, you'll close your eyes." Orbicularis oculi closes the eye; Riolan's keeps those eyelids closed.



## Tarsal Plate

As already mentioned, the tarsal plate is the point of insertion for the levator palpebrae superioris and Muller's muscle. Also known as the skeleton of the eyelid, the tarsal plate is made up of tough fibrous tissue and is the structure making it possible to evert (turn inside out) the upper eyelid. It's larger in the upper lid than in the lower lid and contains glands that secrete an oily substance.





## Conjunctiva

The conjunctiva is a general term used to identify the layer of protective tissue covering the back surface of the eyelids and front surface of the eyeball. It's anatomically broken down into two parts—palpebral conjunctiva (on the inner eyelids) and bulbar conjunctiva (on the anterior portion of the eyes' sclera). The fornix is the area where the palpebral conjunctiva and the bulbar conjunctiva come together. As you can see, the conjunctiva is really a continuous layer of tissue, some on the inner lid and some on the eye itself. Think of a neighborhood cul-de-sac.

It's important to realize the bulbar conjunctiva does not cover the cornea. It stops at the limbus. Conjunctiva forms a barrier against infection for the eye, much like what our skin does for the rest of our body. Conjunctiva also contains goblet cells that secrete mucin, which is the third component of the corneal tear layer. The other two components of the tear layer are oil and aqueous, which are secreted by the sebaceous and lacrimal glands, respectively.



Complete the content above before moving on.

## Eyelashes

The eyelashes are hairs located on the lid margins. The upper lid has about twice as many lashes as the lower eyelid. Eyelashes form the first line of defense for the eye. A network of super sensitive nerves surrounds each hair follicle. These nerves cause the lids to close quickly if any debris touches the lashes.

## Glands

Each eyelid contains glands secreting oils (sebaceous glands) and tears (lacrimal glands). The glands of Zeis, located at the base of each eyelash, are sebaceous (oil) glands. They secrete an oily material lubricating the eyelashes and keeping the lid margins from sticking together. Some of the oil gets on the eye and mixes with the tear layer.

The meibomian glands are also sebaceous (oil) glands. These are the glands located in the tarsal plate. The oil from the meibomian glands and the glands of Zeis mix with the corneal tear layer and help reduce evaporation of tears.

If an oil gland becomes infected, an external hordeolum or styne can develop.

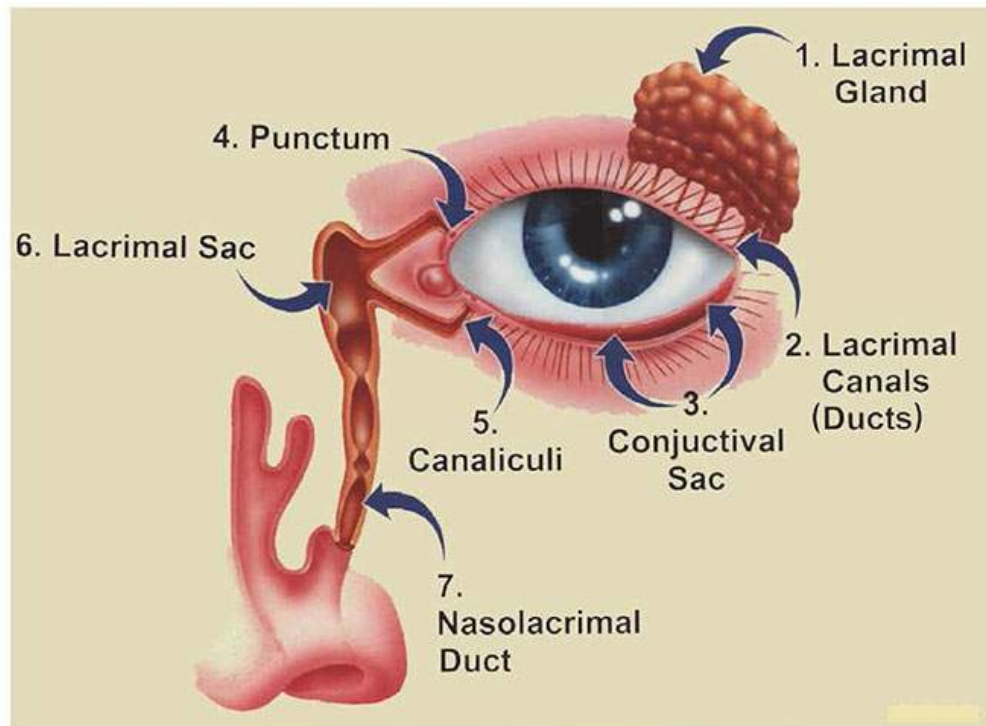
The glands of Krause and Wolfring are accessory lacrimal (tear) glands; they secrete a water-like fluid. They are not your primary tear producers. They help the lacrimal glands (covered shortly). Glands of Krause and Wolfring are located in the palpebral conjunctiva, the innermost layer of the eyelid.

### LACRIMAL SYSTEM

### LACRIMAL SYSTEM CONTINUED

The lacrimal system is comprised of all the structures involved in producing and disposing of tears. Most of the structures in this system are located in or very near the eyelids. The lacrimal system includes the lacrimal gland, lacrimal canals (ducts), conjunctival sac, puncta, canaliculi, lacrimal sac, and nasolacrimal ducts.

The best way to understand the lacrimal system is to follow the journey of a tear. Refer to figure 1–3 below to visualize this process. A tear begins its journey in the lacrimal gland, which is located in the lacrimal gland fossa (located in the superior, temporal portion of the frontal bone, above the eyeball).



#### LACRIMAL SYSTEM

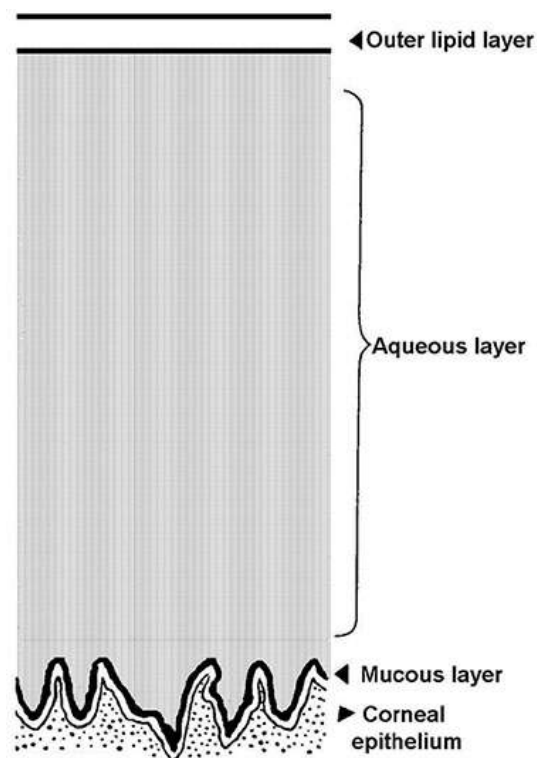
#### LACRIMAL SYSTEM CONTINUED

From there it flows through lacrimal canals (ducts) onto the surface of the eye. It mixes with lacrimal fluid from the accessory tear glands (Krause and Wolfring), oils from the sebaceous glands (meibomian and Zeis), and mucin from the goblet cells of the conjunctiva, and is now a complete tear.

Some of the tear evaporates and the cornea absorbs some of it. Gravity pulls the tear down the eye, where it ends up in the conjunctival sac (fornix area of the lower lid). Suddenly, a blink starts from the lateral canthus, and the upper and lower lids sweep across the eye like two squeegees. A tear spreads across the surface of the cornea, picking up dust and debris along the way. It finally ends up in the medial canthus area, near the puncta (singular is punctum), which are two little holes—one located on the upper lid margin and one on the lower lid margin.

Drawn from the surface of the eye, the tear passes through the puncta. It then drains into little tubes called canaliculi, on its way to the lacrimal sac. Finally, the tear drops into the nasolacrimal duct, flows into the back of the throat, and is swallowed. This is why you can taste your tears. When you cry a lot, after watching something emotional like “Marley and Me” or “Lone Survivor,” your nasolacrimal duct can’t handle all the tears, so they overflow into your nose, making it run.

The makeup of the tear film is vital to the lubrication of the cornea and external globe. Normally the tear film has a mucin, aqueous, and oil layer. Only when all three ingredients are correctly balanced does the cornea receive the proper nutrients.



Complete the content above before moving on.

**Self-Test Questions.** After you complete these questions pertaining to ocular adnexa, you may check your answers at the end of this module.

1. What does the ocular adnexa consist of?

Type your answer here

---

SUBMIT

2. What is the main purpose of eyebrows?

Type your answer here

---

SUBMIT

3. In addition to limiting light and foreign debris, what is another important job of the eyelids?

Type your answer here

---

SUBMIT

4. Name the visible anatomical landmarks of the adnexa.

Type your answer here

---

SUBMIT

5. What are the two muscles that open the eyelids?

Type your answer here

---

SUBMIT

6. What are the two muscles that close the eyelids?

Type your answer here

---

SUBMIT

7. A tough fibrous tissue that makes it possible to evert the upper eyelid is a description of which layer in the eyelid?

Type your answer here

---

SUBMIT

8. Which type of conjunctiva is on the eye itself? Does it cover the cornea also?

Type your answer here

---

SUBMIT

9. What cells does the conjunctiva contain and what do they secrete?

Type your answer here

---



SUBMIT

10. What defense mechanism makes the hair follicles of the eyelashes special?

Type your answer here

---

SUBMIT

11. What do sebaceous glands secrete? Lacrimal glands?

Type your answer here

---

SUBMIT

12. What type of gland is in the tarsal plate?

Type your answer here

---

SUBMIT

13. What happens if an oil gland becomes infected?

Type your answer here

---

SUBMIT

14. Where are the glands of Krause and Wolfring located?

Type your answer here

---

SUBMIT

15. Name the structures of the lacrimal system beginning with the birth of a tear until it gets to the end of the system.

Type your answer here

SUBMIT



Complete the knowledge check questions before moving forward in the lesson.

## The Bony Orbit

The eyeball needs a place to call home. Since it's soft and easily damaged, it needs a solid, protective place--the bony orbit. Several bones make up the bony orbit surrounding the eye.

These bones protect the globe from harm and provide a place for muscle attachment. Without a place for the eye muscles to attach, you would not be able to look around without moving your head.

## The Orbit Form

The bony orbit is a pear-shaped socket. It's big at the anterior (front) and narrows towards the posterior (back). It houses and protects the eyeball, ocular blood vessels, nerves, and fat. The bones surrounding the front opening (aditus orbitae) are exceptionally strong, and logically, provide the majority of the protection.

The medial walls of each orbit run straight back and are parallel to each other. The lateral walls in adults are at 45° angles to the medial wall in each orbit. This being the case, the angle from the lateral wall of one orbit to the lateral wall of the opposite orbit forms a 90° angle. It's pretty interesting that although the


orbits seem to point out to each side, the eyes actually look straight ahead. Each orbit contains the following seven bones:

- Sphenoid (with a greater and a lesser wing)
- Ethmoid
- Lacrimal
- Frontal
- Maxilla
- Palatine
- Zygomatic

An easy way to remember this is **SELF-MPZ**. If each orbit has seven bones, then both orbits together should have 14 bones, right? This makes sense, but is not the case. Between both orbits combined, there are only 11 bones total. This is because the two orbits share three of the bones.

The shared bones are the frontal, ethmoid, and sphenoid. An easy way to remember the three-shared bones is **For (frontal) Each (ethmoid) Side (sphenoid)**.

To analyze the orbit more easily, we break it down into four sides described in the following table (use fig. 1–5 to locate the bones of each wall as you study them).



Four Sides of the Eye Orbit	
Side	Description
Roof	The lesser wing of the sphenoid forms the posterior portion, and the frontal bone forms the anterior portion of the roof. The frontal bone also makes up the major part of the orbital roof. Remember, the lacrimal gland is located in a fossa (dent) in the frontal bone, and the trochlear fossa is another "dent" located in the frontal bone. The trochlear fossa holds the trochlear pulley and will be covered in the section on muscles. A way to remember which bones form the roof of the orbit is to know <u>Light Shines (lesser sphenoid) From (frontal) the roof</u> .
Medial wall	The medial wall is composed of the maxilla, lacrimal, ethmoid, and lesser wing of the sphenoid. The medial wall is the weakest wall in the orbit, because the ethmoid bone (the majority of the medial wall) is paper-thin, and as such, is considered the weakest bone. A way to remember the medial wall is <u>Eat at MELL'S (maxilla, ethmoid, lacrimal, and lesser sphenoid)</u> .
Floor	The maxilla, palatine, and zygomatic are the bones making up the floor of the orbit. The maxilla forms the greatest portion, running from the orbital margin (front edge of the orbit) almost to the apex (most posterior portion) of the orbit. The palatine, the smallest bone in the orbit, forms a very small part of the posterior floor, while the zygomatic forms part of the anterior lateral portion of the floor. A way to remember the makeup of the floor is <u>We MoP (maxilla and palatine) Zee (zygomatic) floor</u> .
Lateral wall	The zygomatic bone forms the anterior portion of this wall, and the greater wing of the sphenoid makes up the posterior portion. The lateral portion of the orbit is most exposed to trauma; so it makes sense the zygomatic, which is the strongest bone in the orbit, makes up the majority of this wall. Since it's such a good strong wall, you can remember it by calling it <u>Zee Great Side (zygomatic greater sphenoid)</u> .

## Four Sides of the Eye Orbit

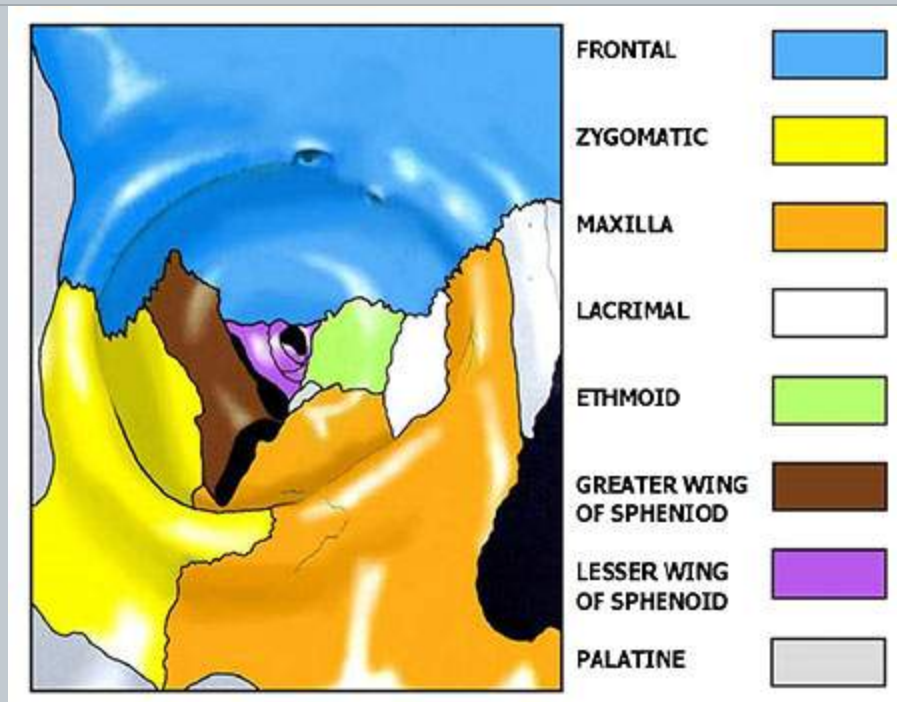


Figure 1-5. The bones of the ocular orbit.

## Fissures and Foramina

Most of the time, bones are not perfectly flat, nor are there seamless transitions from one to the next.

There are numerous openings in the bones of the ocular orbit allowing blood vessels and nerves to enter

and leave. These openings are called fissures (cracks) and foramina (holes). You'll learn about these openings as this lesson moves from the posterior (back or apex) and moves anteriorly to the front of the orbit.

OPTIC FORAMEN	SUPERIOR ORBITAL FISSURE (SPH...	INFERIOR ORBITAL FISSURE	INFRAORBITAL GROOVE/CANAL	ADIT
---------------	----------------------------------	--------------------------	---------------------------	------

The optic foramen is a hole in the lesser wing of sphenoid where the optic nerve (cranial nerve [CN] II) and ophthalmic artery pass through to the orbit. As the optic nerve enters the orbit, part of the nerve sheath (the dura) spreads out and covers the surface of all the bones in the orbit. This tissue is called periorbita, or periosteum, and is a tight-fitting connective tissue.

Think of it as a smooth covering for the bones, providing a firm attachment point for some eye muscles and other tissues. Since you have two eyes, it makes sense you have two optic foramens--one for each eye. Knowing this, you should never forget which CN passes through the optic foramen.

**Think two eyes = two optic foramens = CN II, the optic nerve.**

OPTIC FORAMEN	SUPERIOR ORBITAL FISSURE (SPH...	INFERIOR ORBITAL FISSURE	INFRAORBITAL GROOVE/CANAL	ADIT
---------------	----------------------------------	--------------------------	---------------------------	------

The superior orbital fissure is a crack between the greater and lesser wings of the sphenoid. The superior orbital fissure is the entry site of the orbit for the 3rd (oculomotor), 4th (trochlear), 5th (naso-ciliary division), and 6th (abducens) CNs. It's also the exit site for the superior ophthalmic vein.

OPTIC FORAMEN	SUPERIOR ORBITAL FISSURE (SPH...	INFERIOR ORBITAL FISSURE	INFRAORBITAL GROOVE/CANAL	ADIT
---------------	----------------------------------	--------------------------	---------------------------	------

The inferior orbital fissure separates the lateral wall and the orbit floor. It starts out as a crack and becomes covered by bone, turning it into a canal, which begins on the floor at the junction of the greater wing of the sphenoid and the maxilla. The inferior orbital artery passes through this crack/canal.

OPTIC FORAMEN	SUPERIOR ORBITAL FISSURE (SPH...	INFERIOR ORBITAL FISSURE	INFRAORBITAL GROOVE/CANAL	ADIT
---------------	-------------------------------------	-----------------------------	------------------------------	------

The infraorbital groove starts beneath and temporal to the back of the orbit, and travels forward almost to the orbital margin. The maxilla bone covers the anterior portion, at which point it becomes the infraorbital canal. It should be pointed out the amount of maxillary bone covering the groove/canal is quite thin, and is the most likely portion of bone to break in the event of blunt trauma to the eye. This breakage of bone from blunt trauma is called a blowout fracture.

The other bone likely to break in the event of a blunt trauma is the ethmoid bone, which is considered to be the weakest bone in the orbit, as it is almost paper-thin. The problem with blowout fractures is they can sometimes cause the extraocular eye muscles to become trapped, resulting in pain and diplopia (double vision).

OPTIC FORAMEN	SUPERIOR ORBITAL FISSURE (SPH...	INFERIOR ORBITAL FISSURE	INFRAORBITAL GROOVE/CANAL	ADIT
---------------	-------------------------------------	-----------------------------	------------------------------	------

The aditus orbitae is the largest opening of the orbit. This is the opening at the front of the orbit the eye peers out of.



Complete the content above before moving on.

## Fossa

Fossae are hollowed or depressed areas in bones. It's easiest to think of fossa as "dents" in bones. While not a hole or a crack, fossae are important in accommodating various structures around the eye (e.g., lacrimal gland and trochlear pulley).

### Lacrimal Sac Fossa



The lacrimal sac fossa is located in the lacrimal bone. It holds the lacrimal sac and nasolacrimal duct in place.

### Lacrimal Gland Fossa —

The fossa for the lacrimal gland is hidden behind the orbital rim (front edge) of the superior, temporal portion of the frontal bone. This fossa houses the lacrimal gland and is somewhat almond shaped.

### Trochlear Fossa —

The trochlear fossa is located in the superior, nasal portion of the frontal bone. This depression provides an attachment point for the trochlear pulley. You'll learn about the trochlear pulley in the next section, which covers extraocular muscles (EOM).



Complete the content above before moving on.

**Self-Test Questions. After you complete these questions pertaining to the bony orbit, you may check your answers at the end of this module.**

1. What is the shape of the bony orbit?

Type your answer here

SUBMIT

2. In what position do the medial walls run in relation to each other?

Type your answer here

---

SUBMIT

3. In adults, what angle is formed between the medial wall and lateral wall of the bony orbit?

---

☐

50°

☐

90°

☐

45°



20°

SUBMIT

4. In adults, what angle is formed by the lateral wall of one orbit to the lateral wall of the other orbit?

---



50°



90°



45°



20°

SUBMIT

5. Select the seven bones contained in each orbit of the eye.

---

☐

Sphenoid

☐

Optic canal

☐

Frontal

☐

Ethmoid

☐

Optic Nerve

☐

Lacrimal

☐

Maxilla

☐

Palatine

☐

Zygomatic

☐

Superior bone

SUBMIT

6. Name the bones of the roof of the orbit.

Type your answer here

SUBMIT

7. Select the four bones of the medial wall of the orbit.

☐

Lesser sphenoid

☐

Frontal

☐

Ethmoid

☐

Lacrimal

☐

Maxilla

☐

Palatine

☐

Zygomatic

SUBMIT

8. Select the three bones of the floor of the orbit.

---

☐

Palatine

☐

Lesser sphenoid

☐

Frontal

☐

Zygomatic

☐

Ethmoid

☐

Maxilla

☐

Lacrimal

SUBMIT

9. Select the bones of the lateral wall of the orbit.

---

☐

Palatine

☐

Greater sphenoid

☐

Frontal

☐

Zygomatic

☐

Ethmoid



☐

Maxilla

SUBMIT

10. Select the weakest orbital bone. The Strongest. The Smallest.

---

☐

Maxilla

☐

Ethmoid

☐

Zygomatic

☐

Frontal

☐

Palatine

SUBMIT

11. Select the two types of openings in the bony orbit.

---

☐

Maxilla

☐

Fissures (cracks).

☐

Optic canal.

☐

Foramina (holes).

SUBMIT

12. What passes through the optic foramen in the lesser wing of the sphenoid?

Type your answer here

---

SUBMIT

13. Where is the superior orbital fissure located?

Type your answer here

---

SUBMIT

14. Which bone, or portion of bone, is the most likely to break (a blowout fracture) due to a blunt trauma to the eye?

Type your answer here

---

SUBMIT

15. Name the three primary fossa of the bony orbit and their locations.

---

☐

Lacrimal sac fossa located in the lacrimal bone.

☐

The annulus of the ocular orbit.

☐

Trochlear fossa located in the superior, nasal portion of the frontal bone.

☐

Lacrimal gland fossa located behind the orbital rim of the superior, temporal portion of the frontal bone.

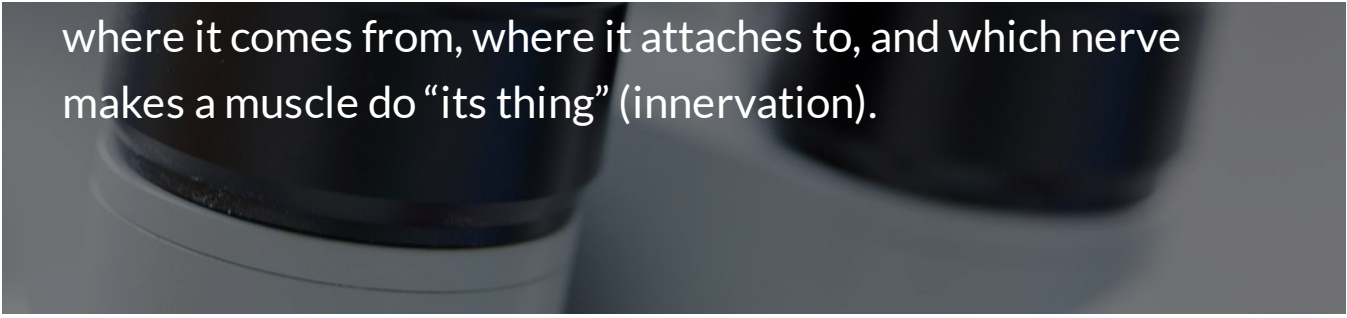
SUBMIT



Complete the knowledge check questions before moving forward in the lesson.

## Extraocular Muscles: Origin, Insertion, and Action

EOMs are the reason we can look all around without moving our heads. In this lesson, you'll study each muscle, its function,



where it comes from, where it attaches to, and which nerve makes a muscle do “its thing” (innervation).

## Extraocular Muscles

The EOMs are the muscles moving your eyes and keeping them lined up when you are looking at any particular object. When both eyes look at an object, and your brain sees only one image, we call this single binocular vision (SBV), which is the main reason for having EOMs. If you never had the need to look around, and your eyes just remained in their primary position of gaze, which is straight ahead, you could probably do just fine without a bunch of EOMs; however, looking around is a valuable survival feature in humans. As an ophthalmic technician, it will benefit you to know more detailed information about how the muscles work and some problems affecting them.

Each eye has six EOMs, which are named based on where they attach to the eye (sclera):

- Superior rectus (SR)
- Inferior rectus (IR)
- Medial rectus (MR)
- Lateral rectus (LR)
- Superior oblique (SO)
- Inferior oblique (IO)

The primary action of each EOM is when it moves from the primary position (straight ahead) to any other position. Occasionally, we'll also mention an EOM's secondary action, which is an additional action performed by an EOM while it is performing its primary action. For the most part, primary actions are going to be our main focus. As you read about each EOM, refer to figure 1–6 to help you visualize what's being discussed.

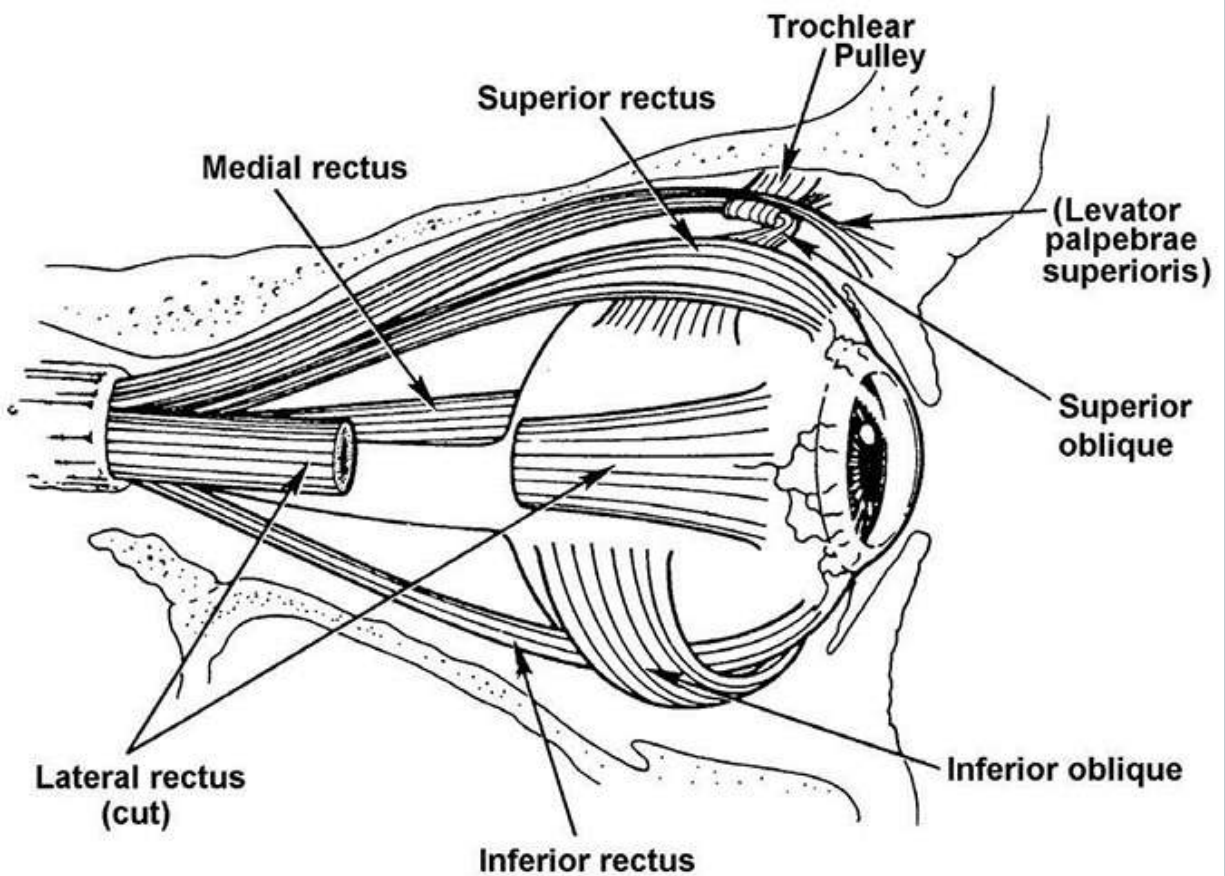


Figure 1–6. The extraocular muscles (for the right eye).

## Superior Rectus Muscle

The SR begins at the back (posterior) of the ocular orbit at a place called the annulus of Zinn. The annulus of Zinn is a circular tendon surrounding the optic nerve and attaches to the optic foramen. It is the origination point for five of our six eye EOMs, the one exception is the IO.

The SR extends forward and attaches to the sclera on the top of the eye, anterior to the equator of the globe, approximately 7.7 millimeter (mm) away from the limbus (cornea/sclera junction).

The primary function of the SR is elevation of the eye. Simple enough to remember—the SR sits on top and pulls the eye superiorly. The nerve innervating the SR is the oculomotor nerve (CN III).

**Flip through each flashcard below to  
learn about the other rectus muscles of  
the eye.**

---

Inferior Rectus Muscle

The IR originates at the annulus of Zinn. It extends forward along and attaches to the sclera on the bottom of the eye, anterior to the equator of the globe, approximately 6.5 mm away from the limbus. Its primary function is depression of the eye. Simple to remember: IR pulls the eye inferiorly. The

1 of 3

Medial Rectus Muscle

The MR begins at the annulus of Zinn. It extends and attaches to the sclera on the medial (nasal) side of the eye, anterior to the equator of the globe, approximately 5.5 mm away from the limbus. Its primary function is adduction of the eye.

Simple to remember: MR pulls  
the eye medially

2 of 3

Lateral Rectus Muscle

The LR muscle begins at the annulus of Zinn. It extends and attaches to the sclera on the lateral (temporal) side of the eye, anterior to the equator of the globe, approximately 6.9 mm away from the limbus. Its primary function is abduction of the eye. Simple to remember —LR pulls the eye laterally

3 of 3



Complete the content above before moving on.

## Superior Oblique (SO) Muscle

The SO muscle originates at the annulus of Zinn, the same as all the rectus muscles. The difference is, all the rectus muscles go forward along the eye and attach anterior to the equator. Not so with the SO.

It extends forward along the superior, medial side of the orbit until it passes through the trochlear pulley, which is well forward in the orbit. From there, it swings around the pulley, and then extends slightly rearward and across the top of the eye, passing underneath the SR, and attaching posterior to the equator on the lateral side of the globe.



The SO muscle extends across the eye, from the medial side to the temporal side of the eye. This is important to visualize, as it helps you understand why the primary action of the SO is intorsion, which is where the top of the eye rotates in toward the nose.

Imagine the SO is innervated to help you better understand the process. The muscle pulls the top of the eye in toward the trochlear pulley. This causes the top of the eye to rotate in toward the medial wall (or nose). This is intorsion and is the primary action of the SO.

The secondary action of the SO is depression. Oblique muscles are unique as they pull the eye in the opposite direction of what their name implies. Why? Remember where the SO attached on the eye-- posterior to the equator. Where did the muscle originate? As far as the eye is concerned, it originates at the trochlear pulley (although you already learned, it really started back at the annulus of Zinn). So when the SO is innervated, it pulls the superior, posterior portion of the eye forward. This causes the eye to look downward, hence depression. If you still don't understand, ask your supervisor or doctor for assistance. This is an important concept, so try to picture it in your mind. This muscle is the reason an eye can look down and across the nose while still maintaining alignment with the other eye.

The SO muscle is innervated by the trochlear nerve (4th CN). How can you remember this? What is the piece of cartilage the superior oblique passes through? The trochlear pulley. So the trochlear nerve (4th CN) must innervate the SO muscle since it passes through the trochlear pulley, right? Yes. A final bit of information: the SO muscle is our longest EOM and the most susceptible to even mild trauma.

## Inferior Oblique (IO) Muscle

The IO muscle does not originate at the annulus of Zinn. It actually begins at the anterior, medial floor of the bony orbit. From this forward and nasal origination point, the IO muscle wraps under the eye, and extends rearward and temporally, passing over the IR and up under the LR. It attaches posterior to the equator of the globe on the temporal side. The IO is our shortest EOM.

The primary action of the IO muscle is extorsion, which is where the top of the eye rotates outward, toward the temple. It's the opposite of intorsion. It happens because the IO muscle is attached to the temporal side of the eye, but originates from the nasal side of the orbit. So when the muscle is innervated, it pulls the

bottom of the eye toward the medial wall, causing the top of the eye to rotate out, or temporally. Hence, the (primary) action of the IO muscle is extorsion.

The secondary action of the IO muscle is elevation. It points the eye upward. How? Remember the IO muscle began at the front of the orbit and traveled under the eye toward the back of the orbit. When the muscle is innervated and shortens, the back of the eye is pulled forward, making the eye look up. This muscle is the reason an eye can look up and across the nose while still maintaining alignment with the other eye. The IO muscle is innervated by the oculomotor nerve (3rd CN). So it, the MR, SR, and IR muscles are all innervated by the 3rd CN.

## Innervation Made Easy

Knowing the muscles and what they do is very important, but to really be able to put this information to use, it needs to be connected with the knowledge of which cranial nerve innervates which muscle. Knowing the LR muscle pulls the eye laterally (abduction) is nice, but if it's not working, can you tell which nerve may be at fault? This is why knowing the EOM innervation is important. There is a very simple formula to remember which CN innervates which muscle:

**(LR6SO4)3**

This formula is a shortcut for stating the LR is innervated by the 6th CN (abducens), the SO muscle is innervated by the 4th CN (trochlear), and the rest of the EOMs are innervated by the 3rd CN (oculomotor).

## Ocular Motility Terminology

There are many terms used when discussing the actions of the eyes and the movements of the EOMs. Let's go over some of these.

## Saccades and Pursuits

The eye muscles are composed of different types of tissue. Some of the tissue allows for quick bursts of activity by the muscle, whereas the other tissue allows for long, continuous motion, allowing for slow, precise movements of the eyes.

Saccades are quick, voluntary, simultaneous movements of both eyes in the same direction. Saccades are responsible for fixation, refixation, and rapid eye movements. Pursuits are slow, involuntary parallel movement of both eyes, allowing us to follow moving objects.

## **Agonist, Antagonist, and Synergist**

An agonist is the muscle that is the prime mover for a desired direction of gaze. If you want to look at the ceiling with your right eye, the SR muscle is the agonist for such a look. An antagonist is a muscle in the same eye as the agonist working directly against the agonist. Continuing with the ceiling example, the IR is the antagonistic muscle to the SR muscle, which is the agonist. What is the antagonist of the MR muscle? If you said the LR muscle, good job! How about the SO muscle? If we are talking about its intorsion action, the IO muscle is its antagonist. If we are looking at its depression action, the SR muscle is its antagonist.

If two people have good synergy, it means they work well together, helping each other out. The same applies to eye muscles. The synergistic muscle is in the same eye as the agonist and helps the agonist move the eye in a particular direction. If the SR muscle is the agonist for an eye to look up at the ceiling, which muscle helps or is synergistic in elevating the eye? The IR muscle. Remember, the IR muscle has a secondary action of elevation, so it helps out, or is a synergist in this case.

## **Yoked Muscles, Versions, and Vergence**

It's not possible for your right eye to look right (abduct) and your left eye to look left (also abduct) at the same time because the eye muscles of your right eye are "yoked" to the eye muscles of your left eye and vice versa. Because the eye muscles between the two eyes are "yoked," it allows the eyes to move together, or parallel to each other. This parallel movement is necessary if you are to look around without experiencing diplopia. If you look left, you want both eyes to look left. For your eyes to track in this manner, the left lateral rectus (LLR) and right medial rectus (RMR) must be innervated. These two muscles work together to make your eyes look left. They are considered to be yoked muscles.

Yoked muscles allow parallel, conjugate (conjunctive) movement of the two eyes, called version movement. Version movement occurs when the eyes move and stay parallel to each other. They do not converge or diverge. Since the two eyes are moving parallel, it's called a conjugate movement.

What is it called when the two eyes don't move parallel to each other? Vergence is the term. The easiest way to visualize this is when the eyes converge or diverge. They are not parallel in these two cases, so we

consider this a disjunctive movement.

Let's get back to yoked muscles. Ideally, we should be able to give you a muscle and you should be able to tell which muscle (in the other eye) it's yoked to. The way to do this is really quite simple. Just take whatever muscle you're given and find the opposite. For example, the yoked muscle for the right superior rectus (RSR) is the left inferior oblique (LIO). Right becomes left, superior becomes inferior, and rectus becomes oblique.

Let's try another. The left superior oblique (LSO) is yoked to the right inferior rectus (RIR). Since you are on a roll, how about one more? What muscle is yoked to the right lateral rectus (RLR)? You might think the left medial oblique (LMO), right? But this can't be, since there is no such thing as a medial oblique. In this case, since you can't convert rectus to oblique, just stick with rectus. The RLR is yoked to the left medial rectus (LMR). To ensure you get it, study the yoked muscle chart below.

Let's cover two more terms—duction and version. Duction is the movement of one eye. If you check ductions on someone, you are checking the movement of one of their eyes. If you checked the movements of both eyes together, you are checking their versions.



## Yoked Muscles

RSR ↔ LIO

RIR ↔ LSO

RSO ↔ LIR

RIO ↔ LSR

RMR ↔ LLR

RLR ↔ LMR

**Self-Test Questions.** After you complete these questions pertaining to extraocular muscles, you may check your answers at the end of this module.

1. Where is the primary position of gaze?

Type your answer here

SUBMIT

2. Name the six EOMs.

Type your answer here

---

SUBMIT

3. Which muscle does not originate at the annulus of Zinn?

---

☐

IR

☐

MR

☐

IO

☐

SO

SUBMIT

4. Where does the SR muscle attach to the eye?

Type your answer here

---

SUBMIT

5. Which nerve innervates the IR muscle?

Type your answer here

---

SUBMIT

6. What is the primary function of the LR muscle?

Type your answer here

---

SUBMIT

7. What structure does the SO pass through?

Type your answer here

---

SUBMIT

8. What is the primary action of the SO? Secondary action?

Type your answer here

---

SUBMIT



9. What is the name of the CN IV?

Type your answer here

---

SUBMIT

10. Which EOM is the longest?

---

☐

SO

☐

IO

☐

LR

SUBMIT

11. Where does the IO originate?

Type your answer here

---

SUBMIT

12. From its origination point, what is the path the IO takes to get to its attachment point?

Type your answer here

---

SUBMIT

13. What is the shortest EOM?

---

☐

LS

☐

IO



SO

SUBMIT

14. What is the primary action of the IO? Secondary action?

Type your answer here

---

SUBMIT

15. What does  $(\text{LR}_6\text{SO}_4)_3$  mean?

Type your answer here

---

SUBMIT

16. What are saccades and what are they responsible for?

Type your answer here

---

SUBMIT

17. What are pursuits?

Type your answer here

---

SUBMIT

18. What is an agonist?

Type your answer here

---

SUBMIT

19. What is an antagonist?

Type your answer here

---

SUBMIT

20. What muscle is in the same eye as the agonist and helps the agonist?

Type your answer here

---

SUBMIT

21. What do yoked muscles allow our eyes to do?

Type your answer here

---

SUBMIT

22. What kind of movement is vergence of the eyes considered to be?

Type your answer here

---

SUBMIT

23. What muscle is yoked to the LMR? The LIO? The RIR?

Type your answer here

---

SUBMIT

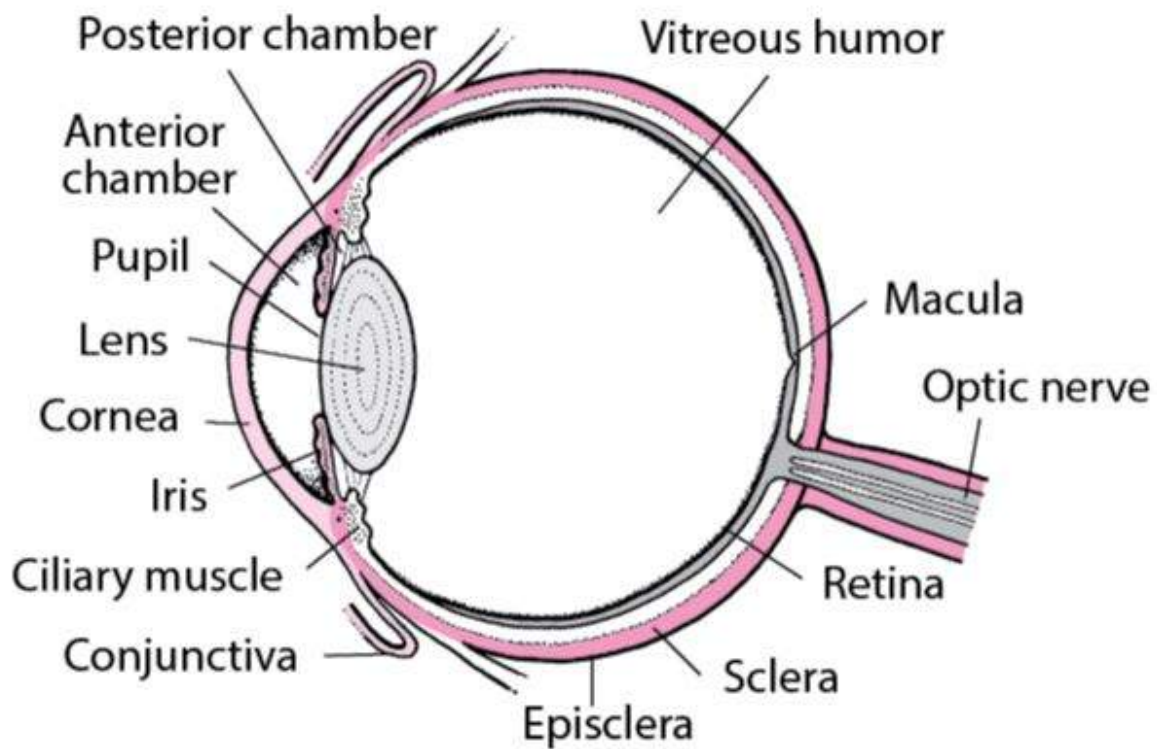
24. What is duction?

Type your answer here

SUBMIT



Complete the knowledge check questions before moving forward in the lesson.



## Eyeball Anatomy

The eyeball (refer to image on the left) is about 1" in diameter and contains specialized structures. It focuses light rays and converts visible light to electrochemical impulses for the brain to interpret as vision.

The eye can be broken down into three layers or tunics--fibrous, vascular (also known as the uveal tract), and nervous. Each has its own mission in making the eye work.

The fibrous tunic is the outermost layer of the eyeball and is composed of the cornea and sclera. The basic overall purpose of the fibrous tunic is protection of the eye, but the cornea and sclera also have their own special jobs in addition to protection. Since the cornea is at the front, it's logical to start there.

## Cornea

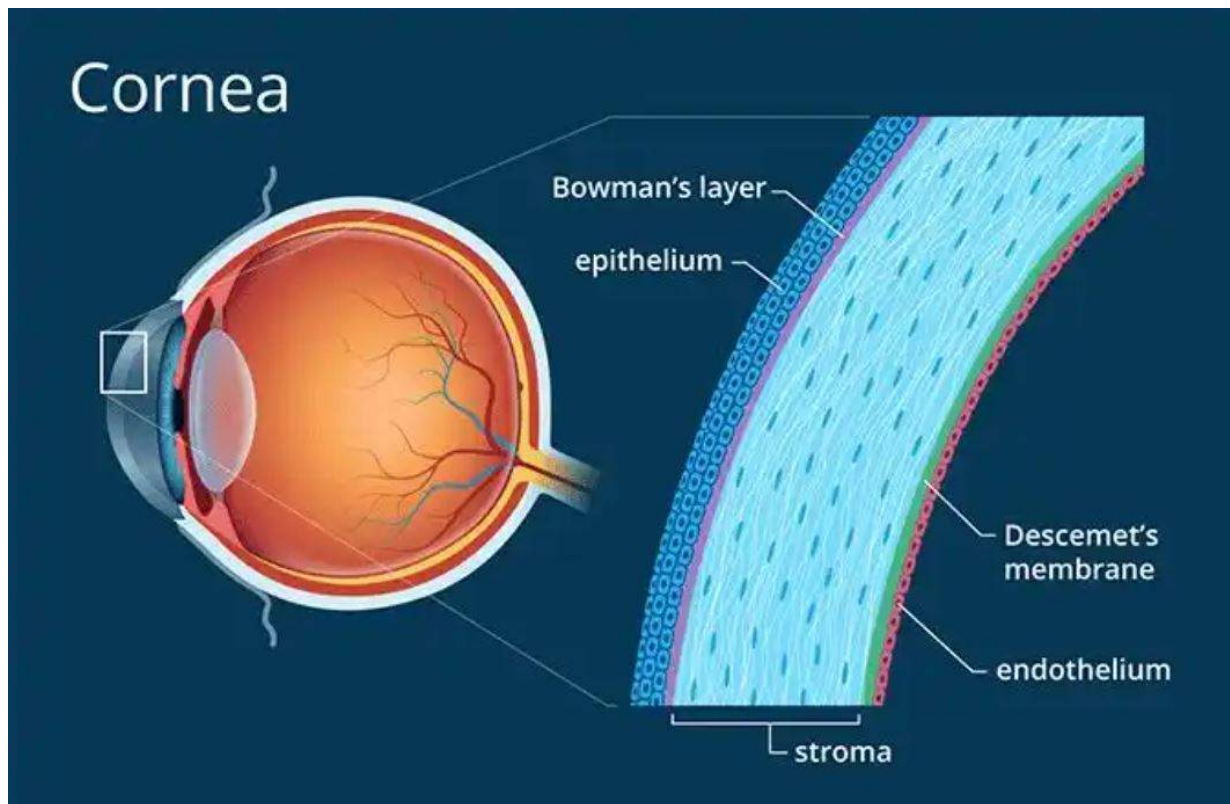
The cornea makes up the anterior one-sixth of the fibrous tunic. It's the clear window of the eye. In an adult, it's about 12 mm wide (horizontally) and about 11 mm tall (vertically).

Its primary job is refraction of light. It's the most powerful refracting structure of the eye with an approximate power of +43.00 diopters (D). This is amazing! It's also avascular, meaning it does not contain any blood vessels (**a = without; vascular = blood vessels**).

The cornea communicates what it feels to the brain via the trigeminal nerve (5th CN). This is an afferent nerve, meaning it carries messages to the brain. Think of it as afferent carries a feeling to the brain. The cornea is extremely sensitive, as anyone who has experienced a corneal abrasion can easily attest to. Since the cornea has five layers, you should easily remember which CN innervates it, five layers of the cornea innervated by the 5th CN.

A way to remember the layers of the cornea is through the mnemonic ***Every Blue Smurf Dies Eventually***. For a description of the corneal layers, see the image to the right. It starts from the outermost (exposed) layer going in toward the eye

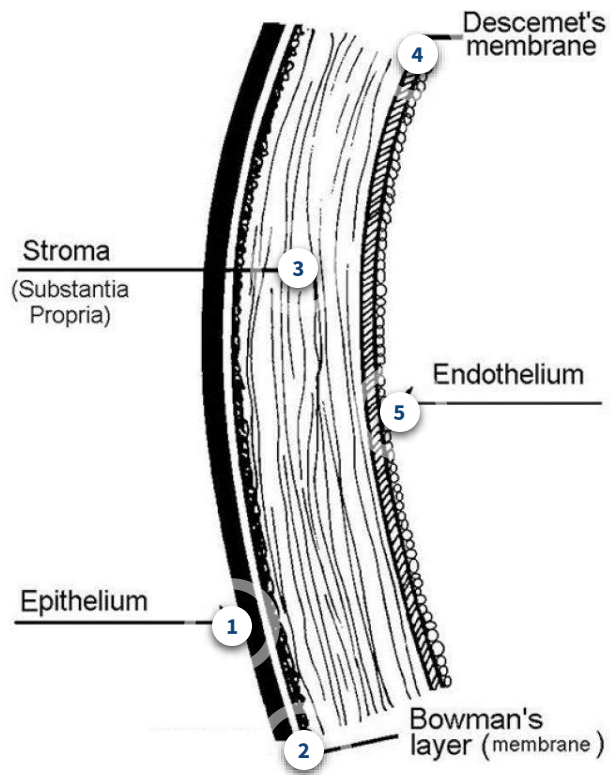


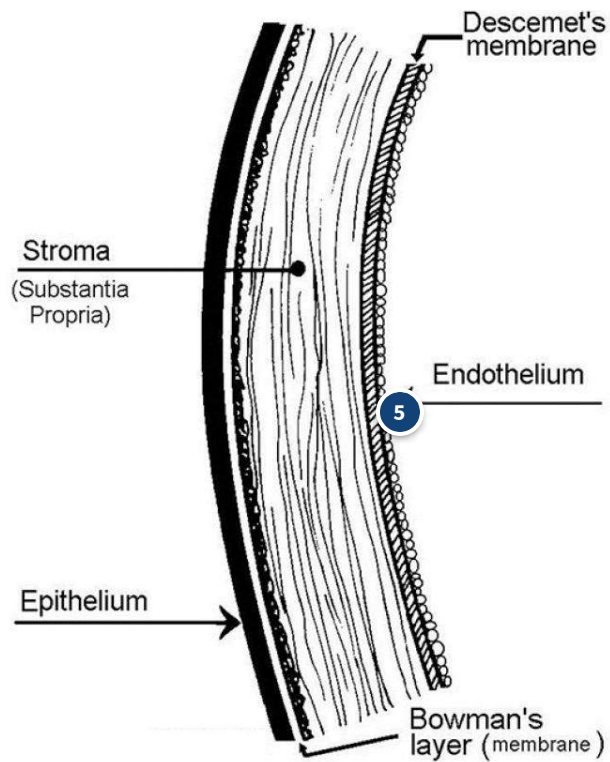


The cornea allows light to enter the eye for vision. Here are the basics you should know about this important part of the eye.

---

**Below is an image of the layers of the cornea. Click on each number to learn about the different layers.**



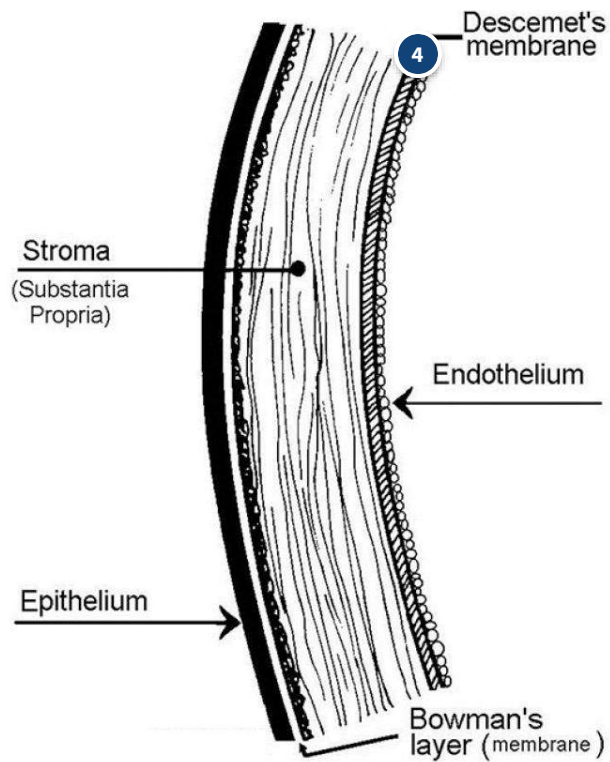


## Endothelium

The endothelium is one-cell layer thick and in direct contact with the aqueous humor (fluid in the anterior chamber of the eye). The cornea receives much of its nutrition from the aqueous humor. The endothelium doesn't just let aqueous pour in though. It acts as a physiological pump for the cornea, pumping waste from the stroma and maintaining the cornea's normal, dehydrated state.

The number of endothelium cells we're born with is all we'll ever have. Your body does not make any more and endothelium cells don't regenerate when they are damaged or die. When an endothelial cell "croaks," the neighboring cells move over and enlarge to fill in the empty space. As we age, some endothelial cells die off naturally. Also, any penetrating trauma or surgery (e.g., cataract extraction) kills and damages some endothelial cells.

If too many are lost, the remaining endothelial cells can't fill in all the gaps. If this occurs, the endothelium cannot effectively control the fluid entering the stroma. The stromal fibers then swell, absorbing too much fluid. The swelling causes cloudiness and VA takes a nosedive.

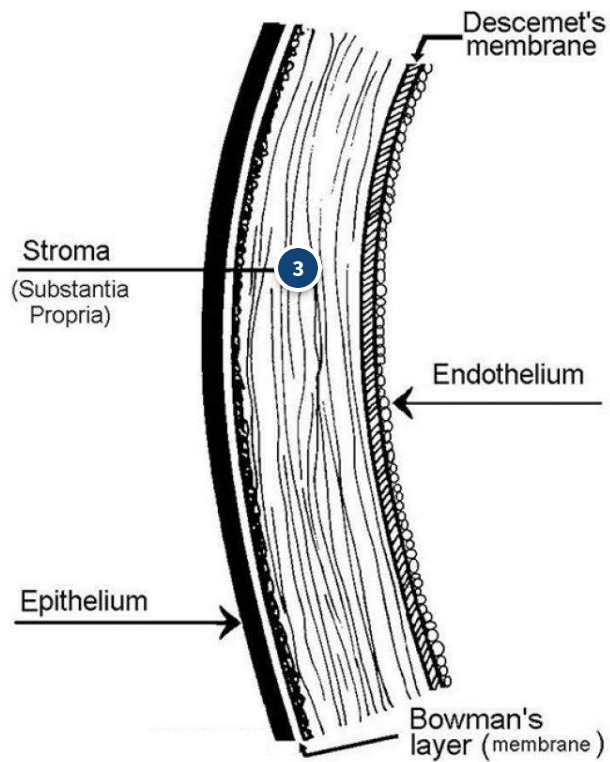


## Descemet's membrane

Is a thin layer of tissue quite similar to Bowman's layer? Descemet's membrane is quite tough and resistant to penetration. This is good since we are getting close to being inside the eye itself.

Any object having penetrated this far really needs to be stopped, because the endothelium (the last layer) is not a protective layer. The endothelium has its own job to do.

If an object does penetrate Descemet's membrane, a scar forms upon healing. Realistically though, if an object did penetrate Descemet's membrane, you have bigger problems to deal with anyway.

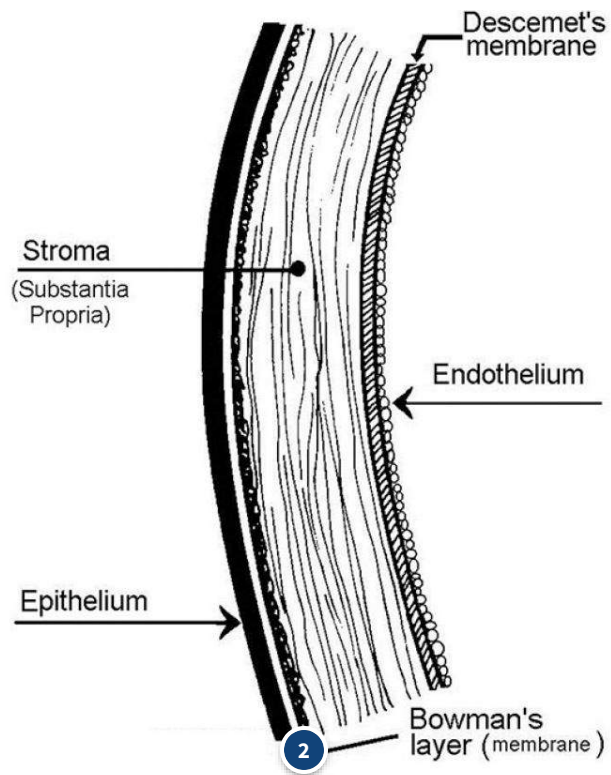


### Stroma (substantia propria)

The stroma forms about 90 percent of the cornea. It's quite thick when compared to the other layers and performs most of the refraction (bending) of light accomplished by the cornea.

The stroma depends on the epithelium and endothelium to maintain the proper hydration (fluid) level, since it can't manage its own fluid levels.

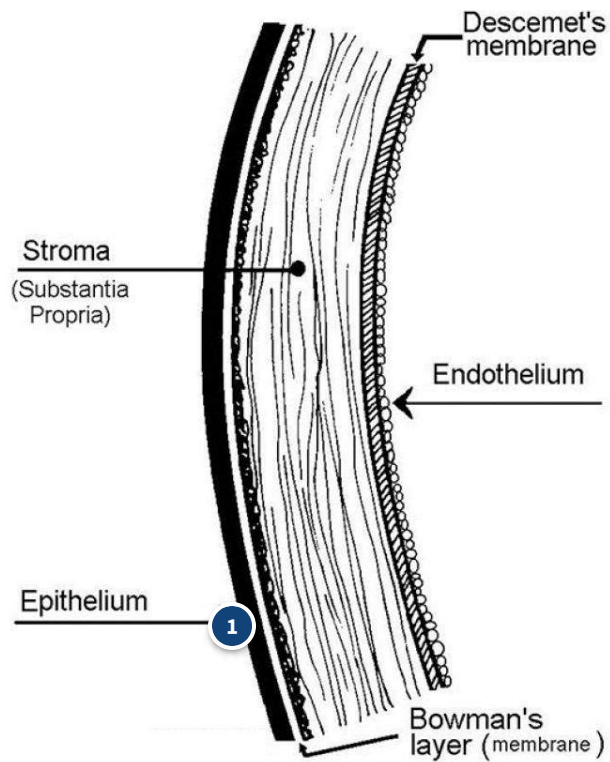
The stroma is actually kept in a fairly dehydrated state. If the stromal fibers absorb too much fluid, they swell and the stroma gets cloudy. Obviously, a cloudy stroma is not a good thing when trying to maintain good visual acuity. Like Bowman's layer, if the stroma is traumatized or otherwise injured, a permanent scar is left.



## Bowman's layer

Is the tissue just under the epithelium, and is acellular (without cells), very thin, and made up of collagen fibers? It's very resistant to trauma and acts as a barrier to microorganisms.

The downside is, if Bowman's layer does receive damage, a scar is left. Fortunately, most eye injuries are mild abrasions and fail to penetrate enough to damage this layer.



## Epithelium

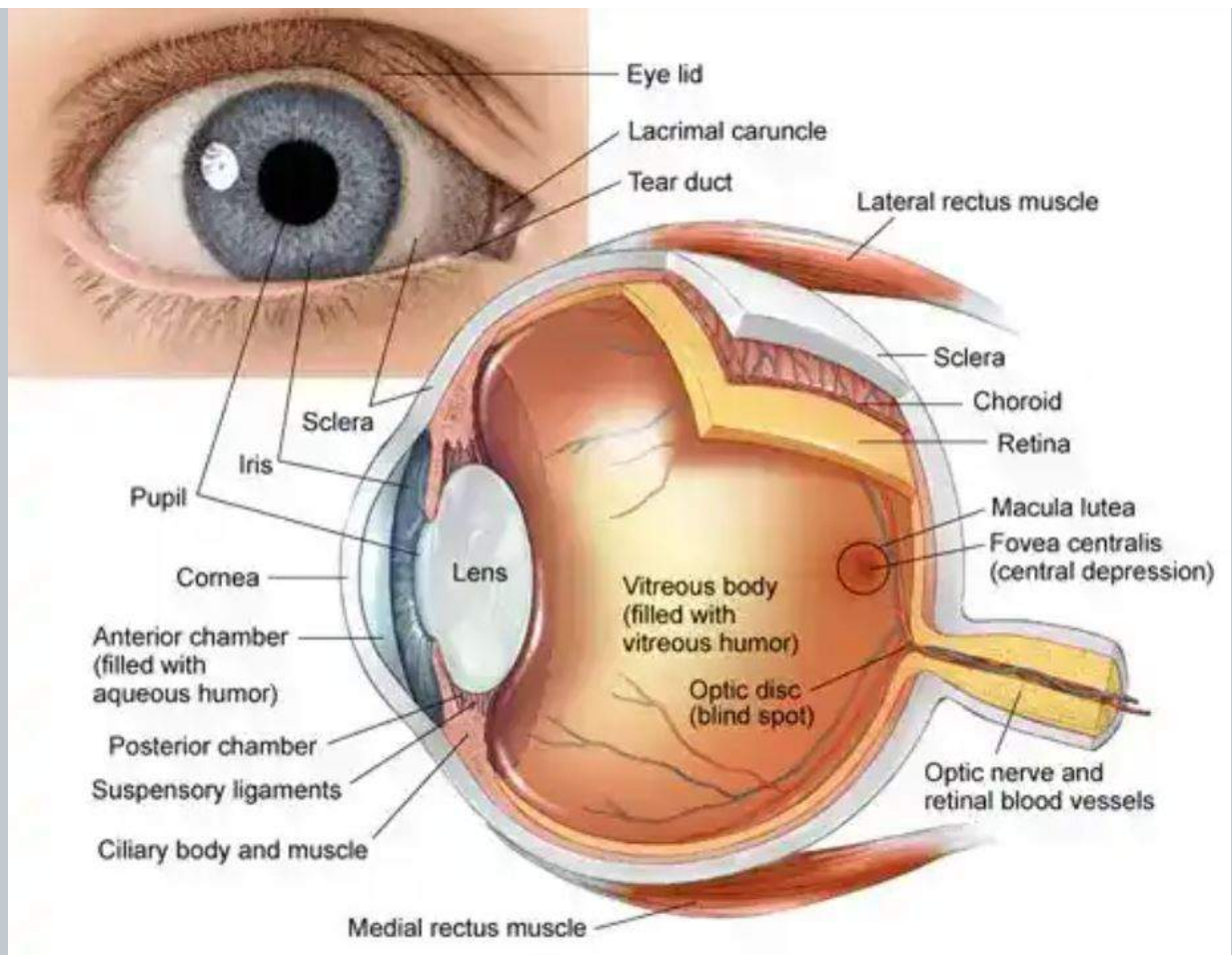
The epithelium is five cell layers thick. Since it's the outer layer, it's very susceptible to injury. Fortunately, by design, it can repair minor scrapes and scratches inflicted upon it. Its layers slide around to fill in damaged areas (e.g., a scratch), while more epithelium cells are produced quickly to permanently heal the area. With proper treatment, a scratched epithelium can usually heal within 24 hours.

The other neat thing about epithelium is it does not leave a scar upon healing. Considering how many little scratches our eyes receive in our lifetime, this is a good thing. Imagine if we got a scar on our cornea for every little abrasion. In a short time, we would have nothing but a cloudy window to look out of, and would essentially be blind for most of our lives. It also limits the amount of fluid entering the deeper layers of the cornea, absorbs food from the tear layer, and is the oxygen inlet to the eye.



Complete the content above before moving on.



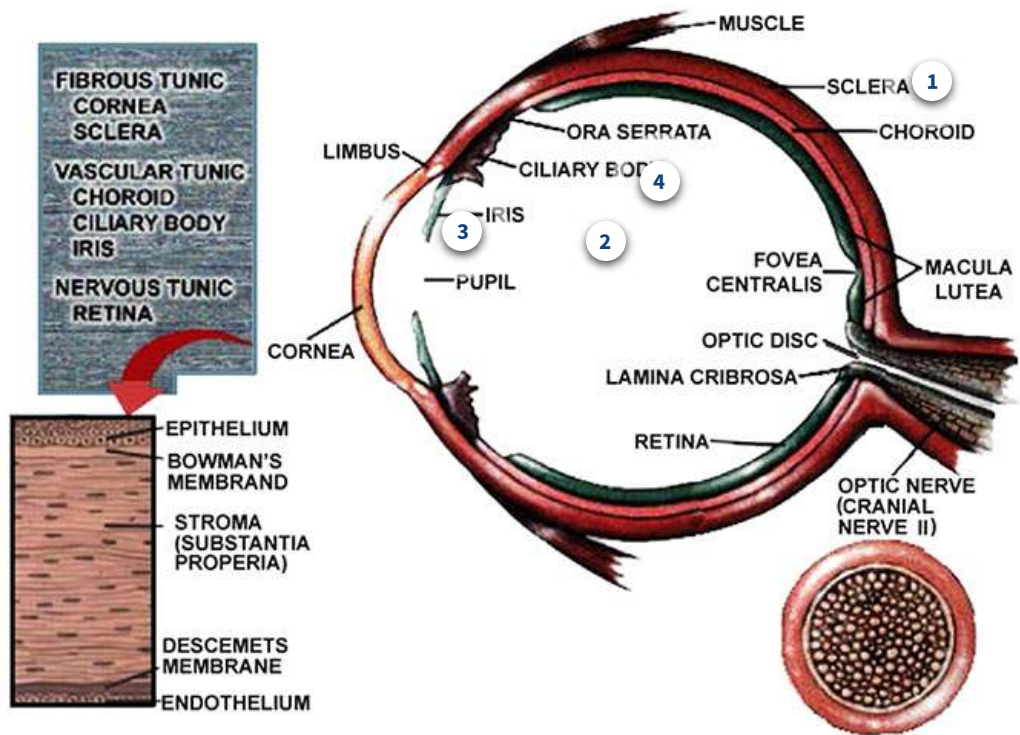


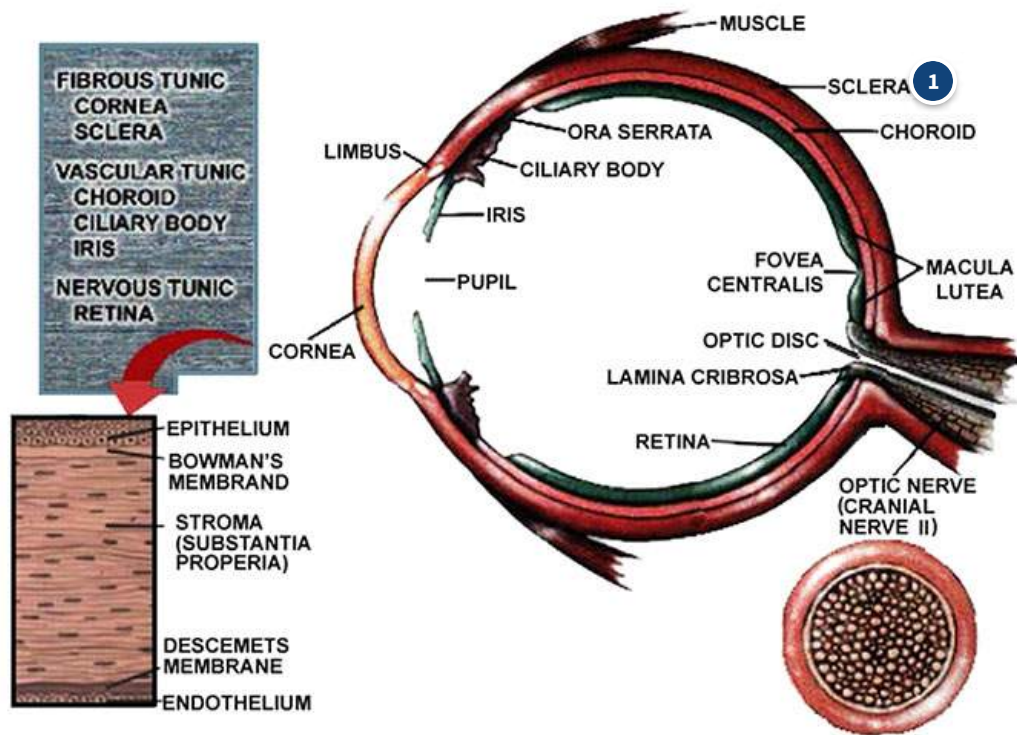
Cross section of the eye.

---

Below is an image of a cornea. Click on each number to learn additional information on the cornea.





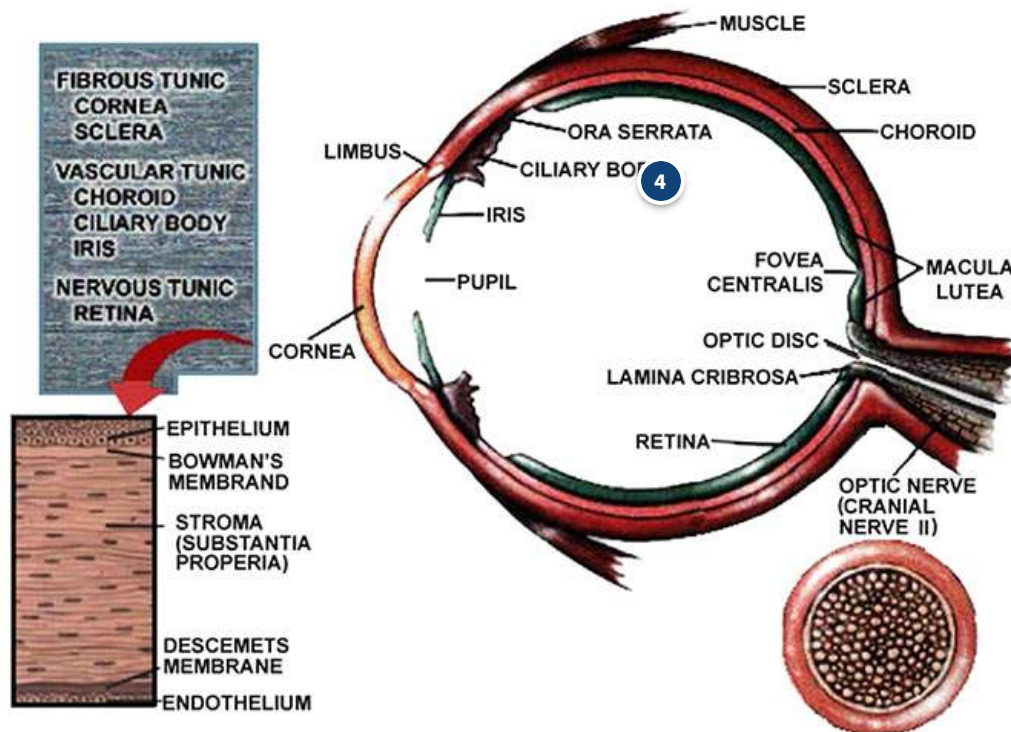


## Sclera

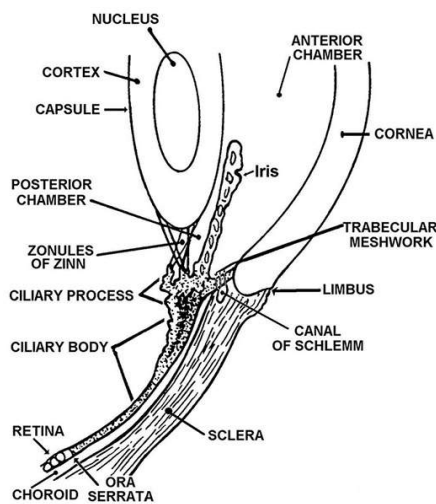
This is the white of the eye. It makes up the posterior five-sixths of the fibrous tunic. The sclera is a fibrous, tough tissue, giving the eye the support needed to maintain the structures within it. It provides an insertion point for the six EOMs.

It's thickest at its posterior portion and becomes thinner anteriorly. The optic nerve penetrates the sclera posteriorly, slightly above and nasal to the fovea.

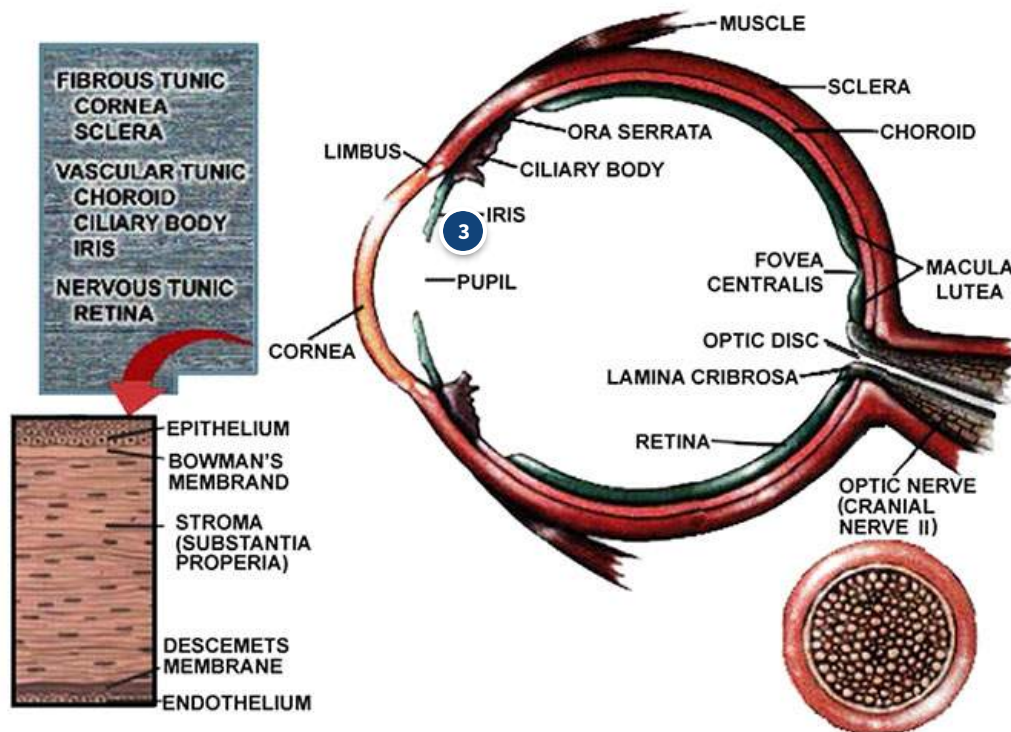
This sieve-like area is called the lamina cribrosa and consists of many small holes through which the optic nerve, ciliary nerves, ciliary branches of the oculomotor nerve (3rd CN), and blood vessels (veins and arteries) pass through the sclera. It's the sclera's weakest point.



## Ciliary body



The ciliary body is located just behind and near the base of the iris. It has a multitude of functions. To explain its various functions, we divide the ciliary body into two sections—the anterior pars plicata and the more posterior pars plana. Refer to figure 1-11 as you study each section.



## Iris

The iris is the beautifully colored part of your eyes. The coloring is based on the amount of pigmentation built up on the iris. When we are first born, our eyes are blue. They look blue because there is little to no pigment on the front of our iris. What is seen is the thin membrane of tissue that is our iris. Since this tissue is very vascular, we see the bluish-appearing blood vessels. Look at the veins of your arms.

They appear blue, but we know the blood inside is red. Same deal with the iris. So, people with blue eyes haven't developed much pigment on the front side of their irides (plural of iris). Green-eyed people have a moderate amount of pigment. Brown eyed people have a lot of pigment.

The iris is the most anterior part of the uveal tract and can be thought of as the muscular "shutter" of the eye. It actually has a hole in the middle of it called the pupil, much like a doughnut hole.

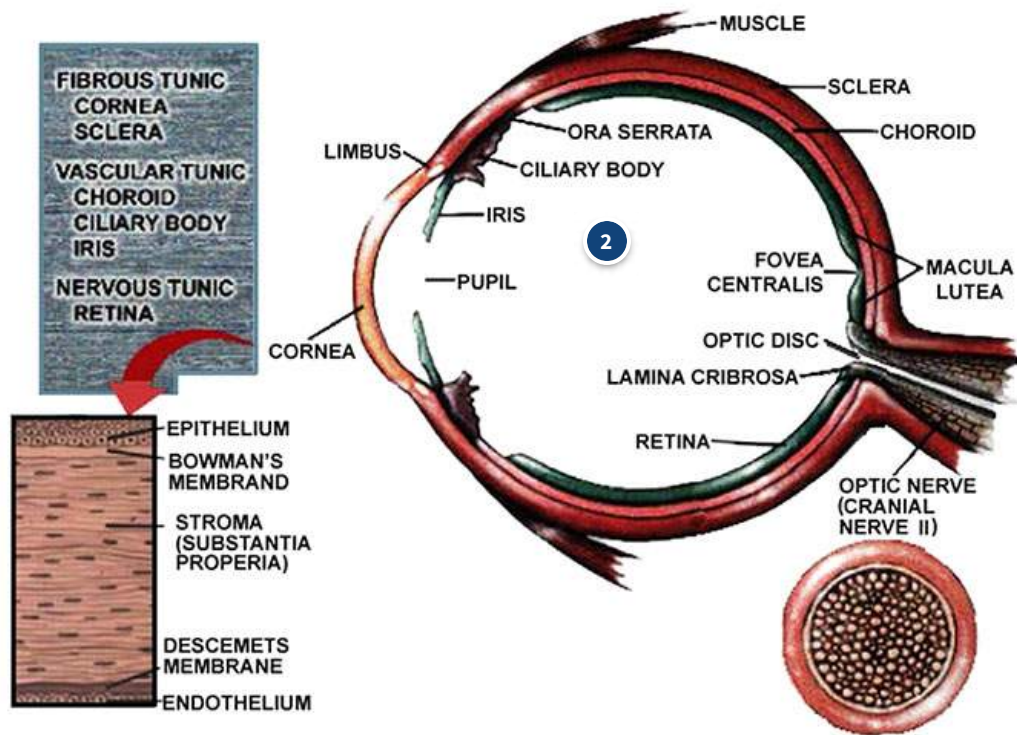
The primary function of the iris is to control the pupil size and regulate the amount of light entering the eye. If there's too much light, things get "washed out."

Just look at a light bulb, and then try to look at something else! When there is too much light, the pupil gets smaller, blocking some of the light. On the other hand, if there is too little light, you can't see well. So, the iris enlarges, allowing more light to enter the eye. The iris has dilator muscles to make the pupil bigger.

They are longitudinal muscles extending from the edge of the pupil to the base of the iris. When innervated, the dilator muscles pull the pupil margin toward the base of the iris, making a bigger opening. When it's time to restrict

the amount of light entering the eye, the sphincter muscle, which is circular and surrounds the pupillary edge, makes the pupil smaller. When innervated, it squeezes the pupillary opening down to a smaller size. The pupil is nothing more than a hole in the iris and changing its sizes determines how much light enters the eye.





### Vascular tunic (uveal tract)

The vascular tunic, commonly referred to as the uveal tract, is composed of the iris, ciliary body, and choroid. As you read through this lesson. The uveal tract is highly vascular and pigmented. Its functions are nutritional and muscular.



Complete the content above before moving on.

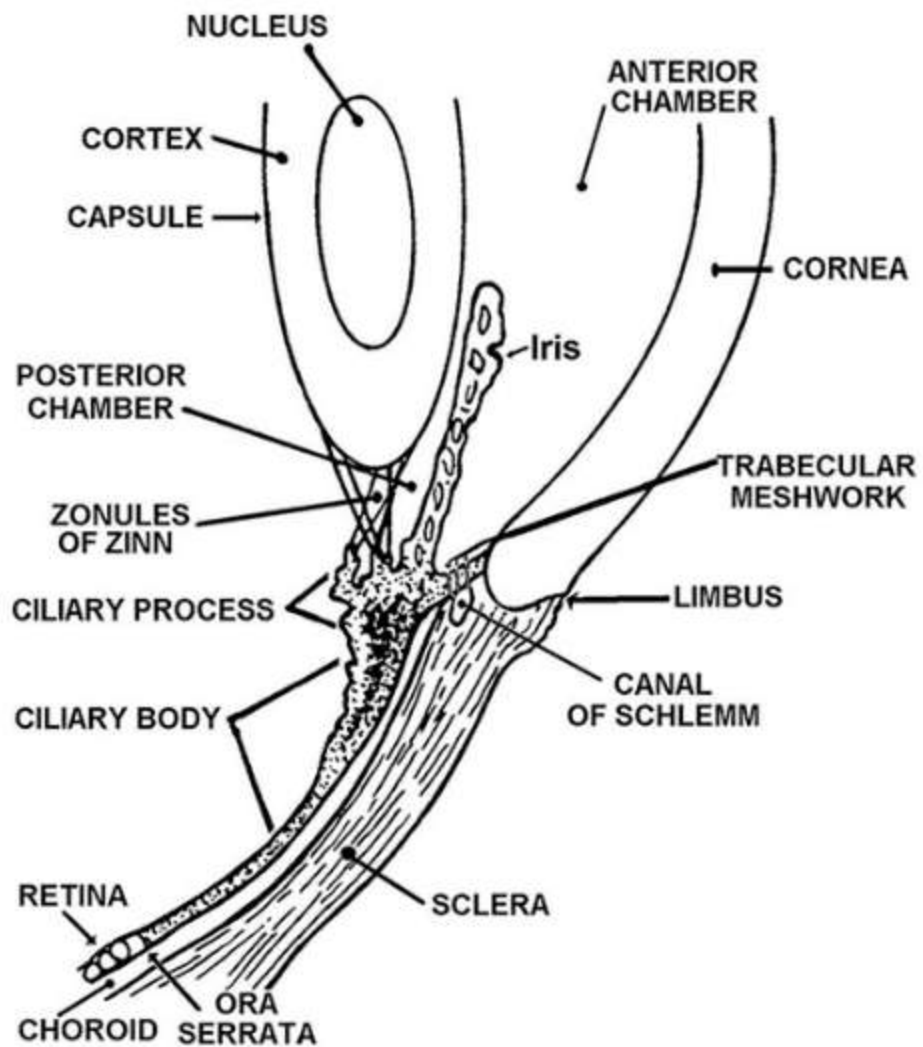
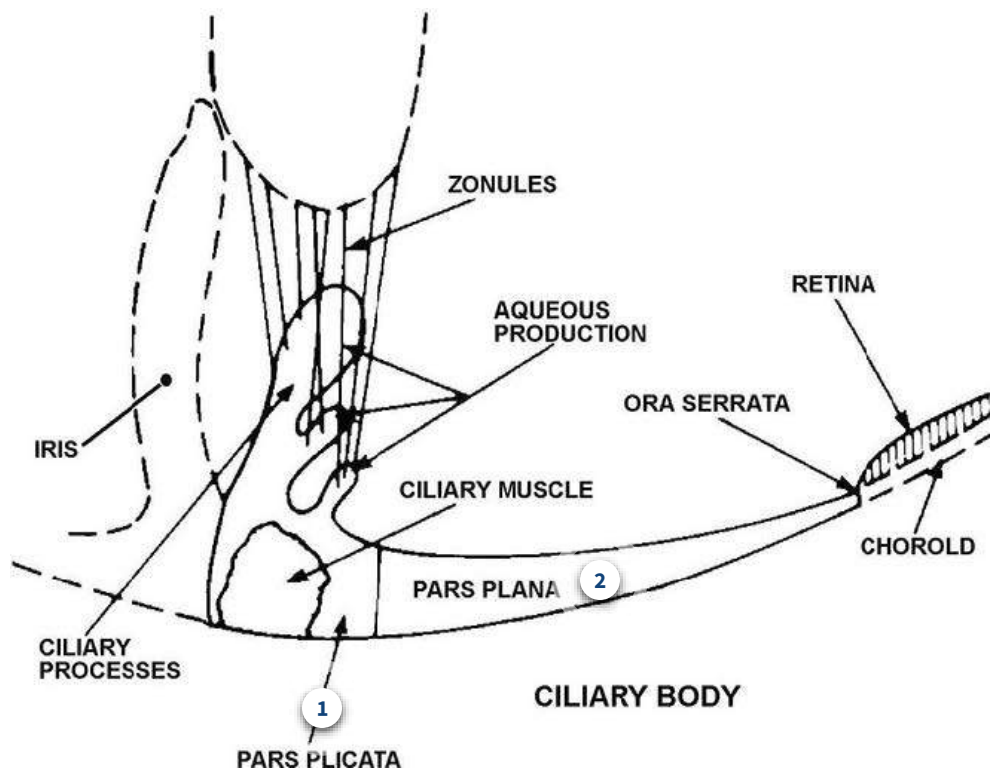
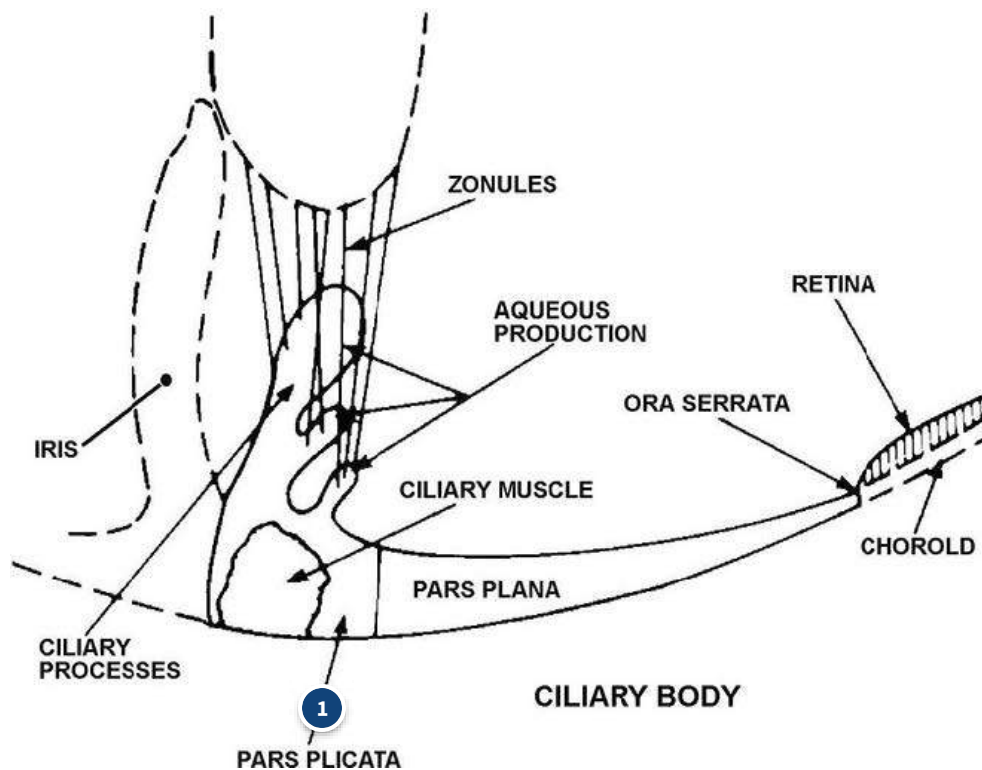


Figure 1-10. Ciliary body.

Below is an image of a ciliary body. Click on each number to learn additional information on the ciliary body.







## Pars plicata

The pars plicata contains the ciliary processes, Zonules of Zinn, and ciliary muscle. The ciliary processes are small projections just behind the iris producing aqueous humor. Remember, the aqueous provides nourishment for the cornea and maintains the proper pressure inside the eye. The pressure in the eye is called intraocular pressure (IOP).

The ciliary muscle is located in the ciliary processes and is responsible for focusing the eye. It can't do it by itself, so hair-like fibers called Zonules of Zinn, or just zonules, if you prefer, are attached to the ciliary processes. These zonules extend from the ciliary processes to the crystalline lens. The zonules control the tension on the lens and keep the lens centered in your eye. The tension on the lens controls its accommodative (focusing) ability.

When the ciliary muscle relaxes, it pulls the zonules tightly. The zonules then pull the outer edges of the crystalline lens, causing it to get thinner and flatter. This reduces its refractive power. This is the relaxed position for the eye and is what happens when a person with no refractive problems (an emmetrope) looks off into the distance. You don't need a lot of refractive power when looking at distant objects, as the light rays entering the eyes from distances of 20 feet and beyond are essentially parallel and not diverging.

So, the relaxed position of the focusing mechanism of your eyes is when the zonules are pulling tightly on the crystalline lens. This occurs when the ciliary muscle is relaxing. When an emmetrope needs to focus on a near object, the eye needs more refractive power than it did for distance viewing. This is because the light rays reflecting off near objects are more divergent, requiring more convergent power from the eye to bring them into focus (accommodation).

This is when the ciliary muscle works. By contracting itself, it releases tension on the zonules. Since the zonules are no longer pulling on the crystalline lens, the lens gets fatter and becomes more curved. This increases its refractive power by allowing more surface curvature. So, the working position for the ciliary body is when it constricts and allows the zonules to be slack or loose.

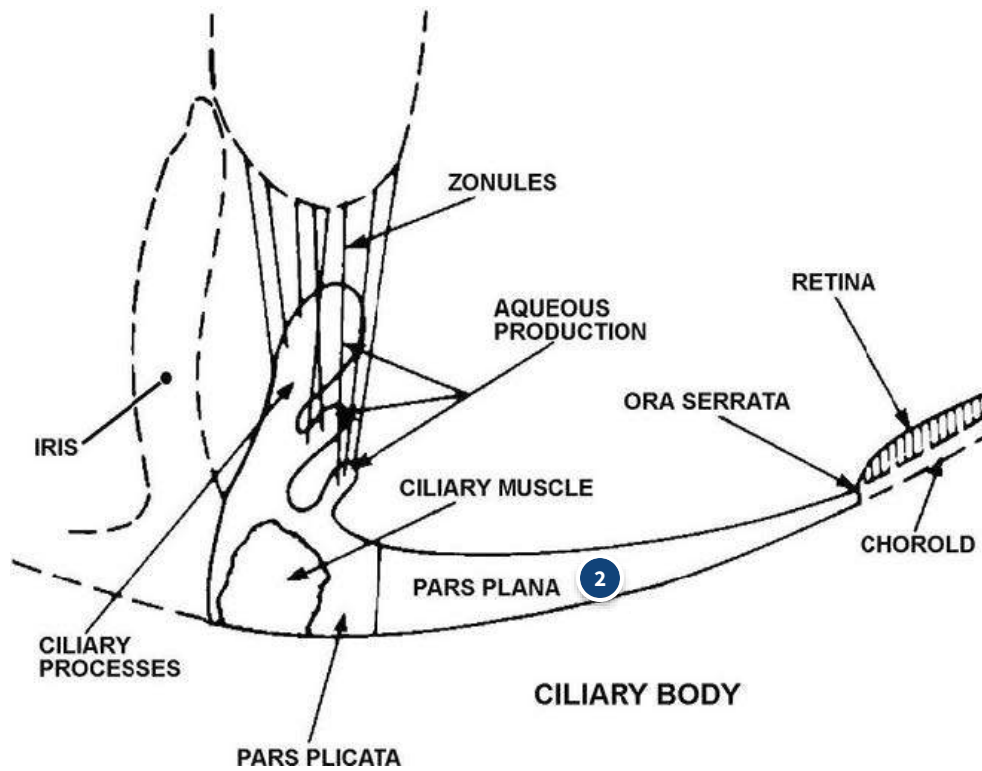
The zonules no longer pull on the crystalline lens, allowing the lens to swell to a rounder shape, giving it more curvature, and thus, more refractive or focusing power. It can be tough to imagine when the ciliary body constricts (works), it actually relaxes the zonules allowing the crystalline lens to accommodate more. An example of this can be seen when someone who reads a lot complains that his or her eyes are tired. Accommodating on a near object takes a lot of work on the part of the ciliary muscle. Extended reading puts a lot of strain on the muscle.

When it's time to look off at a distant object, you need less accommodative power. When less accommodative power is needed; the ciliary body relaxes, causing the zonules to pull tightly on the lens, making it skinny and flatter. This reduces its accommodative power, which produces good distant vision. Understanding how the eye accommodates is an important concept to grasp. It puts the visual complaints of patients with presbyopia, myopia, and hyperopia into perspective. Presbyopes can't see well up close because their crystalline lenses have lost their elasticity and the lens can't get fatter, rounder, or more curved enough to focus the diverging light coming from near objects.

The ciliary body is still working to loosen the zonules, but the lens just can't change shape enough to focus the diverging light from near objects anymore. Myopes can't see in the distance because the ciliary body can only relax so much, and it doesn't pull the lens flat enough to prevent excessive focusing of the light rays coming from the distant objects. The person continues to have blurry vision because the light is focusing in front of the retina, rather than on it. Hyperopes can see distant objects well (usually), but they tend to complain of eye fatigue. This is because their ciliary body is constantly working. If their eye completely relaxes, as it does when a cycloplegic medication is put in the eye, their distant vision is blurry as their eye cannot bring the light rays to a focus soon enough.

The light rays theoretically come to a focus behind the eye. So how do they manage to see fine day to day, when there is no cycloplegic in their eyes? Their ciliary body works and relaxes the zonules, allowing the crystalline lens to focus the light rays onto the retina. The amount of work the ciliary body must accomplish increases as an object becomes closer to the hyperope. This explains why hyperopes complain of eye fatigue, especially after long periods of reading.

Their ciliary body is working pretty much full time to keep the world around them clearly focused and works even harder when they need to read. As you can see, pars plicata is responsible for the production of aqueous (via the ciliary processes) and also the accommodation, or focusing, of our eyes (via the ciliary muscle and the Zonules of Zinn affecting the crystalline lens). The pars plicata is located just behind and near the base of the iris.



## Pars plana

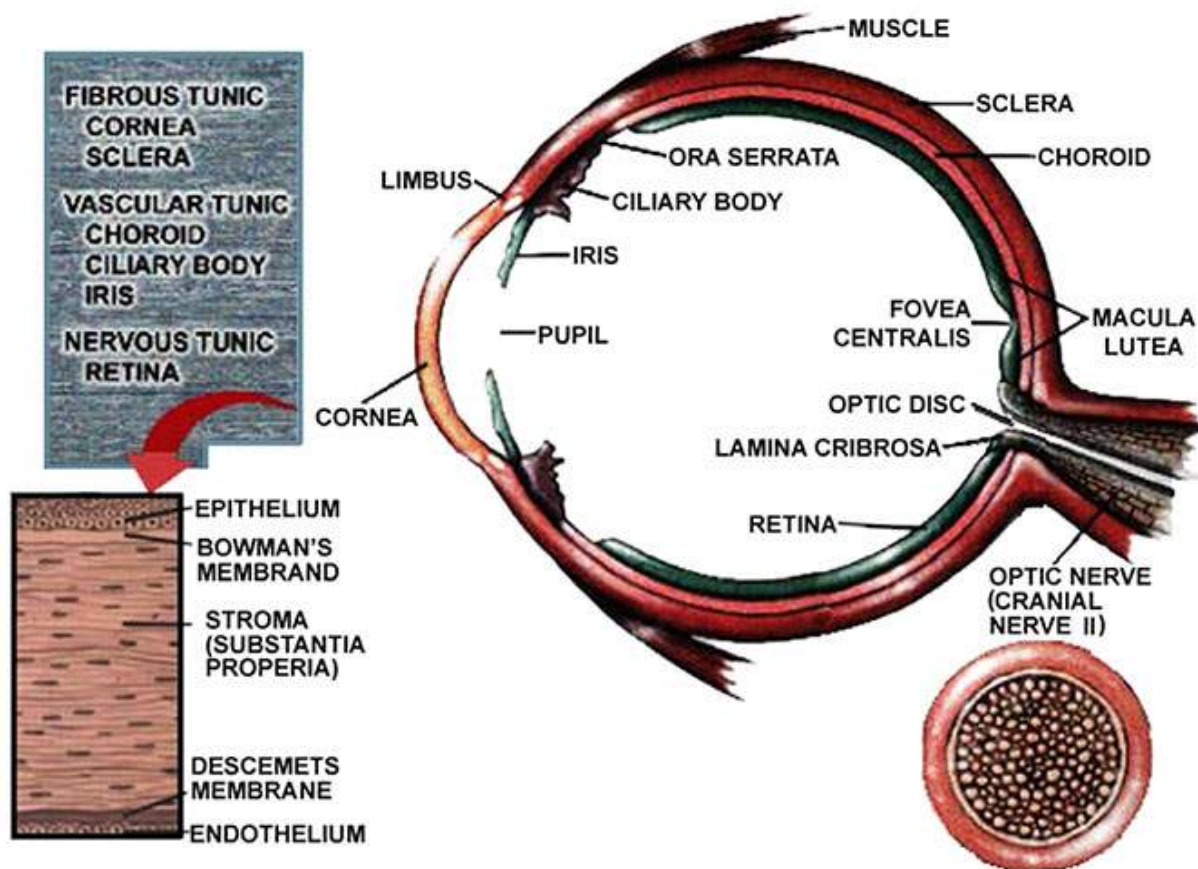
The pars plana is used more as a landmark than anything else. It's part of the ciliary body, but other than being a vascular structure, it does little else of note.

It's located posterior to the pars plicata and runs back until it gets to the choroid and retina, which you'll learn about shortly.

It's probably just good to know there is an area of the eye called the pars plana, if for no other reason than there is an eye disorder called pars planitis, which is essentially inflammation of the pars plana.



Complete the content above before moving on.



## Choroid

The choroid is the “chow hall” for the inner eye. It’s highly vascular and supplies the iris, ciliary body, retina, and inner sclera with blood. Blood is the food and oxygen carrier keeping tissue alive, so the choroid is extremely important.

The choroid lines the inner sclera of the eye, from the posterior (where the optic nerve enters the eye) forward, until it gets to the pars plana. It terminates there (as does the retina); this termination point is called the ora serrata.

Basically, the choroid is sandwiched between the sclera and the retina. Sandwiched is a good term because of what the choroid does--provides nourishment. Notice the choroid is firmly attached at the ora serrata and at the margin of the optic nerve.

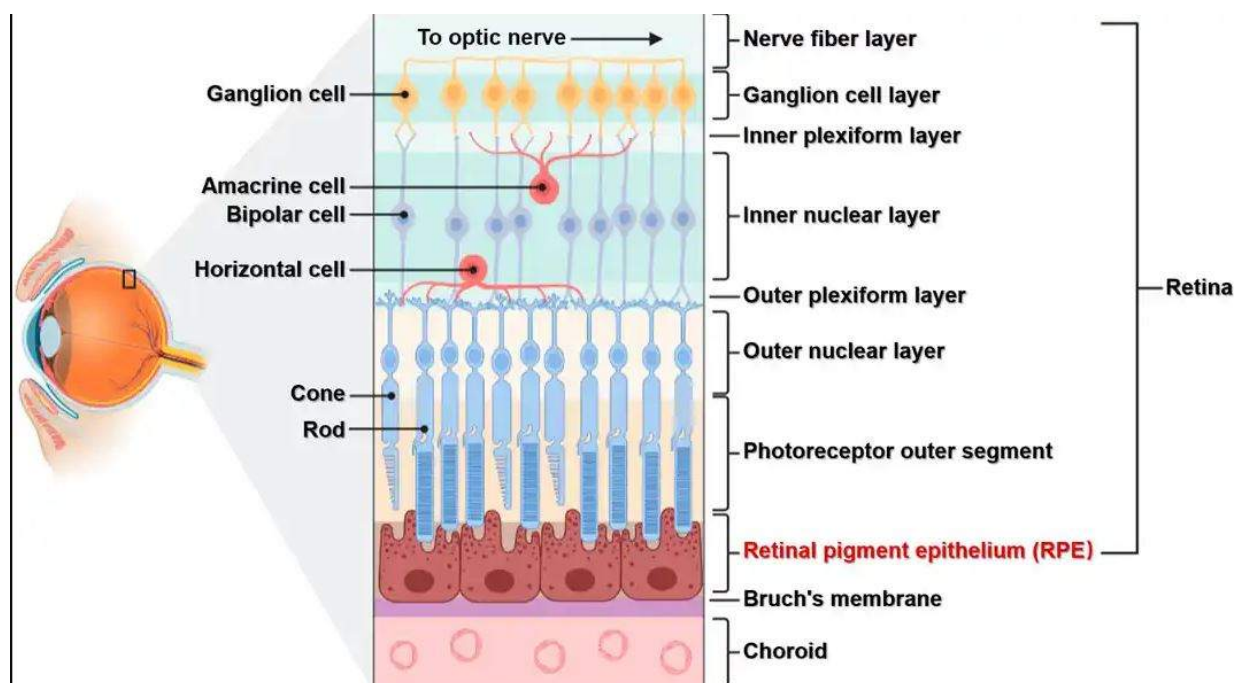
## Nervous Tunic or Retina

The nervous tunic and the retina are one in the same. The retina lines the posterior two-thirds of the inner eye as it sits between the choroid and vitreous fluid. It's a vital neural connection to the brain; some consider it merely an extension of the brain. The retina has photochemicals that convert light energy into electrochemical messages carried back to the visual cortex of the brain for interpretation. The retina is attached to the globe at the optic disc and at the ora serrata very firmly, stronger than any other attach points.

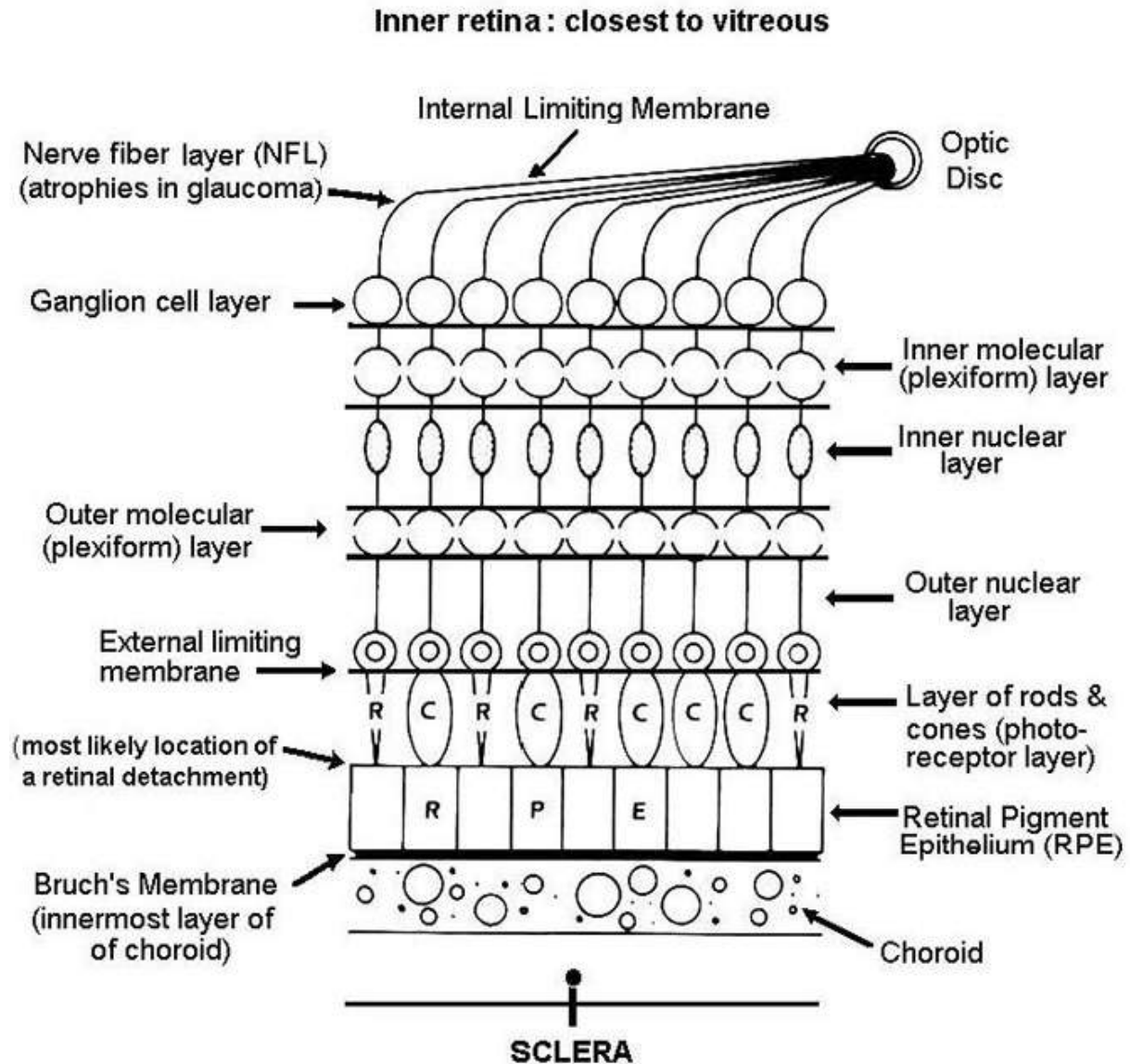
A significant landmark of the retina is the macula lutea, usually called the macula. The macula is 1.5 mm in diameter and is in the very center of the retina. The macula, disk, vortex veins, and equator make up the posterior pole.

In the center of the macula is the fovea centralis or foveola, often called the fovea. The fovea is the absolute center of our vision and is the site of our clearest vision. In addition, it's where we get our most sensitive color vision. The fovea is also unique, as it's actually a little depression in the retina.

When you look at pictures depicting the eye, they show the fovea as a little divot or dip in the retina. When looking at the fovea of a healthy eye through your retinal camera, it actually seems to shine or reflect some of the light back. This is because of the differences in elevation from the rest of the retina.



Retinal Layers



## Retinal Layers

The retina has 10 layers; each has physiological functions to perform. From the outermost layer (closest to the choroid) to the innermost layer (in contact with the vitreous), the layers are as follows:

- Retinal pigment epithelium (RPE)
- Layer of rods and cones (photoreceptor layer)
- External limiting membrane

- Outer nuclear layer
- Outer molecular (plexiform) layer
- Inner nuclear layer
- Inner molecular (plexiform) layer
- Ganglion cell layer
- Stratum opticum, or nerve fiber layer
- Internal limiting membrane

As an eye technician, it really isn't necessary for you to know what each layer does; however, you should know some facts about some of the more frequently referred to layers.

Being a professional, you'll want to be conversant with your doctor and aid your patients in understanding their eye problems as they relate to retinal function.

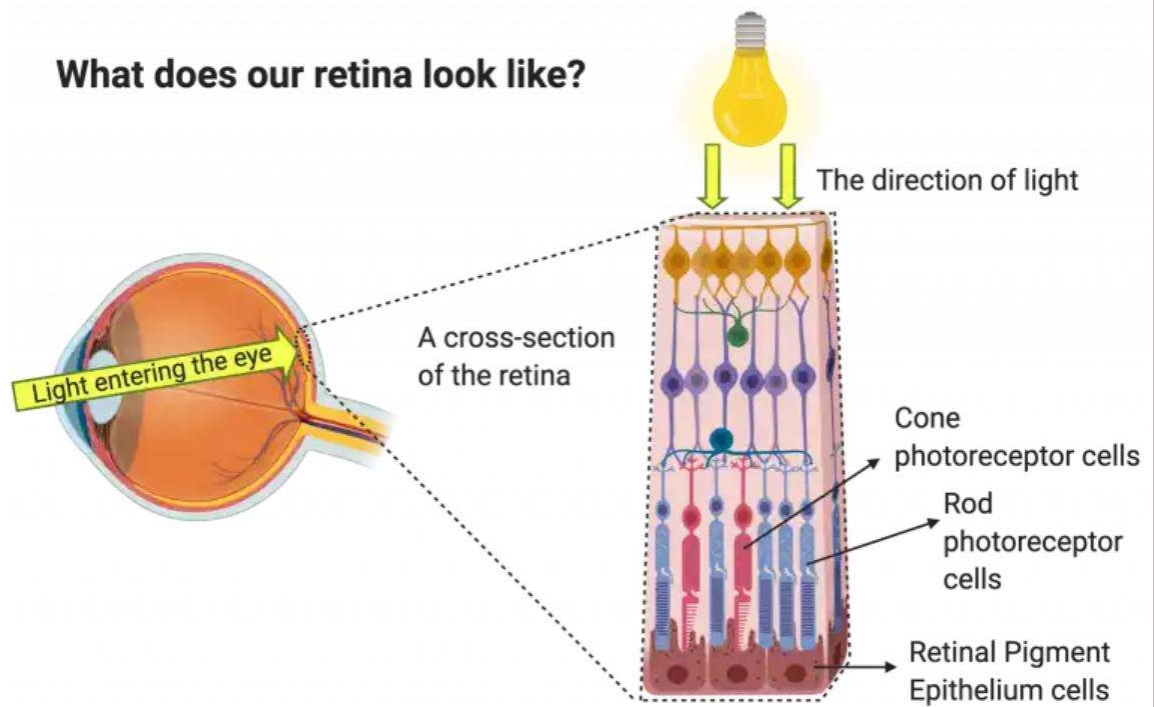
## **RPE**

This is the outermost layer, meaning it's closest to the choroid. Nine of the 10 retinal layers are transparent, but this layer is a highly pigmented layer. The RPE's job is to absorb excess light and serve as a nourishing and garbage collection layer for the rods and cones.

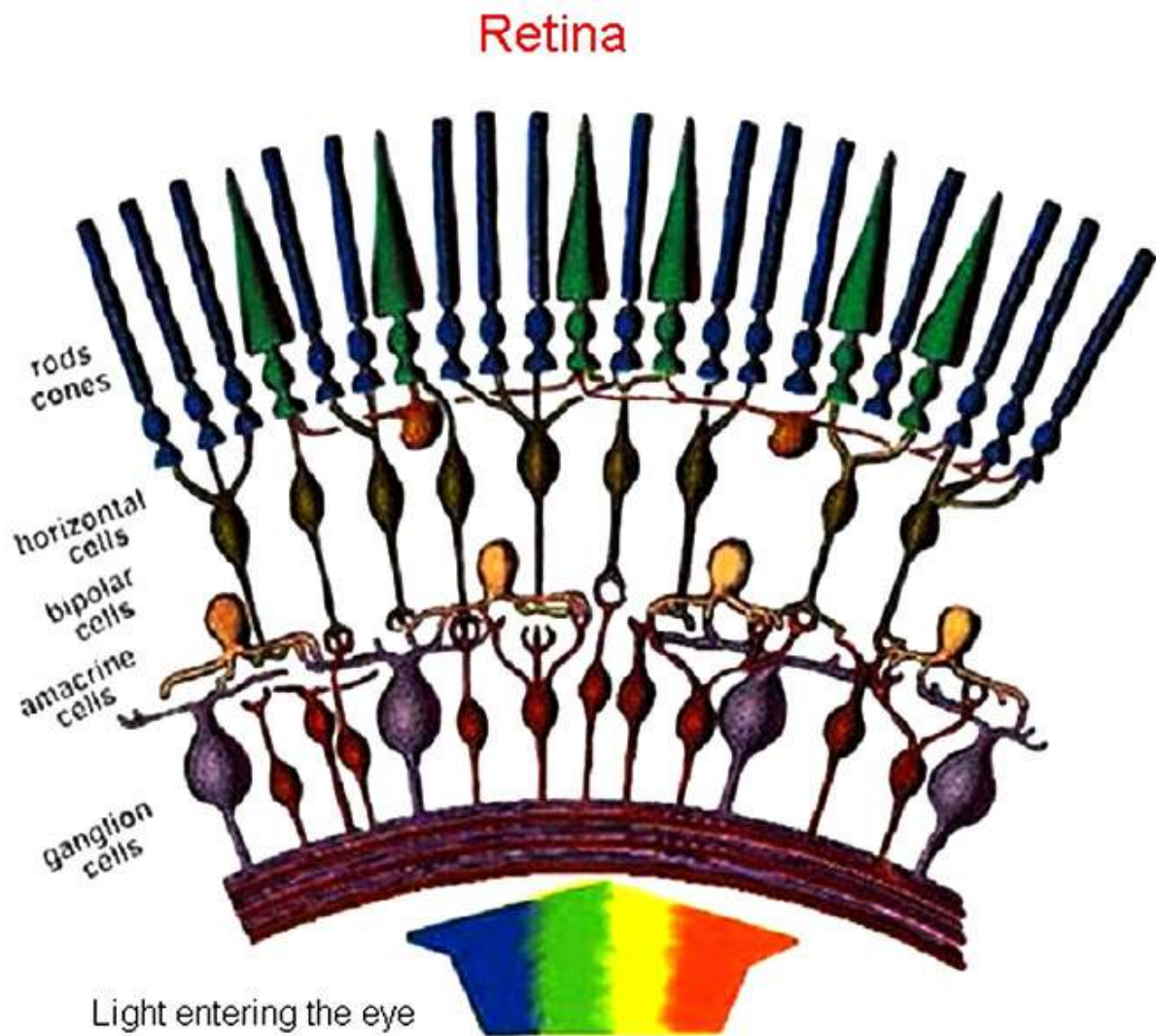
When people look at the retina, they are really looking at this layer, since all the others are transparent. The color of the RPE layer varies, just as our skin color varies.



## What does our retina look like?







Photoreceptor layer (rods and cones)

---

### Photoreceptor Layer (Rods and Cones)

This layer has the highly specialized cells known as the photoreceptors (rods and cones), which are responsible for converting the light striking them into electrochemical nerve impulses.

The rods and cones process electromagnetic radiation with wavelengths in the 750 nanometers (nm) (red) – 400 nm (violet) range, which is considered the visible spectrum of light.

There are approximately 125 million rods in the retina. Rods are primarily for night vision, also known as scotopic vision. Most rods are in the periphery of the retina, so they handle much of our peripheral vision.

The visual pigment rods contain is called rhodopsin; it's this pigment that helps the rods convert light into the electrochemical nerve impulses sent to the brain.

There are approximately six million cones in the retina. Cones are predominantly in the macula and fovea, but can also be found throughout the retina. There are no rods in the fovea; it's exclusively cones. This explains the fovea's extremely detailed clarity and super color vision traits. It also explains why we see more poorly at night; we need rods for low-light vision, and the fovea has none. The cones function best under photopic or fully illuminated conditions, like daylight.

Cones provide our color vision, and they do this in much the way your color television works. The TV projects only three colors--red, green, and blue. Yet you see all the colors of the rainbow on TV. This is because mixing red, green, and blue can create any other color.

### **Photoreceptor Layer (Rods and Cones)**

Your retina has at least three different types of cones, each sensitive to a different color. The cone sensitive to red has a visual pigment called erythrolabe (erythro is Greek for red). The green-sensitive cone has a pigment called chlorolabe (remember this by thinking of green plants producing chlorophyll).

The cone sensitive to blue contains a visual pigment called cyanolabe (cyan being the color blue). By stimulating the red-, green-, and blue-sensitive cones in various amounts, the brain receives electrochemical messages from each and interprets the actual color seen. The following table should help you remember the pigments that relate to rods and cones.

Eye Pigments	
Photoreceptor	Visual Pigment
Rods	Rhodopsin.
Red-sensitive cones	Erythrolabe.
Green-sensitive cones	Chlorolabe.
Blue-sensitive cones	Cyanolabe.

### Bipolar Layer

This layer is like the operator at the switchboard of the retina. It passes the electrochemical message produced by the rods and cones to the retinal ganglion layer of the retina. Without this layer, the rods and cones could be “screaming” away a message for the brain, but the message would never get there.

### Ganglion Cell Layer

This layer is composed of ganglion cells with their long axons, which act like telephone cables carrying the retinal message (received from the bipolar layer, which came from the rods and cones) to the brain.

All these ganglion cell axons come from every part of the retina and extend toward the optic nerve, where they leave the eye, and run back toward the brain.

These massive bundles of fibers, all extending toward the optic nerve head, form the nerve fiber layer. This layer becomes damaged in people with glaucoma, limiting the amount of information the brain can receive from the eye.

Retinal Blood Supply Sources	
Source	Description
CRA	The CRA (and central retinal vein [CRV]) forms the vascular system for the inner two-thirds of the retina. The CRA divides into four branches and nourishes the corresponding region of the retina: superior and inferior temporal branches and the superior and inferior nasal branches. The CRA also nourishes the ganglion cells and bipolar cells. The CRV follows a similar pattern as the CRA.
Choriocapillaris	The outer one-third layer of the retina (rods, cones, and RPE) is nourished by the choriocapillaris (the innermost layer of the choroid).

## Retinal Blood Supply

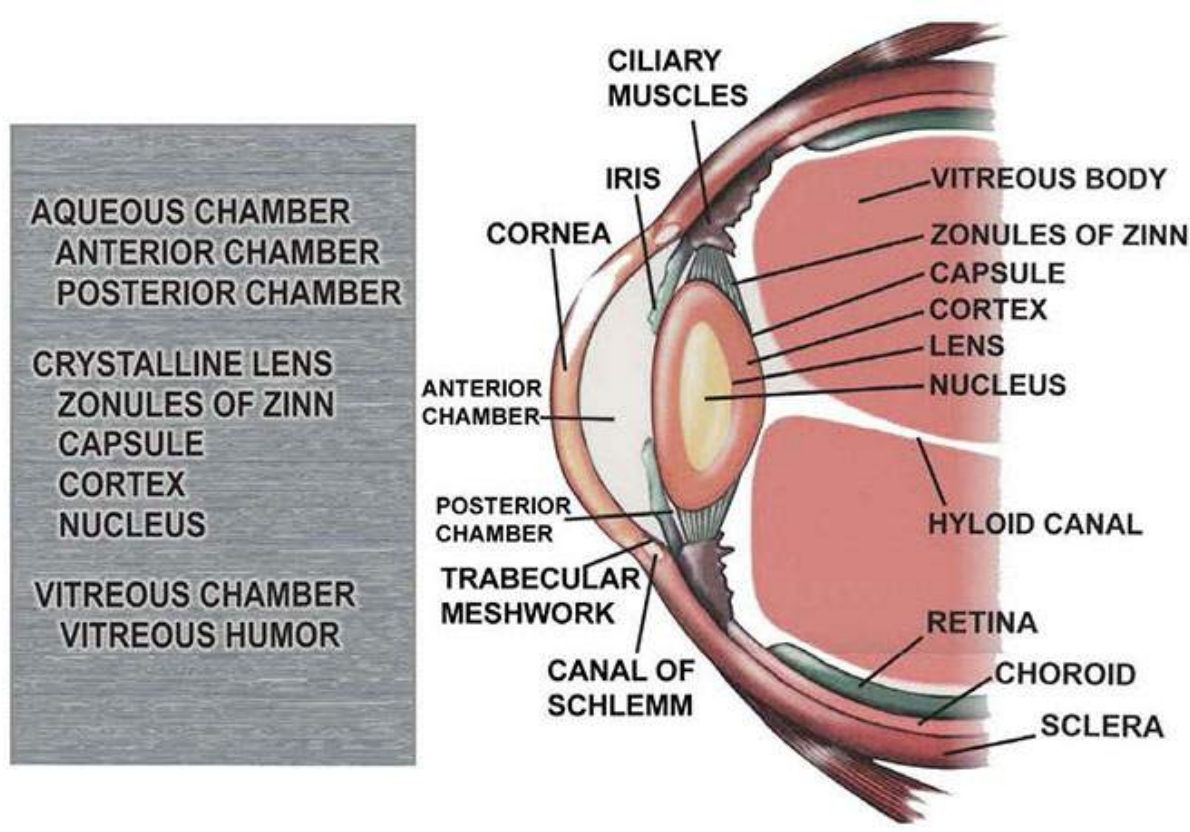
The retina receives its blood supply from two separate sources--the central retinal artery (CRA) and choriocapillaris.

These vessels enter and leave the eye at the optic disc. The following table describes these two sources of retinal blood supply.

### Ocular Media

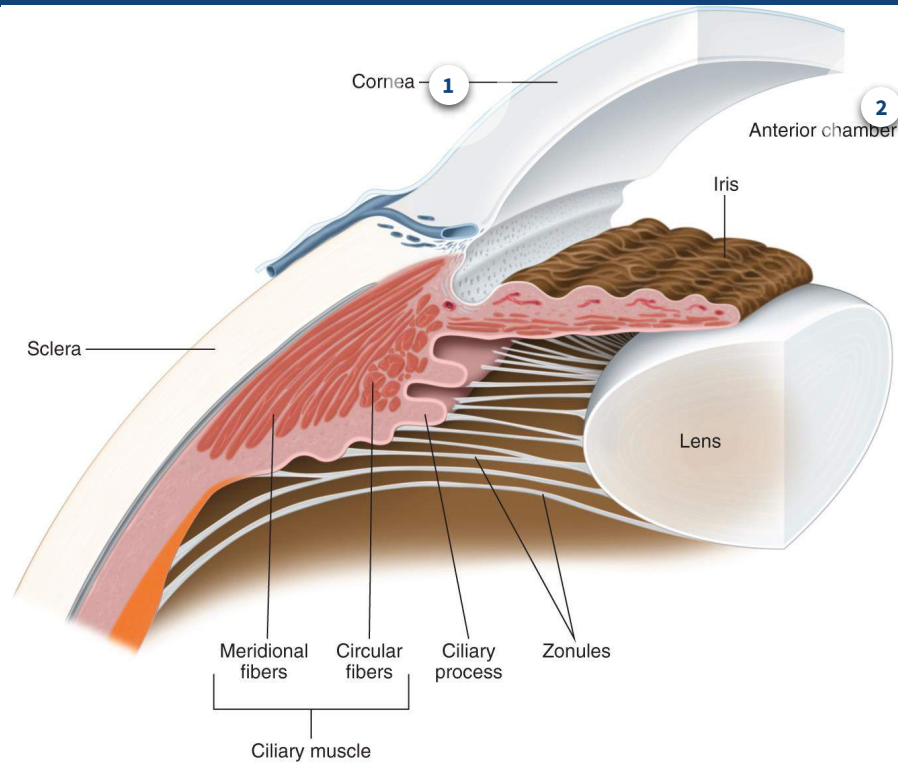
The ocular media are the transparent optical surfaces and liquids within the eye. They are the structures or fluids light must pass through before reaching the retina.

The total refractive power of the ocular media in an adult is between +58.00D and +60.00D. The ocular media includes the cornea, aqueous humor, crystalline lens, and vitreous humor.

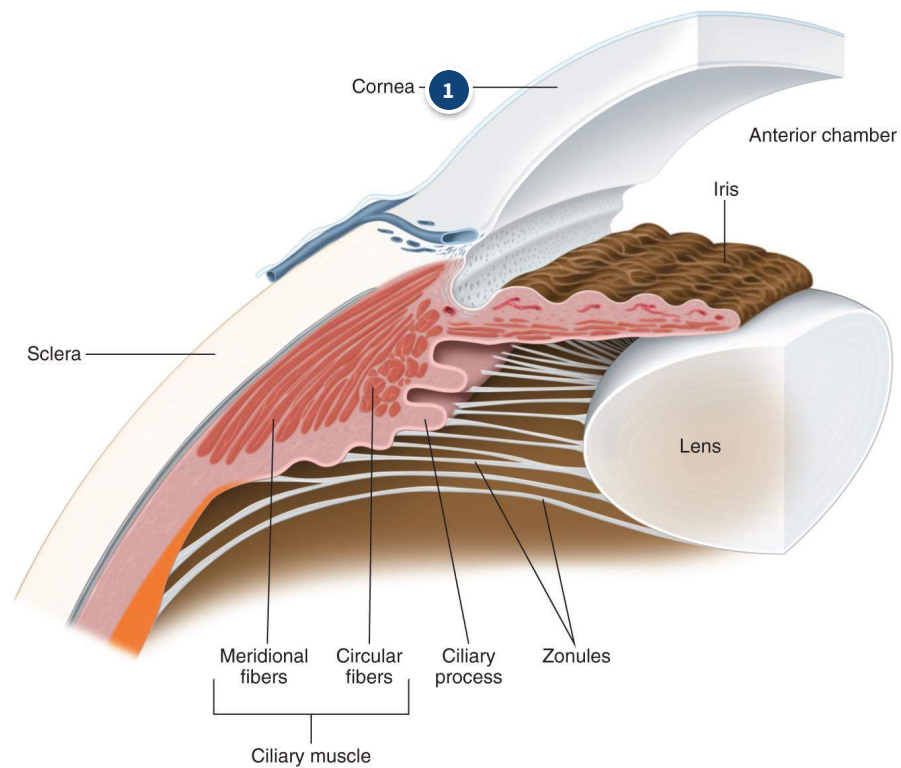


Ocular media.

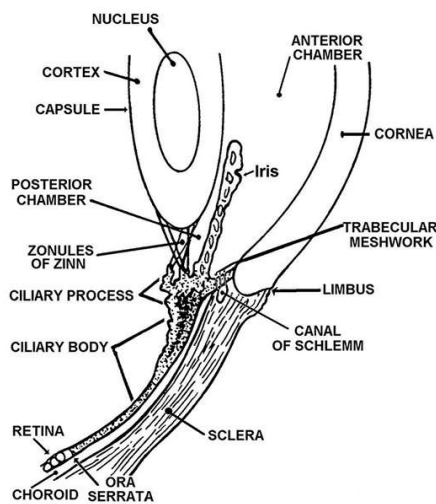
Click on each number below to learn about the cornea and anterior chamber of the eye.



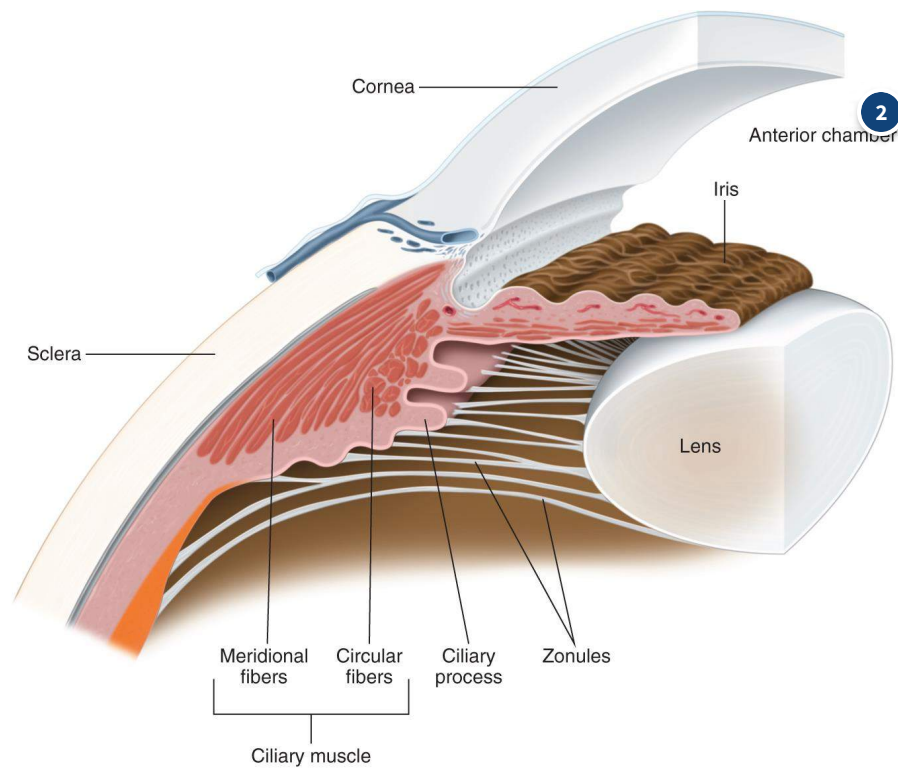




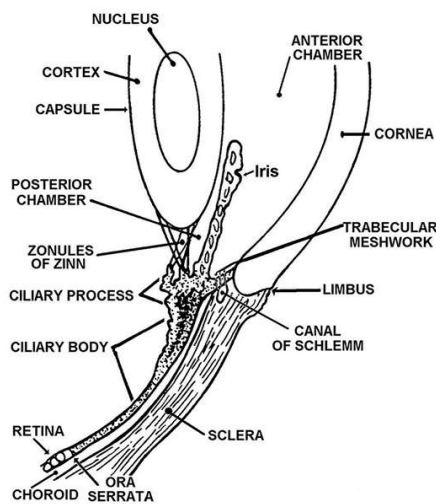
## Cornea



The cornea was covered under the fibrous tunic lesson, so we won't cover it again here; however, an important point to keep in mind is the cornea has five layers and provides the most refractive power for the eye (approximately +43.00D).



## Anterior Chamber (Aqueous humor)



The aqueous humor is a clear, watery fluid filling the anterior and posterior chambers of the eye (essentially everywhere anterior from the ciliary processes). The aqueous humor can be considered a blood supply substitute for the lens, cornea, and trabecular meshwork since all are avascular. The aqueous contains the essential nutrients for these tissues and removes all waste products..

The ciliary processes through methods of secretion, ultra filtration, and diffusion produce the aqueous fluid of the eye. The aqueous flow begins in the posterior chamber (do not confuse this with the vitreous chamber). It then flows through the pupil to the anterior chamber. From there, it's drained out of the eye through the canal of Schlemm, after passing through the trabecular meshwork (a filter of sorts for the canal).

The trabecular meshwork and canal of Schlemm are located inside the eye just behind the limbus (cornea/sclera junction). Aqueous production and outflow is a continuous process maintaining the IOP within the eye. Additionally, the aqueous also serves as a refractive media in the anterior chamber.



Complete the content above before moving on.

## Crystalline Lens

The crystalline lens lies directly behind the iris, is about 10 mm in diameter, and has a refractive power of approximately +16.00D. It's a biconvex lens with a shorter radius of curvature (steeper curve) on the front surface. The fine fibers, known as the Zonules of Zinn, connect the crystalline lens to the ciliary body. The primary job of the crystalline lens is to perform accommodation (focusing) for the eye.

It's very pliable in young people, but hardens with age. As we age, the lens continues to produce cell material, but the older cell material is not discarded, causing hardening of the crystalline lens. Due to its flexibility in children, the power of the lens can increase by as much as +14.00D. This flexibility decreases with age, so by age 70 the lens can only increase its power about +0.12D.

The lens consists of three parts—capsule, cortex, and nucleus. The lens capsule is the outermost layer and is especially thickened around its periphery where the Zonules of Zinn attach. Think of it as the clear bag holding the cortex and nucleus. The cortex is a gelatinous, watery mass surrounding the nucleus. The nucleus is the thick dense center of the lens. Remember, the purpose of the lens is to fine-focus light rays on the fovea centralis. It has no blood or nerve supplies, and is completely clear, unless a cataract develops.

## Vitreous Humor

The vitreous humor is a clear, jelly-like substance contained in the vitreous chamber of the eye and is posterior to the crystalline lens (fig. 1-14). The vitreous consists of mostly water, 99 percent water in fact. The other 1 percent has two components—hyaluronic acid and collagen. These two components give the vitreous a gel-like form and consistency since they can bind large volumes of water.



The vitreous accounts for two-thirds of the eye's volume and weight. The vitreous humor within the vitreous chamber is encapsulated in a thin vitreous membrane, which keeps the vitreous contained in the vitreous chamber so it doesn't flow forward, mix with the aqueous, and drain out of the eye. The vitreous humor provides internal support and helps the eye maintain its shape. It also helps keep the retina pressed up against the choroid, where it belongs.

Unlike the aqueous, the vitreous does not regenerate or reproduce itself. Consequently, a perforating injury allowing the vitreous to escape is very bad since it could allow the eye to collapse, potentially leading to loss of the entire eye. Even if the eye is saved, any vitreous lost is gone for good and is not regenerated.

**Self-Test Questions. After you complete these questions pertaining to the eyeball anatomy , you may check your answers at the end of this module.**

1. What structures make up the fibrous tunic?

Type your answer here

---

SUBMIT

2. How big is an adult's cornea?

Type your answer here

---

SUBMIT

3. What is the primary job of the cornea?

Type your answer here

SUBMIT

4. The cornea is avascular. What does this mean?

Type your answer here

SUBMIT

5. Which CN innervates the cornea?

Type your answer here

---

SUBMIT

6. Name the corneal layers from anterior to posterior.

Type your answer here

---

SUBMIT

7. How long does it usually take before a scratched epithelium heals? Will it be scarred?

Type your answer here

---

SUBMIT

8. Describe Bowman's layer.

Type your answer here

---

SUBMIT

9. Which corneal layer(s) does the substantia propria rely on to keep it at the proper hydration level?

Type your answer here

---

SUBMIT

10. What happens if the stroma starts to absorb too much fluid?

Type your answer here

---

SUBMIT

11. How thick is the endothelium?

Type your answer here

---

SUBMIT

12. What is the endothelium's function?

Type your answer here

---

SUBMIT

13. How long does it take the endothelium to regenerate new cells when the old ones are damaged or destroyed?

Type your answer here

---

SUBMIT

14. What does the sclera do?

Type your answer here

---

SUBMIT

15. What is the weakest point in the sclera?

Type your answer here

---

SUBMIT

16. What tissue surrounds the sclera?

Type your answer here

SUBMIT

17. List another name, or term, for the vascular tunic.

Type your answer here

SUBMIT

18. What is the color of our eyes based on?

Type your answer here

---

SUBMIT

19. What is the primary function of the iris?

Type your answer here

---

SUBMIT

20. What two muscles are in the iris?

Type your answer here

---

SUBMIT



21. What are the sections of the ciliary body? Which has the majority of structures in it?

Type your answer here

---

SUBMIT

22. What produces aqueous humor?

Type your answer here

---

SUBMIT

23. What must the ciliary muscle be doing if the Zonules of Zinn are being pulled tightly?

Type your answer here

---

SUBMIT

24. When the eye accommodates (focuses), what's happening with the ciliary muscle, zonules, and crystalline lens?

Type your answer here

---

SUBMIT

25. What is the name of the eye disorder where the pars plana becomes inflamed?

Type your answer here

---

SUBMIT

26. What structures does the choroid supply blood to?

Type your answer here

---

SUBMIT

27. What is the anterior termination point of the choroid called?

Type your answer here

---

SUBMIT

28. What structure is the same as the nervous tunic?

Type your answer here

---

SUBMIT

29. At what two points is the retina attached to the globe stronger than any other attach point?

Type your answer here

SUBMIT

30. If the center of the retina is the macula, what is the depressed area in the center of the macula called?

Type your answer here

SUBMIT

31. What retinal layer is closest to the choroid? To the vitreous?

Type your answer here

---

SUBMIT

32. How many retinal layers are there? How many are transparent?

Type your answer here

---

SUBMIT

33. What is the RPE's function?

Type your answer here

---

SUBMIT

34. What is the photoreceptor layer?

Type your answer here

---

SUBMIT

35. What is the shortest wavelength the photoreceptors can see? The longest?

Type your answer here

---

SUBMIT

36. How many rods are in the retina? How many cones?

Type your answer here

---

SUBMIT

37. What is the visual pigment in rods called?

Type your answer here

---

SUBMIT

38. What are the best conditions for cones to function in?

Type your answer here

---

SUBMIT

39. What is the visual pigment in the red cones? Green cones? Blue cones?

Type your answer here

---

SUBMIT

40. What does the bipolar layer of the retina do?

Type your answer here

---

SUBMIT

41. What part of the ganglion cells act like telephone cables for retinal messages going to the brain?

Type your answer here

---

SUBMIT



42. What two structures deliver the retina its blood supply?

Type your answer here

---

SUBMIT

43. What structures form the ocular media?

Type your answer here

---

SUBMIT

44. What is a continuous process that maintains the IOP within the eye?

Type your answer here

---

SUBMIT

45. How big is the crystalline lens? How much refractive power does it have?

Type your answer here

---

SUBMIT

46. Name the three parts of a lens.

Type your answer here

---

SUBMIT

47. What is the vitreous encased in?

Type your answer here

---

SUBMIT

48. What function does the vitreous serve?

Type your answer here

SUBMIT

49. If lost, how long does it take for vitreous to regenerate?

Type your answer here

SUBMIT



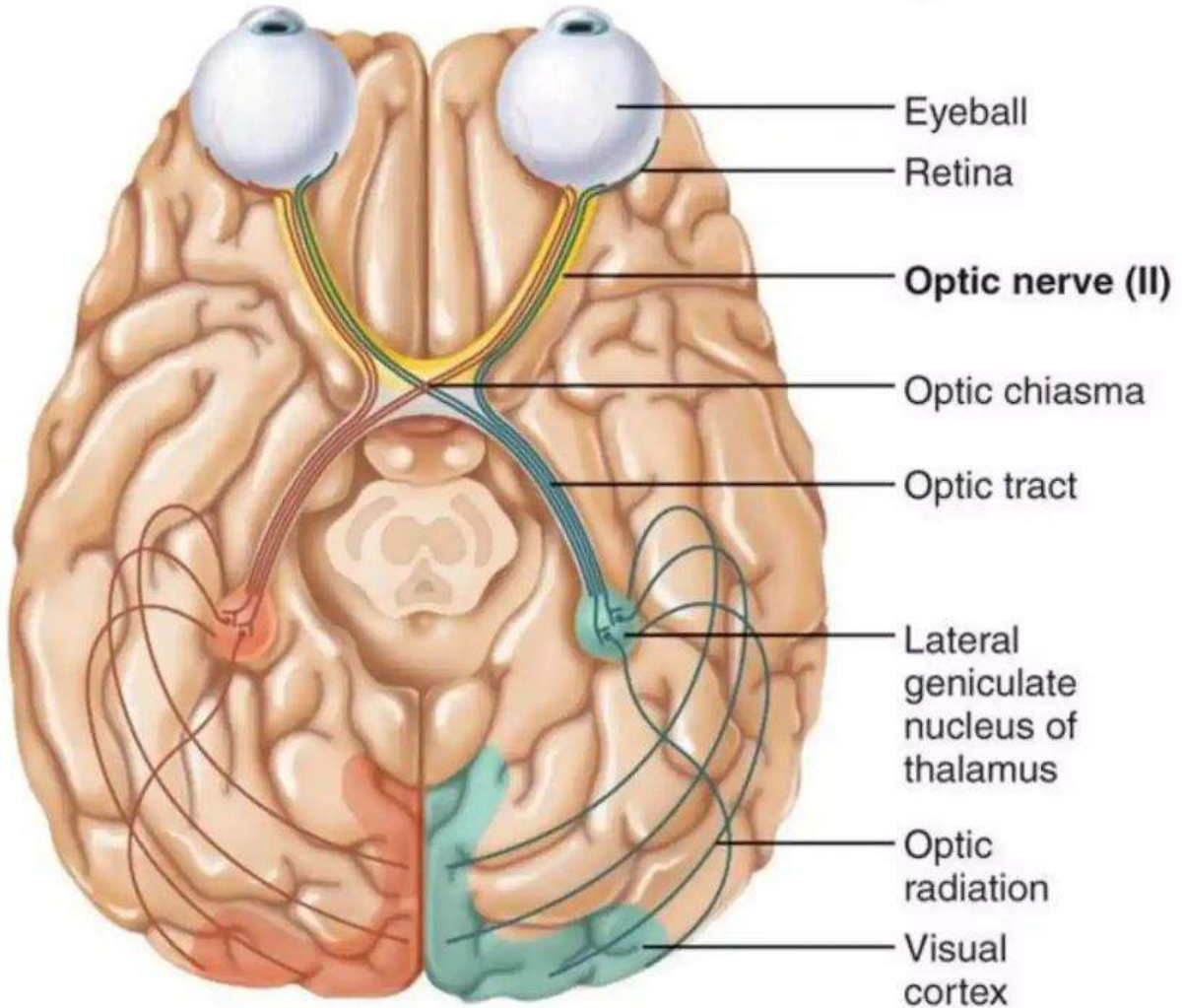
Complete the knowledge check questions before moving forward in the lesson.

## Visual-Pupillary Pathway

The visual pathway is defined as the path taken by the nerve impulses between the retina of the eye and the visual cortex of the brain when the retina is stimulated by light. Let's be clear, the retina does not send a picture image to the cortex of the brain. Vision is more complex than this. When the retina of the eye is stimulated by light coming off an object, it sends an electrochemical message to the cortex.

The cortical area of the brain decodes, or interprets, the message as an image. This is a simple explanation to how we see. Think of the visual pathway as the "information highway" for visual messaging information to get from the retina to the decoding center of the brain--the cortex.

# The Visual Pathway



Afferent Visual Pathway

## Visual (Afferent) Pathway

The visual pathway is an afferent (sensory) pathway, which essentially means information is going to the brain. Think of afferent as “a feeling.” You may have felt you saw something, but until the brain interprets the afferent message, you don’t know what you saw.

The opposite of afferent is efferent, which are nerve impulses exiting the brain. Efferent messages are covered in more detail when you get to pupillary pathways lesson.

The visual pathway consists of the following seven structures:

- Retina
- Optic nerve
- Optic chiasm
- Optic tract
- Lateral geniculate body (LGB)
- Optic radiations
- Visual cortex area (aka Brodmann area 17)

These structures make up the three orders of neurons linking the retina to the cortex of the brain. Let's start by looking at the seven individual structures making up the visual (afferent) pathway, and then, look at how they form the three orders of neurons.

## Retina

The retina is the light-sensitive tissue in the back of the eye. It's composed of 10 layers, but in this lesson, you're really only interested in two—rods and cones (photosensitive layer) and the ganglion cell. As we've said, the retina converts the light striking it into an electrochemical impulse. This impulse is the message sent to the brain. The rods and cones fire their message across a synaptic gap to the ganglion cells of the retina.

Once the ganglion cells receive the message, they carry it all the way from the retina to the LGB, where they finally pass on the message so it can continue to the visual cortex; however, we're getting ahead of ourselves, so let's get back to the retina.

Visualize the retina divided into four quadrants. The superior and inferior are in one half, and a temporal and nasal are in the other half. The fovea centralis is considered the exact center of the retina. The optic nerve head is located on the nasal retina. It shows up temporally on a visual field test. When you consider the superior/inferior and the temporal/nasal divisions of the retina together, you can see the retina as having the following four distinct quadrants:

- Superior temporal

- Superior nasal
- Inferior temporal
- Inferior nasal

Understanding the four quadrants is important in visual field testing. What appears in your superior field of view hits your inferior retina, what appears in your temporal field of view hits your nasal retina, and so on. Whichever field of view an object appears to you, the light rays from the object falls on the opposite portion of your retina. For example, close your left eye and look straight ahead with your right. If you hold your finger above your right eye, it's in the superior field of view. Now, the light rays coming off your finger are entering your eye from above and actually end up hitting your inferior retina.

The brain gets the message that light rays are hitting the inferior retina, and it knows the object being seen must be above the eye. You don't think about it or need to do any mental analysis, the brain just knows since it has been like this all your life. Now, leave your finger above your right eye, but move it temporally. Now, your finger is in your superior and temporal field of view. The light rays come into your eye from above and temporally.

They then, logically, end up striking your inferior, nasal retina. Wherever you see an object in your field of view, the light rays coming from it are actually hitting in the exact opposite portion of your retina. If a car is in the temporal field of view of your right eye, the light rays coming from it strike the nasal retina of the eye. If a plane is flying in your superior field of view, the light rays coming from it hit your inferior retina.

Where do the light rays strike the retina if an object appears in the inferior, nasal field of view? If you said the superior, temporal retina, you did great and understand the concept. This division of the retina into quadrants, and the understanding the difference between where something appears in our field of view and where the light rays from the object actually strike our retina are very important in visual field testing. For example, it can help you and your doctor decide if a person's visual field loss is due to glaucoma, a tumor, or just droopy eyelids.

Your eye is a lot like a camera in regards to field of view and area of retina stimulated. When you look at someone through a camera, they look upright, but the light rays from the person are flipped upside down and reversed by the optics of the camera before the light rays strike the film. This is just like your eye. When the image of the person hits the film, what was superior strikes the film inferiorly; what was temporal

strikes the film nasally. If you can think of the ocular media of your eye as being like the optics of the camera and your retina as being like the film, it may make this whole concept easier to understand.

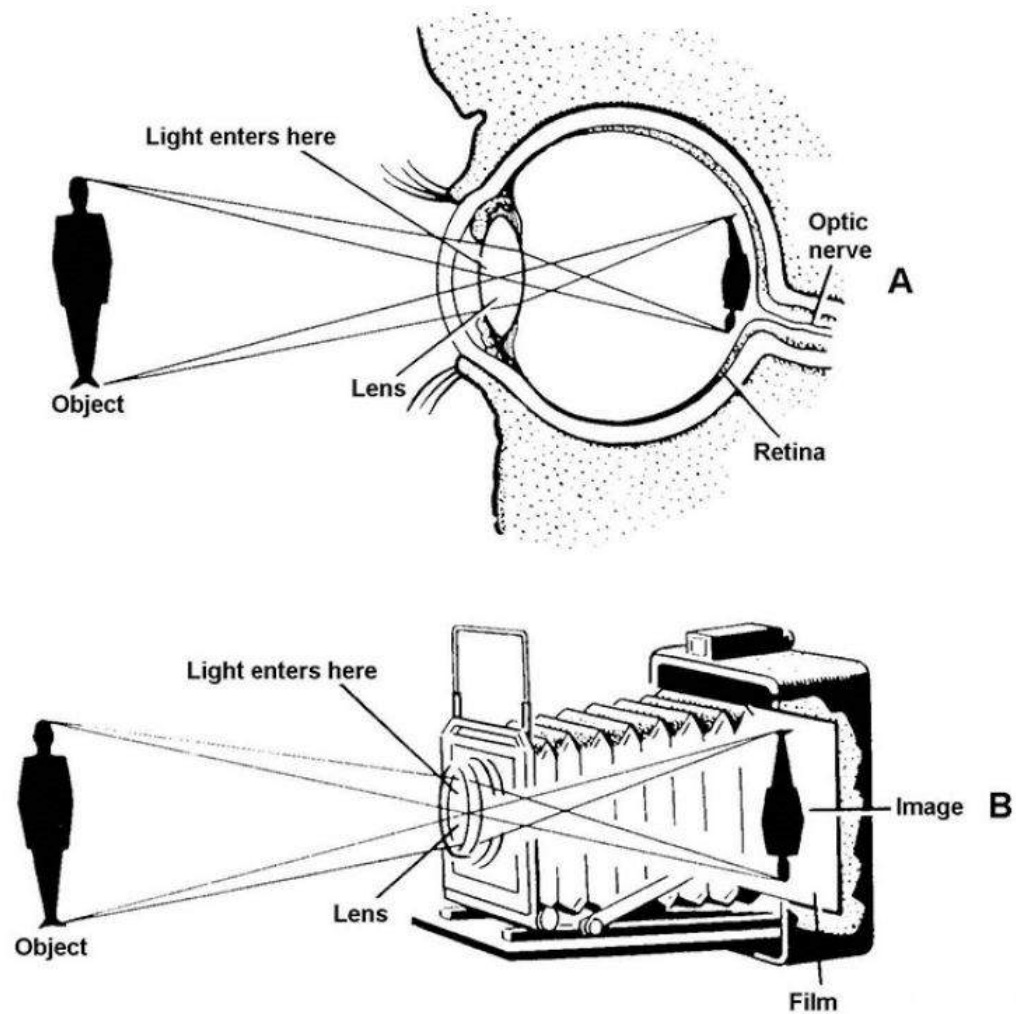


Figure 1-17. Inversion of visual images.

## Optic Nerve

The optic nerve consists of the ganglion cell axons from the retina. Remember, the ganglion cells received the visual message from the rods and cones. These ganglion cell axons now carry visual messages from the retina out through the optic nerve head or disk. If you did not realize it already, the optic nerve head doesn't



have any rods or cones and is the reason we have a physiological blind spot in each eye. This physiological blind spot is shown on each visual field (VF) test you run correctly.

The optic nerve is the CNII and is really just composed of all the ganglion cell axons from the retina. This nerve extends from the posterior of the eye, through a hole in the lesser wing of the sphenoid (the optic foramen), and to the optic chiasm.

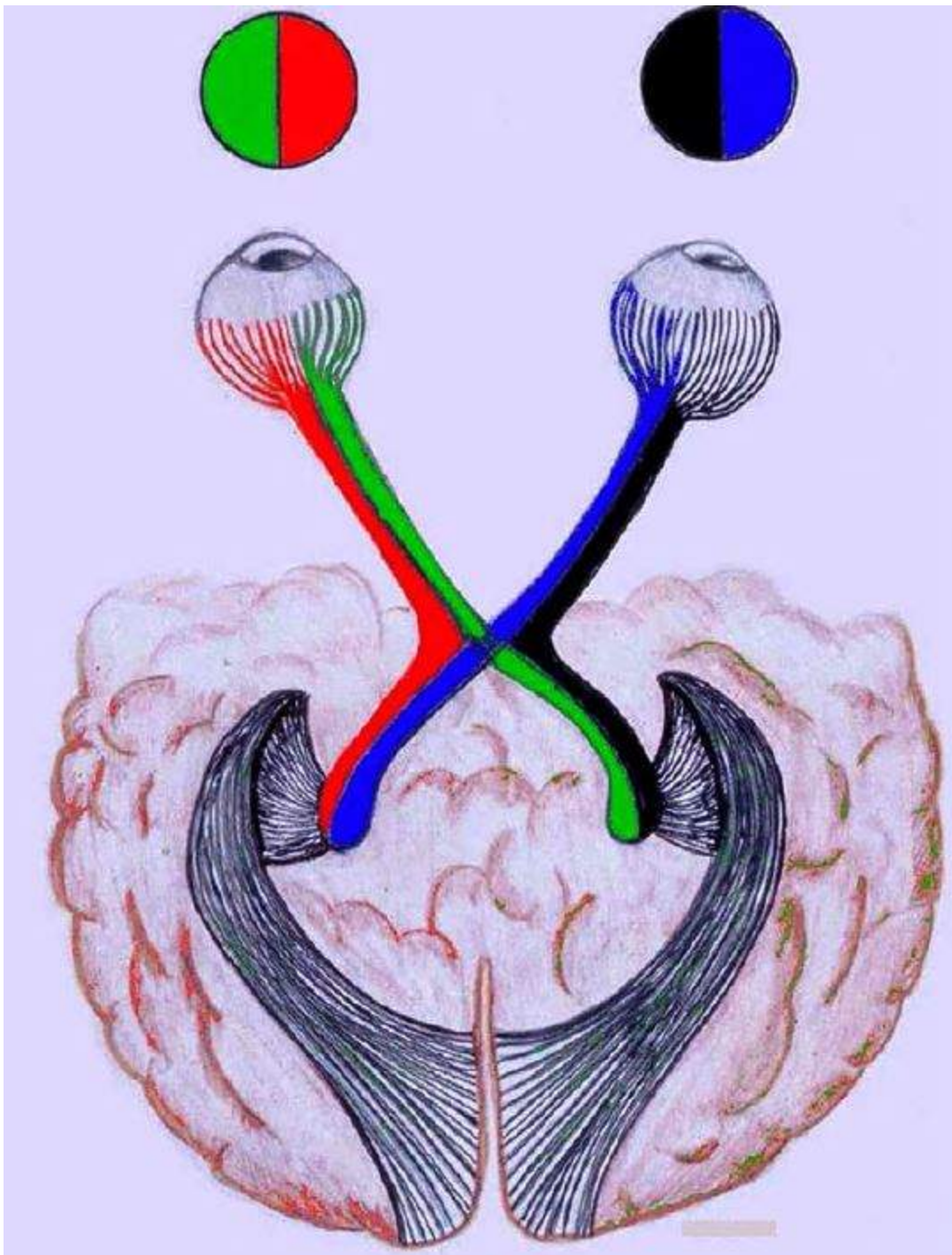


Figure 1-18. Visual pathway highlighting right and left visual fields.

## Optic Chiasm

The optic chiasm is the point where each optic nerve divides in half and crosses to the other side (fig. 1-18). The ganglion cell axons from the nasal retina cross over inside the chiasm to the other side of the head.

Nasal fibers entering the optic chiasm on the right side exit the chiasm on the left side. The same process occurs for the left eye.

The ganglion cell axons from the temporal retina do not cross. They stay on the same side of the head (e.g., the temporal fibers from the right eye stay on the right side of the brain). Same thing for fibers leaving the left eye--they remain on the left side of the head. So, the optic chiasm is the crossing point for the nasal retina's ganglion cell axons. The temporal retina's ganglion cell axons continue on without crossing. Simply stated, nasal fibers cross at the optic; chiasm temporal fibers do not.

## **Optic Tract(s)**

The optic tract(s) consists of the temporal ganglion cell axons from one eye and the nasal ganglion cell axons from the other eye. The optic tract carries this mixture of retinal fibers from each eye to the LGB.

## **Lateral Geniculate Body**

The LGB is located on each side of the midbrain. It's easily remembered as a neural "relay station" where the optic tract fibers (which are really just ganglion cell axons beginning at the retina) pass on their message to the optic radiations. The message carried by the optic tract is fired across a synaptic gap in the LGB and is picked up by the optic radiations.

For each ganglion cell axon leaving the retina and reaching the LGB, there is a matching fiber in the optic radiations to carry on its message. This passing on of the visual message in the LGB accounts for why the LGB is often called a relay station. That is essentially its job, providing a place for the optic tract fibers to pass on their message to the optic radiation fibers.

## **Optic Radiations (Geniculo-Calcarine Tract)**

This area of the brain contains widespread visual fibers representing the temporal fibers of one eye and the nasal fibers of the other. It carries the visual impulses to the occipital lobe/visual cortex.

## **Visual Cortex (Brodman Area 17)**

The Brodmann area 17 in the occipital lobe of the brain contains the visual cortex, which is responsible for initial conscious registration of visual information. It's the cerebral end of the afferent (sensory) visual pathway. This is the area in the brain that decodes the visual message originating at the rods and cones of the retina. In Brodmann terminology, it's area 17 of the brain.

Just for fun, Brodmann area 18 connects area 17 to area 19. Brodmann area 19 is associated with pursuit or following eye movements. Isn't it amazing how all these things are interconnected and allow us to see the way we do? Next, you have to tie all this together so you can see how the visual pathway makes up the three orders of neurons before moving onto pupillary pathways.

## Three Orders of Neurons

The afferent (sensory) visual pathway consists of three orders of neurons; meaning information goes through three separate links to get from the rods and cones of the retina to the visual cortex of the brain.

Think of the three orders of neurons in terms of telephone communications. When you speak into a phone, your phone encodes your words into electrical impulses, which goes to a satellite. This is like the first order neuron (rods and cones to the ganglion cells of the retina). From the satellite, these electrical impulses pass to the other person's phone.

This is like the second order neuron (ganglion cell axons going through the optic nerve, optic chiasm, optic tract, and on to the LGB). The receiving phone takes the electrical impulses and decodes them back into words. This is the third order neuron (LGB, optic radiations, to visual cortex). Those three orders of neurons break down like this:

1. The first order neuron goes from the rods and cones of the retina to the ganglion cells of the retina. The rods and cones have to send their electrochemical message across a slight gap, called a synaptic gap, to get their message to the ganglion cells.
2. The second order neuron extends from the ganglion cells of the retina, along the ganglion cell axons, through the optic nerve, optic chiasm (remember the nasal fibers crossed over to the other side of the brain here), through the optic tract, to the LGB. The second order neuron is quite long in comparison to the first order neuron! This second order neuron is made entirely of the ganglion cell axons originating in the retina. Now the message carried by the second order neuron to the LGB must be "fired" across a synaptic gap in the LGB to pass its message on to the third order neuron.

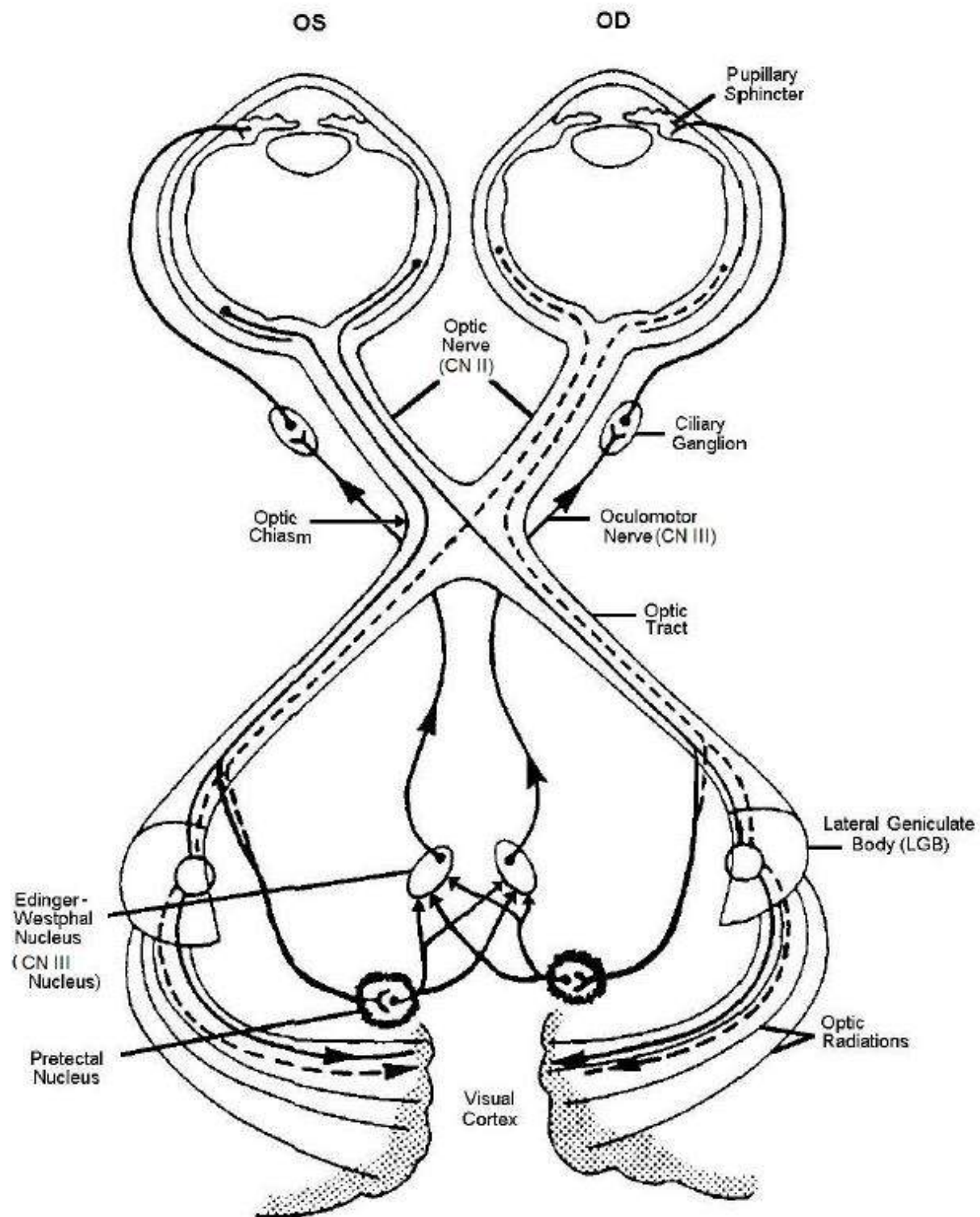
3. The third order neuron goes from the LGB through the optic radiations and to the visual cortex. The visual cortex finally decodes the message originated by the rods and cones of the retina.

The significance of the three orders of neurons is doctors can pinpoint visual problems, not caused by refractive errors, down to a particular neural area along the visual pathway. Testing can determine if a visual problem is occurring in the first, second, or third order neuron. This helps in correctly diagnosing problems and determining what treatment, if any, can be used. When you check the pupils with a penlight, you are actually checking the three orders of neurons making up the afferent visual pathway.

Keep in mind, a neuron is composed of a dendrite (receiver/transmitter), cell body (interpreter/message booster), and axon (message carrying line). Once the doctor has narrowed down which neuron has a problem, he or she can attempt to determine if the problem is in the dendrite, cell body, or axon of the neuron. For you and me, this doesn't mean much, but for a doctor to treat a patient correctly, it's very important. It's useful for you to at least understand what a neuron is and the fact the visual (afferent) pathway is composed of three orders of neurons.

## Pupillary Pathway (Afferent)

Tied closely to the visual pathway is the pathway for pupillary functioning. There is an afferent (sensory) pupillary pathway to the brain and an efferent (motor) pupillary pathway from the brain .



The afferent pupillary pathway consists of the retina, optic nerve (CN II), optic chiasm, optic tract, pretectal nucleus, and Edinger-Westphal nucleus of the oculomotor nerve. As you can see, the afferent pupillary pathway is the same as the visual pathway to a point. The pupillary pathway never gets to LGB. It splits off

from the optic tract before reaching LGB, goes to the pretectal nucleus, and continues on to the Edinger-Westphal nucleus.

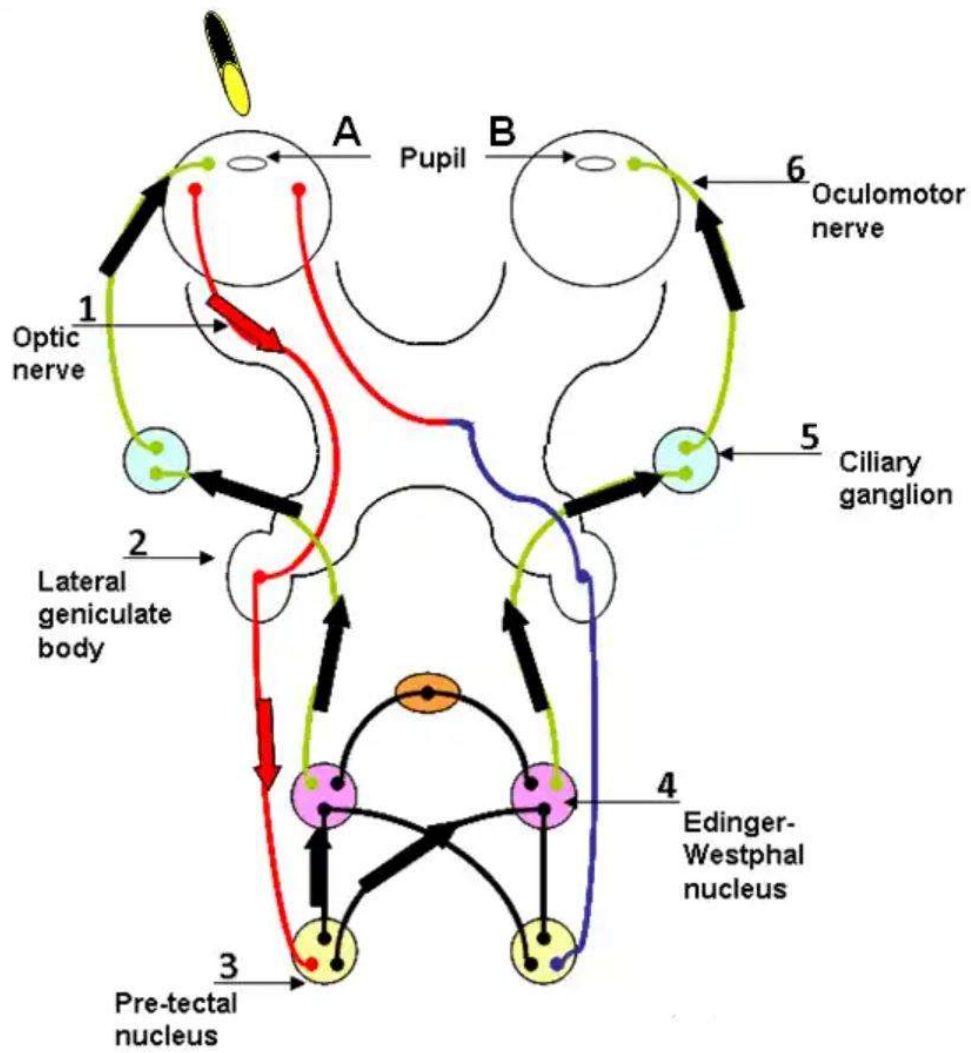
You can think of the afferent visual pathway as carrying the sight information and think of the afferent pupillary pathway as carrying the light message. The sight message must go to the visual cortex for interpretation, but the light message must get to the Edinger-Westphal nucleus for interpretation.

It's important to note the fibers leaving the pretectal nucleus do not just go to the Edinger-Westphal nucleus on one side of the brain; they leave the pretectal nucleus and go to the Edinger-Westphal nucleus on both sides of the brain. This ensures even if one pretectal nucleus is not functioning, the other pretectal nucleus transmits the message to both Edinger-Westphal nuclei.

Another way to look at it is an Edinger-Westphal nucleus receives afferent nerve fiber messages from both pretectal nuclei if they are both functioning correctly, even if only one eye has a light shining in it. Why? Remember, at the optic chiasm 50 percent of the afferent message carried by an optic nerve crosses over. Each side (both optic tracts) now carries 50 percent of the message. This means both pretectal nuclei get the info even though only one eye was stimulated.

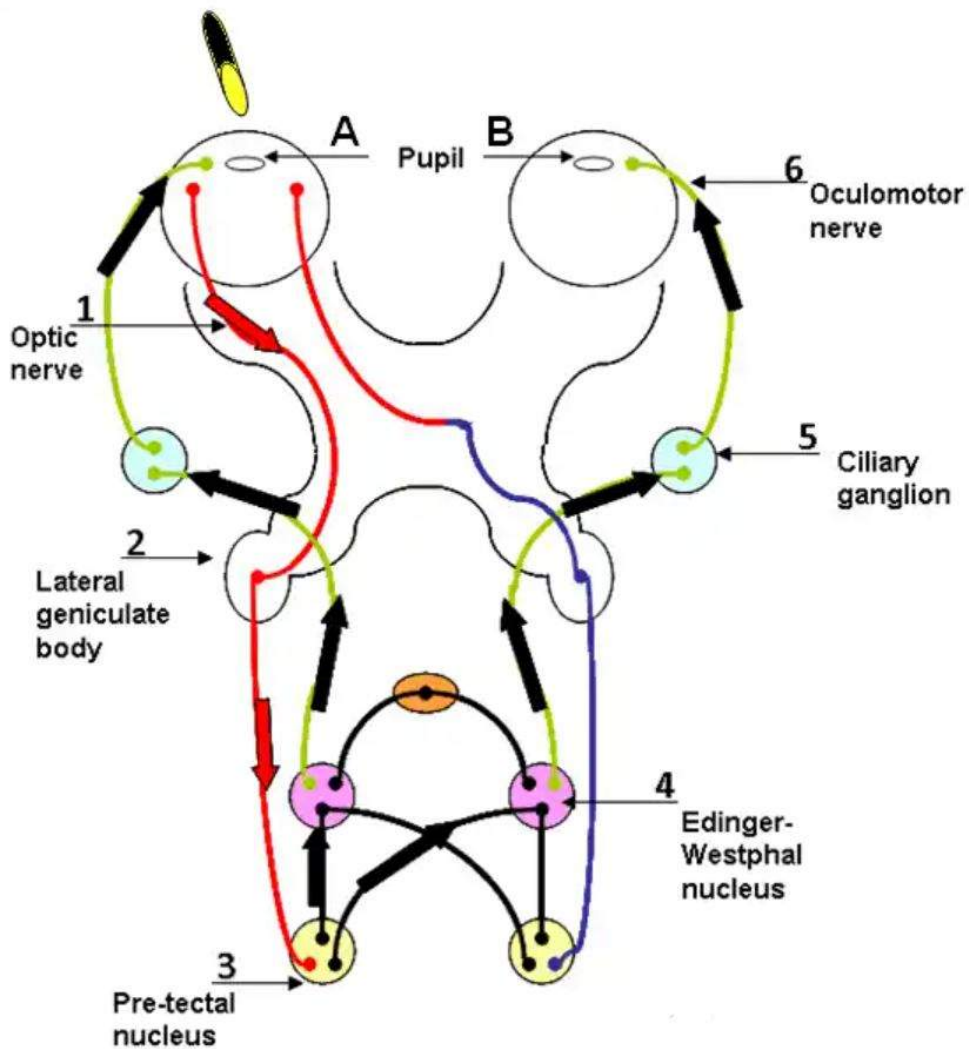
Remember, the afferent pupillary pathway doesn't go as far back in the brain as the visual pathway does. The following list is a quick refresher of the afferent pupillary pathway, going from anterior to posterior:

- Retina
- Optic nerve
- Optic chiasm
- Optic tract
- Pretectal nucleus
- Edinger-Westphal nucleus; also called the accessory third cranial nerve (CN III) nucleus



Afferent pathway (red line) / Efferent pathway (green line)





Afferent pathway (red line) / Efferent pathway (green line)

## Pupillary Pathway (Efferent)

Let's say the Edinger-Westphal nuclei have received a light message and are ready to tell the pupils whether they should get bigger, smaller, or stay the same. The brain needs to send a message out to the pupillary muscles. This message leaving the brain is an efferent or motor message (remember, efferent exits the brain).

Exiting Edinger-Westphal (accessory CN III), it begins the efferent, motor message by extending its axons to the actual CN III and exiting out on each side of the brain. CN III (the oculomotor nerve) goes forward

and synapses to the ciliary ganglion dendrite. Once the dendrite of the ciliary ganglion has received the efferent message, the ciliary ganglion axon extends forward to the iris sphincter muscle and innervates or relaxes it as appropriate; this changes the size of the pupil and regulates the amount of light that enters the eye.

This efferent pathway is separate from the afferent pathway. This is important to note and explains why there can still be pupillary reactions, even though the visual pathway is damaged.

If the afferent pathway gets damaged or disrupted, the efferent pathway won't be affected because it travels along a different path. More simply, severing the optic nerve (an afferent message carrier) of the right eye does not mean the right pupil will no longer show reaction. This is because the efferent message from the brain to the pupil does not go through the optic nerve. It travels a separate road. In this example, it's true you'll not receive a direct response from the right eye on pupillary testing, but you'll still see a consensual pupillary reaction and an accommodative pupillary reaction in the right eye. Pupil testing is covered more thoroughly later on and may help you see this concept more clearly.

Take a quick look at the following to review the structures making up the efferent pupillary pathway:

- CN III (has two axons extending out toward each eye)
- Ciliary ganglion (one on each side)
- Iris sphincter muscle (one in each eye).

The body is an intricate piece of work and the eye is no different. Understanding the structures involved with sight and pupillary action is helpful in understanding various eye problems and in explaining to your patients what is happening to them.

Almost anyone can plop a medical record in the doctor's door, but only a really skilled eye technician (you) can begin to understand the meaning of the various tests performed to check the afferent (sensory) and efferent (motor) pathways.

**Self-Test Questions. After you complete these questions pertaining to the visual-pupillary pathway, you may check your answers at the end of this module.**

1. What kind of pathway is the visual pathway?

Type your answer here

---

SUBMIT

2. What does the optic nerve consist of?

Type your answer here

---

SUBMIT

3. What fibers does the optic tract have?

Type your answer here

---

SUBMIT

4. Because the LGB passes on the visual messages from the optic tract to the optic radiations, to what is it often referred?

Type your answer here

---

SUBMIT

5. What is another name for the optic radiations?

Type your answer here

---

SUBMIT

6. What area of the brain contains the visual cortex?

Type your answer here

---

SUBMIT

7. The rods and cones make up which order neuron?

---

☐

Third

☐

First

☐

Second

SUBMIT

8. How many orders of neurons are in the visual pathway and where do the synapses occur?

Type your answer here

---

SUBMIT

9. Select item(s) that the neuron is(are) composed of?

---

☐

Dendrite

☐

Cell membrane

☐

Axon

☐

Cell body

☐

Nucleus

SUBMIT

10. Select the structures in the afferent pupillary pathway.

---

☐

Retina

☐

Optic nerve

☐

Nucleus

☐

Optic chiasm

☐

Optic tract

☐

Optic membrane

☐

Pretectal nucleus

☐

Edinger-Westphal nucleus (accessory CN III)

SUBMIT

11. What is an efferent message?

Type your answer here

SUBMIT


12. Name the three structures in the efferent pupillary pathway.

Type your answer here

SUBMIT



Complete the knowledge check questions before moving forward in the lesson.







# Ocular Physiology

In the last section you studied the anatomy of the human eye. In this section, you'll study the physiology of the eye. Physiology deals with a structure's function, capacities, and limitations.

Despite some limitations, the human eye is an extremely versatile optical instrument. It's capable of seeing in day and night, rapidly changing focus, distinguishing colors, and judging depth.

## Visual Acuity and Refractive Status of the Eye

You hear someone's vision described as 20/20 or 20/40. What does this mean and why do some people see better than others? Why do some people need glasses or contacts and others don't? These questions and more are answered in the next few lessons.

### Visual Acuity Definition

VA is defined as the eyes' ability to distinguish object details and shape. It's assessed by the smallest identifiable object seen at a specified distance (usually 20 feet for distance acuity and 16 inches for near acuity). Think of VA as a measure of the resolving power of the visual system. It's the ability of the visual system to receive light from images and transmit light to the retina, where it's converted to an electrochemical message, transmitted through the visual pathway, and then interpreted by the brain as a visual image.

VA is often confused with visual efficiency. Visual efficiency refers not necessarily to how well one sees, but rather how comfortably one sees. Individuals actually could have very good VA, even 20/20 vision, but experience difficulty in achieving this level of vision.

Many patients may be able to see the 20/20 line of your eye chart, but are reluctant to read it because they may not be seeing it with a great deal of visual efficiency. Some even refuse to read the actual line on the eye chart they can see, figuring if they see too well, their visual complaint won't be taken seriously. It may be wise to encourage your patients to read the smallest line they can, even if it's not as comfortable and clear as they would like. Reassure them the doctor will still work on helping them achieve better visual efficiency, even if their VA doesn't seem to indicate a problem. There may be refractive errors present that do not necessarily diminish VA, but may affect the patient's visual comfort.

## Factors Influencing Visual Acuity

Many factors influence VA, but the primary factors are the region of the retina stimulated, illumination, spectral quality of light, contrast, pupil size, time of exposure, patient's age, condition of the ocular media, presence of ametropias, and individual variations.

### Region of the Retina Stimulated —

The fovea centralis is the area where best vision (under photopic conditions) occurs. The fovea contains only cones, which produce the clearest images. VA progressively decreases the farther an image strikes the retina from the fovea. This is because the concentration of cones is greatest in the fovea and decreases toward the retina's periphery.

### Illumination —

Good illumination (photopic) conditions allow the visual system to use the cones in the fovea to process light stimuli. Dim light (mesopic) conditions force people to use a mixture of rods and cones to see adequately. This causes a loss of clarity, as rods do not provide images as sharp as cones.

When illumination is very poor (scotopic), the visual system becomes almost completely dependent on the rods for any vision. Rods, while very good at picking up visual images under low light conditions, do not produce very sharp and clear vision. Under scotopic conditions, vision is best when images are placed just outside the fovea. This allows a mixture of rods and cones to process what visual images can be seen.

It's interesting to note the greatest number of rods per area of retina exists just outside of the fovea. For example, a very dim star in the night sky may only be seen when you look slightly away from it. This allows the

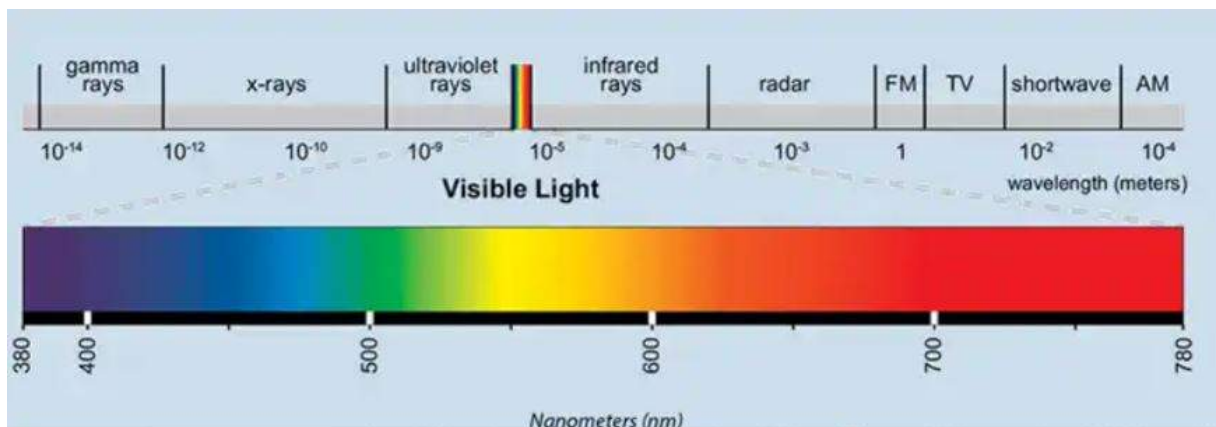
rods to pick up its image. If you look straight at it, it disappears, as the cones are not sensitive enough to process the minute amount of light coming from the galaxy far, far away.



## Spectral Quality of the Light

The spectral quality of light refers to its color or wavelength. The eye can generally see wavelengths between 400 and 750 nm. White light contains all the colors of the rainbow. Some lights are white, but have a reddish or bluish tinge to them. Look at the fluorescent lights in your building and you may notice this. Some of the lights will look different from others.

The clarity of vision can change due to variations in the spectral quality of the light seen. Some light has more blue in it, some has more red, and so on. This variation, though subtle, does have an effect on VA and efficiency. Some people are sensitive to fluorescent lighting, but do fine under incandescent lighting. This is most likely related to their sensitivity to changes in the spectral quality of the light.



## Contrast —

A black letter on a white background is easier to see than a black letter on a gray background. Assuming the same intensity of illumination, VA decreases as contrast decreases. Ever try to read an orange sign with yellow letters on it? It's tough because the contrast is poor.

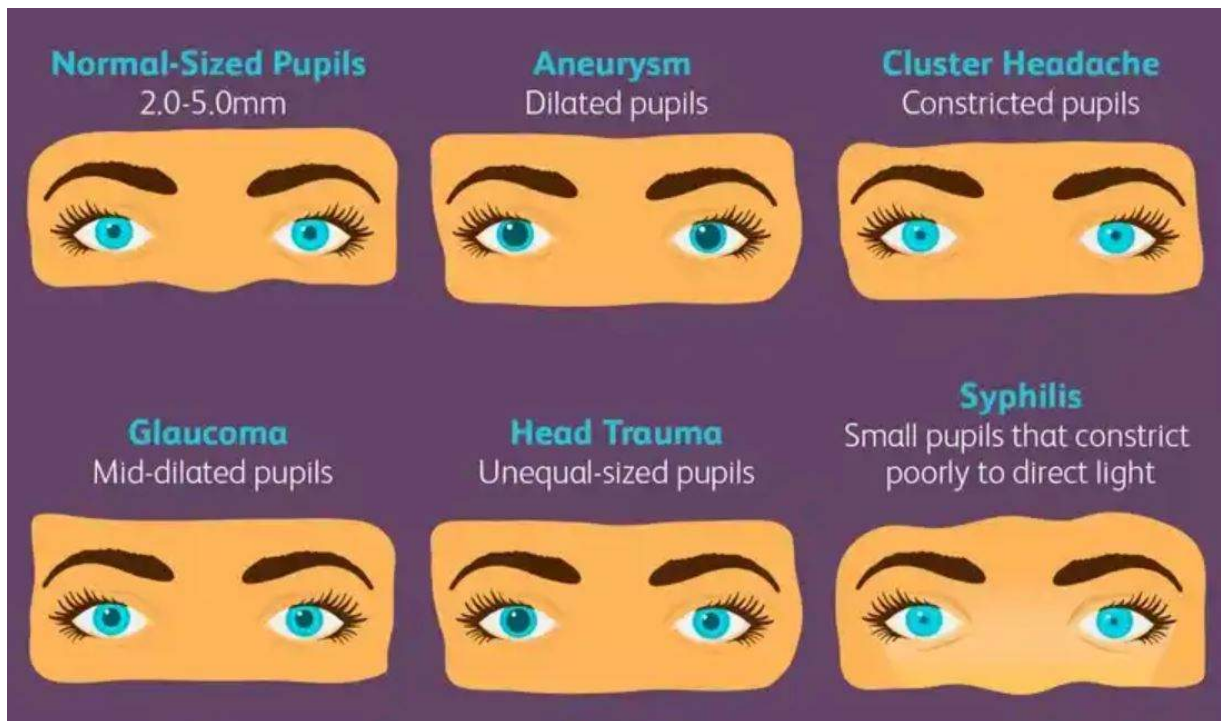
The two colors are close to each other on the visible spectrum. Now imagine an orange sign with violet letters. The contrast is much better as they are on opposite ends of the visible spectrum, so reading the sign is much easier.

## Pupil Size —

The eye produces aberrations similar to those found in spectacle lenses. When the pupils are dilated (large), the divergent peripheral light rays previously blocked by the iris are now entering the eye and creating a focusing dilemma for the optics of the eye. Aberrations occur, blurring the image the brain receives and reducing VA. A blurred image triggers the brain to signal the eyes to accommodate (focus). One effect of the accommodative response is for the pupils to constrict.

The constricted pupils only allow light rays going relatively straight to enter the eye. This reduces the number of deviant light rays striking the retina, so VA is improved. When you perform the pinhole test, you are using this principle. The pupil's main job is to regulate the amount of light entering the eye. If it allows too much light in, the photoreceptors (rods and cones) are washed out by light and a poor image is sent to the visual cortex of the brain.

If the pupil is too small and not enough light gets in, the cones in the fovea are not adequately stimulated and the visual cortex must rely on stimulus sent by the less precise rods, again reducing VA.



## Time of Exposure —

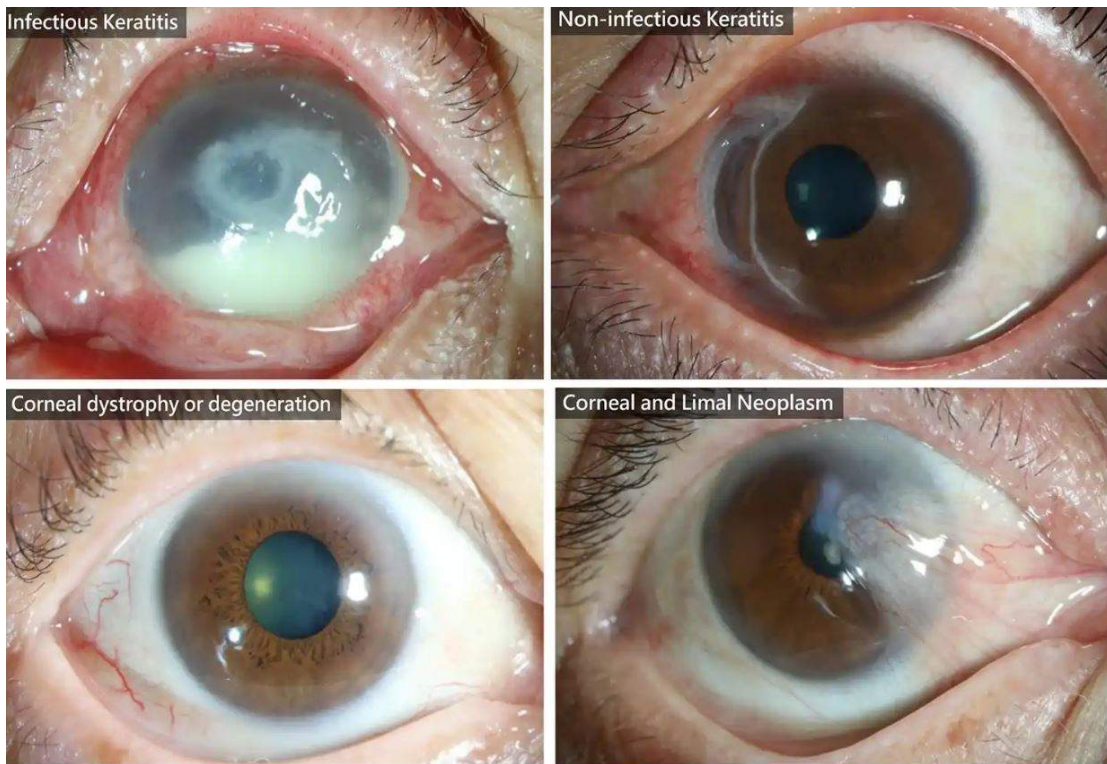
If a person is given a long time to analyze an object, more details are assessed as more rods and cones are stimulated for a longer period of time. The result is usually good VA. If the time of exposure is short, there is less information sent to the brain for analysis, so the VA is generally poorer.

## Age —

When you were born, your vision was at the 20/400 level. Your VA got progressively better as you developed. As you continue to age, time and ultraviolet (UV) light take its toll on the cornea, crystalline lens, and retina, causing VA to diminish. VA is generally clearest between the ages of 15 and 20.

## Condition of the Ocular Media —

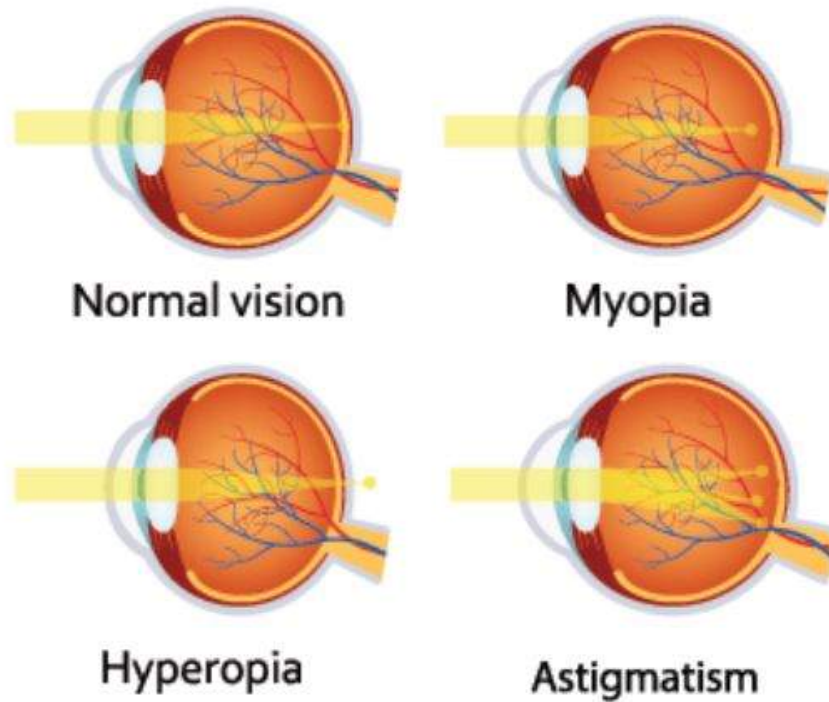
Any abnormality of the ocular media (cornea, aqueous humor, crystalline lens, or vitreous humor) tends to reduce VA. Corneal scars, cells and flares in the aqueous, cataracts, and neo-vascularization in the vitreous are just a few examples of the many conditions degrading one's ocular media.



### Presence of Ametropias (Correctable Refractive Errors) —

Any refractive condition preventing light rays from focusing clearly on the fovea reduces VA. Ametropia is a refractive error (e.g., hyperopia, myopia, and astigmatism). If these refractive errors are not corrected, VA decreases, or at the minimum, visual efficiency suffers.





### Individual Variations

People are different. Some people just have better vision for a variety of reasons (e.g., genetics, visual stimulus experienced as a child, personality type, etc.). Not all people see the same, even with all other factors being equal. This is due to individual variations. It's apparent there are many factors involved with the physiology of VA.

When you study the measuring of VA in module 4, you'll learn how the sizes and shapes of the vision chart letters (objects, etc.) determine the levels of VA (e.g., 20/20, 20/400, etc.). For now, it's important to look at one of the biggest factors in the physiology of VA—ametropias or refractive problems of the eyes.

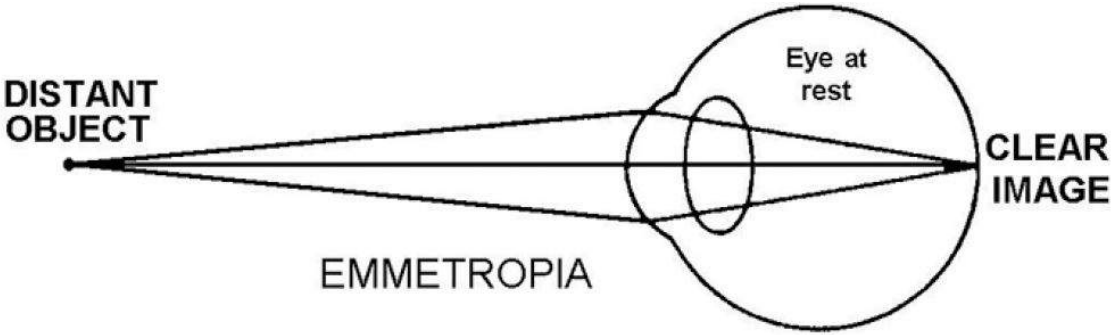


Complete the content above before moving on.

## Refractive Status of the Eye

One of the factors affecting VA is the presence of ametropias, which are errors in the eye’s ability to focus light on the retina when the eye is at rest. Ametropias result in refractive errors corrected by glasses or contact lenses (CL). If a person’s eye is healthy, and glasses or CLs still cannot correct the vision, the person is considered to have amblyopia.

The major refractive errors are hyperopia, myopia, and astigmatism. A person with good vision and no refractive error is considered to be an emmetrope or have emmetropia. Let’s take a look at what it means physiologically to be an emmetrope and then touch on the ametropias.

EMMETROPIA (NORMAL)	HYPEROPIA (FARSIGHTED)	FACULTATIVE HYPEROPIA	ABSOLUTE HYPEROPIA	(NEAR)
<p>Emmetropia is a refractive condition in which no refractive error is present when the eye is at rest. Light rays from distant images are focused perfectly on the retina without the need for accommodation or corrective lenses.</p> <p>So, an emmetropic patient could look at a distant object and see it clearly without his or her eyes needing to accommodate. With the eyes at rest, the light rays from distant objects focus perfectly on the retina, resulting in a clear image (see image below.). This is the desired state.</p> <p>The emmetrope still needs to accommodate to see near objects, but only a normal amount. This focusing does not cause undue eyestrain. Remember it this way: winning an Emmy is good, so being an Emme- is good. Emmetropes do not generally need glasses or CLs until they get to about 40–45 years of age, and they, like everyone else, experience presbyopia (discussed later).</p>  <p>The diagram illustrates the optical system of an emmetropic eye. On the left, a point labeled 'DISTANT OBJECT' emits two light rays that travel horizontally towards the right. These rays enter an eye, which is depicted as a circle. Inside the eye, the rays pass through a biconvex lens. The word 'EMMETROPIA' is written below the eye. The rays converge at a point on the back surface of the eye, labeled 'CLEAR IMAGE'. The text 'Eye at rest' is positioned above the lens, indicating that no accommodation is required for distant vision.</p>				



To spark creativity, feed your brain material like you're cramming for a tough test. Then stop thinking about the problem you want to solve. Go surfing or take a leisurely walk. Research shows that letting your mind wander fosters creativity.

It's also found that meditation helps you spot and solve problems in creative ways. It promotes divergent thinking that gets novel ideas flowing. According to these studies, meditation also makes you more open to considering new solutions. Time to breathe.

The average axial length of an adult eye is about 23 mm. Some people have hyperopia because, in essence, their eye is too short (i.e., less than 23 mm long). As a rule of thumb, each mm of axial length amounts to about 3.00D of refractive power. Using this rule (and ignoring a multitude of other variables affecting refractive error), a person with an eye length of 22 mm theoretically has about +3.00D of hyperopia.

Think about it. If the eye is too short, the optics of the eye (when resting) do not have enough refractive power to focus the light rays from a distant object onto the retina. Instead, the light rays come to a (theoretical) focus beyond the retina. Of course, the brain doesn't like the blurred image it receives, so it tells the eye to increase its focusing power, bringing the light rays to a focus sooner. The eye can do this if the hyperopia is not too excessive. The down side is a hyperope's eye never gets to rest. It must accommodate to see distant objects and it really must accommodate even more to see near objects because they require even more refractive power.

This explains why hyperopes tend to complain of eye fatigue, especially after reading. Assume a person has hyperopia, but the length of the eye is the magically correct, 23 mm in length. What else could keep the light rays from focusing on the retina? Another cause of hyperopia might be the curvature of the cornea or crystalline lens. One of them may have too flat of a curvature (i.e., having too long a radius of curvature). This equates in less refractive power, and thus, the light rays focus beyond the retina. Let's look at an example to explain this concept.

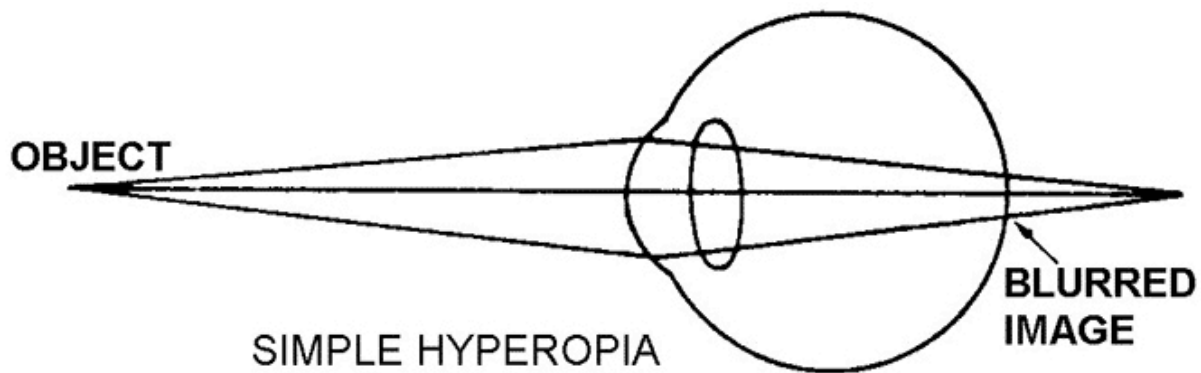
For the sake of this example, we'll focus on just the cornea to illustrate this concept. The average adult cornea has a radius of curvature of 7.5 mm. This radius of curvature has a direct effect on the refractive power of the cornea. If the cornea is fairly flat (has a long radius of curvature [i.e., more than 7.5 mm]), it has less refractive power. If the cornea is steeply curved (has a short radius of curvature [i.e., less than 7.5 mm]), it has more refractive power. So, a person who is experiencing hyperopia due to a problem with the radius of curvature of their cornea or crystalline lens is likely to have a radius of curvature more than 7.5 mm long. A difference in the radius of curvature of just 1 mm equates to a 7.00D effect on refractive power.

Say a cornea has a radius of curvature of 8.5 mm instead of the normal 7.5 mm. This lengthening of the radius of curvature by 1 mm means the cornea is flatter than normal and has 7.00D less refractive power. This means a person needs a +7.00D lens to make up for this lost power. You can see it doesn't take a lot of variation from normal to end up with significant refractive errors. A cornea with a longer radius of curvature is flatter and lacks the refractive power needed to bring light rays from a distant object to a nice sharp focus on the retina (assuming the eye is at rest).

Many older folks experience a hyperopic shift as they age due to a flattening of the crystalline lens. Usually this shift is less than +0.75D and is not a big problem, but it does occur. Surface curvatures of the refractive

surfaces of the eye play a significant role in ametropias. Once again, in the real world of vision, the brain doesn't like receiving a blurry image, so it tells the eye to accommodate (focus) to fix it. The eye responds and can make the image clear and sharp, but it must accommodate when it really should be at rest. This is why the person is said to be hyperopic.

They cannot see clearly in the distance without using some accommodative power. This means their eyes work all the time, but even more so to see near objects clearly. Knowing the two primary factors leading to hyperopia is good. Now you need to think about hyperopia in terms of severity and how people really react to it. The severity of hyperopia can be classified into two basic categories—facultative and absolute.



EMMETROPIA (NORMAL)	HYPEROPIA (FARSIGHTED)	FACULTATIVE HYPEROPIA	ABSOLUTE HYPEROPIA	(NEAR)

Facultative hyperopes are people who can accommodate (focus) enough to bring the light entering the eye to a sharp focus on the retina. Since facultative hyperopes can fix their ametropia using accommodation of the crystalline lens, they may have good VA when tested. So what's the problem? None, if the hyperope is comfortable and not experiencing eye strain from all the extra accommodation they are doing. Remember, ideally, the eye should be able to see a distant object clearly without needing to accommodate.

Facultative hyperopes must accommodate to see things in the distance; the key is they can fix their ametropia and manage to see clearly (in the distance) without spectacles or CLs. Symptoms tipping you off a patient has facultative hyperopia are complaints of eye fatigue or blurriness toward the end of the day, or their eyes fatigue quickly while reading. Of course, the eyes are tired; they are working twice as hard to see objects up close. A look at the physiology of accommodation may explain why a facultative hyperope's eyes tire quickly when reading. Accommodation of the eyes causes three things to happen:

1. The ciliary body constricts, loosening the tension on the Zonules of Zinn attached to the crystalline lens. The lens, no longer held in a flat shape, grows thicker and develops a more curved surface, giving it

more refractive power.

2. The pupils constrict, limiting the admission of peripheral and stray light.
3. The eyes converge.

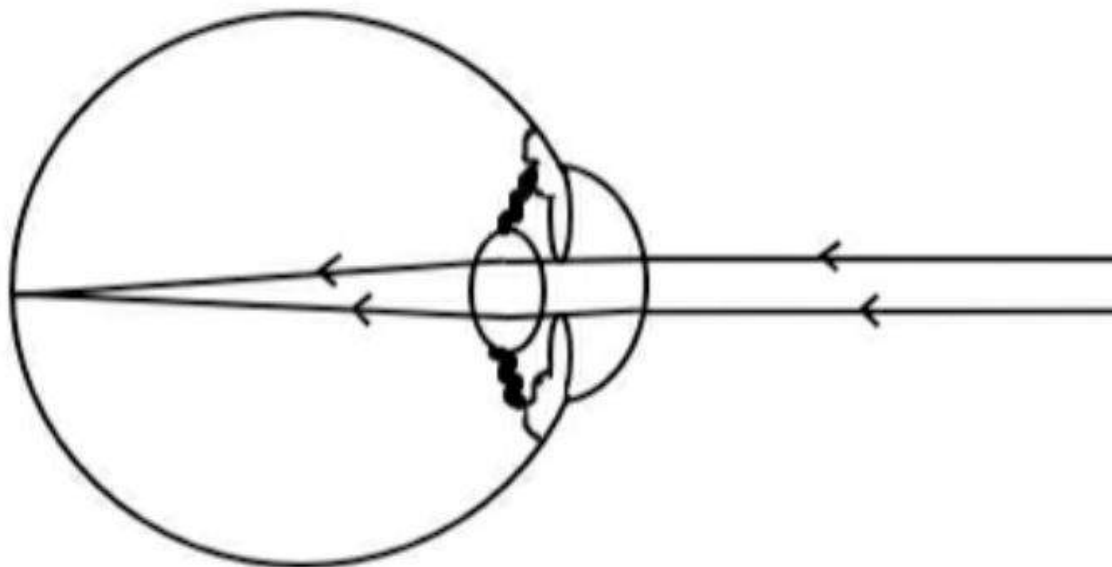
All three things happen when your eyes accommodate, whether you want all three things to happen or not. The occurrence of these three things works out perfectly for someone who is emmetropic (has no refractive error) and is looking at something near to him or her. The person's eyes need more refractive power for near objects, so the eyes automatically going through these three things to accommodate, is a good thing. The constriction of the pupils limits the stray light rays, helping to sharpen the clarity, and the eyes need to converge to maintain alignment when looking at near objects anyway.

Accommodation for an emmetrope is no big deal as they only need to do it to look at near objects, and all the things occurring with accommodation are actually beneficial to a person trying to focus in on a nearby object. Now think about the facultative hyperope. Are the eyes at rest when looking at distant objects or must they accommodate? If you said accommodate, you are correct. So what's the big deal? The increase in refractive power of the crystalline lens is required for seeing objects in the distance clearly. Generally, this is not too much of a problem; however, the ciliary body must work its muscles to allow the crystalline lens to change shape to provide this extra refractive power. This can get tiring over time.

How about the pupils getting smaller? Pupillary constriction while looking at a distant object is not such a big deal, except there is some muscular effort needed by the iris sphincter muscle to constrict the pupils. Again, this can get tiring over time. How about the convergence of the eyes? If the facultative hyperope is trying to look at a distant object, the eyes really should remain parallel to each other to keep the object centered in the fovea of each eye. Convergence is not desirable; it just happens when the eyes accommodate.

When undesired convergence occurs, the lateral recti (plural of rectus) muscles must work to counteract the convergence performed by the medial recti muscles. When you combine this conflicting muscle action with the muscle action occurring in the ciliary body and iris sphincter, you can see the facultative hyperope must do a lot of work to see clearly in the distance. Now, when the person must read something up close, the eyes need to work even harder to keep the brain happy with the image it's getting. No wonder facultative hyperopes complain of eye fatigue! So what's the answer for a facultative hyperope? For some, their hyperopia is just too mild to bother treating. They are usually asymptomatic, and the doctors tend to leave them alone.

For those facultative hyperopes who do have complaints and want some help, the doctor can do a cycloplegic refraction and find out what their true refractive error is. Once this is determined, a set of glasses with the appropriate plus (+) lenses can be prescribed. The plus lenses eliminate most of the need for accommodation, allowing the eyes to relax more. Often, facultative hyperopes are merely prescribed glasses for reading, since this is when their condition is most aggravated. It all depends on the person, taking into account their age, occupation, and desires. Just try to bear in mind, facultative hyperopes may have VAs of 20/20 in the distance and near upon testing, or they may show just a slight decrease in near VA. This is a case where VA may seem to indicate a person is fine, but the patient's visual efficiency may be telling the real story.



EMMETROPIA (NORMAL)	HYPEROPIA (FARSIGHTED)	FACULTATIVE HYPEROPIA	ABSOLUTE HYPEROPIA	(NEAR)
------------------------	---------------------------	--------------------------	-----------------------	--------

Absolute hyperopes are absolutely hyperopic. They cannot accommodate away the problem. These patients are so hyperopic, even though they try to focus their eyes, they just do not have the accommodative power to bring the light entering the eyes to a sharp focus. Testing the VA on these patients generally shows some decreased distant vision and even worse near vision. These patients must have corrective lenses to see clearly. The doctor does a cycloplegic refraction to determine the true degree of hyperopia before prescribing lenses. Once the total amount of hyperopia is determined, the doctor can make an educated decision on what prescription the patient needs. This statement may sound a little odd, so let's explain.

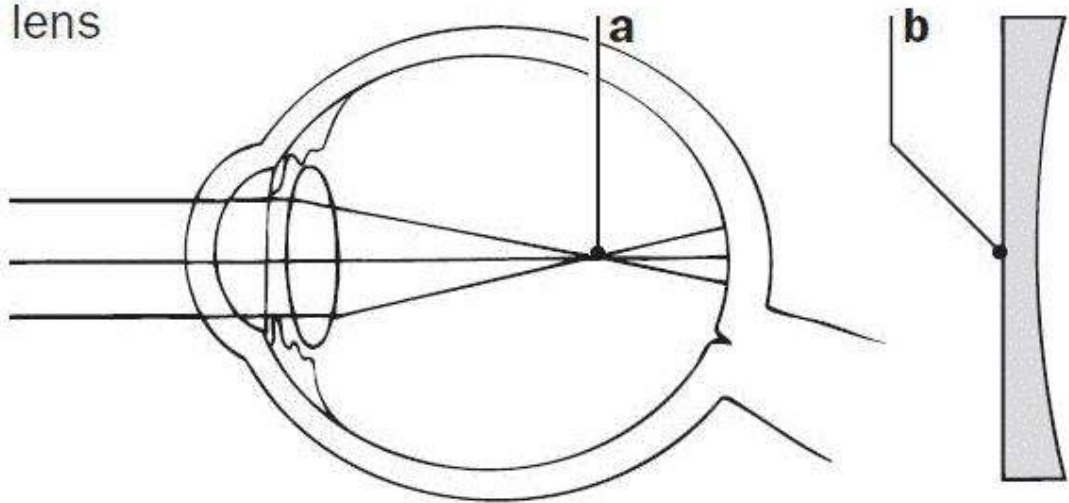
After the cycloplegic refraction, the doctor may find (just as an example) a patient has +5.00D of uncorrected hyperopia. This is considered an objective measurement as the doctor just measured and found a certain amount of refractive error. He did not ask if the patient wanted or liked the +5.00D lenses used to identify the amount of refractive error. If asked, the patient may have said he or she didn't like it. This would be his or her subjective opinion. Since patients are the ones wearing the glasses, it's important to find out what they want or feel comfortable wearing.

Subjectively, a patient may not feel comfortable having his or her full refractive error corrected. He or she may only feel comfortable with +4.00D worth of correction, leaving +1.00 uncorrected to give his or her eyes a little leeway to focus some on their own. So, the doctor will only give the patient +4.00D lenses. If the doctor tried to force the entire amount of correction on the patient, the patient would not be happy and would not

wear the glasses. The patient’s VA may be good with them, but his or her visual efficiency or comfort would not.

Think of it this way--this absolute hyperope patient has spent a lifetime focusing (or at least trying to); if the doctor eliminates all the refractive error with glasses, the patient’s eyes wouldn’t need to do any work. While this may sound great, the patient hates it. It’s unnatural for the patient. They have always accommodated, and they still need to accommodate some to feel comfortable. The doctor understands this and wisely leaves the patient under corrected. Strange, isn’t it? A final note--hyperopia of any type (facultative or absolute) is corrected using plus (+) lenses.

**Hyperopic eye**  
**a** light rays focusing  
behind the retina  
**b** corrective convex  
lens



EMMETROPIA (NORMAL)	HYPEROPIA (FARSIGHTED)	FACULTATIVE HYPEROPIA	ABSOLUTE HYPEROPIA	(NEAR)

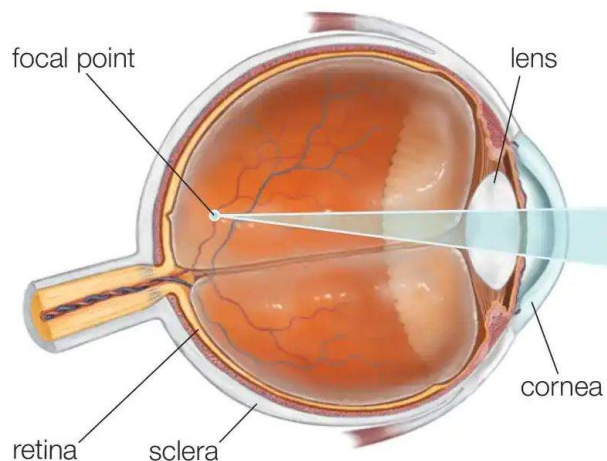
Simple myopia (SM) is often referred to as nearsightedness, because myopes generally see things near them the clearest. For a myope, the distant objects are blurry. Myopia is defined as an overpowered eye in which parallel light rays from distant objects are brought to focus in front of the retina. So, with the eye at rest, and looking at a distant object, the light rays come to a focus before reaching the retina. Look at figure 1-22. By the time the light rays get to the retina, they have already come to a focal point and are now diverging, causing blurry vision. Myopia, like hyperopia, can be attributed to an axial or curvature problem.

When myopia is due to an axial problem, it means the eye is too long. Remember, the average adult eye has an axial length of approximately 23 mm. In an eye with myopia due to excessive axial length, the eye is more than 23 mm long. If an eye is too long, the distant light rays entering are refracted the appropriate amount, but end up focusing before the retina since the retina is farther back than normal. If the myopia is not due to the length of the eye, then the radius of curvature of the cornea or crystalline lens is probably the cause. A short radius of curvature makes for a steeper curve on the cornea or lens, leading to greater refractive power. Greater refraction of light results in the distant light rays coming to a focus before reaching the retina. Recall the normal radius of curvature for the average adult cornea is 7.5 mm.

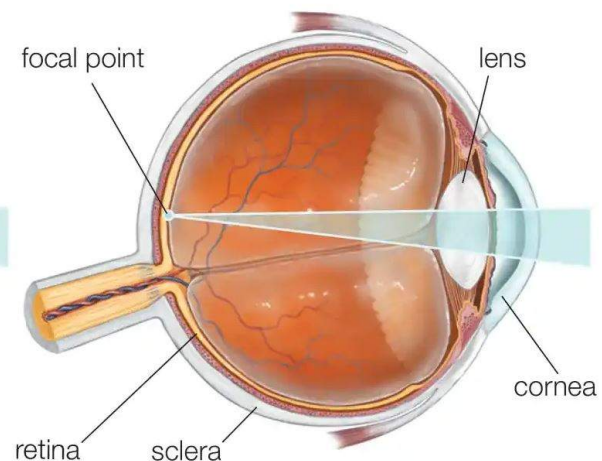
In myopia caused by excessive corneal curvature, the radius of curvature of the cornea is less than 7.5 mm long. This results in a steeply curved cornea with more refractive power than is needed. Also recall for every mm change in the radius of curvature of the cornea, there is a 7.00D change in refractive error. So, if a person has a normal length eye, but a cornea with a 6.5 mm radius of curvature, you can expect this person to be about -7.00D myopic, requiring a -7.00D lens to see clearly. In some cases, myopia can be caused by an increase in thickness or density of the crystalline lens. This is usually the case when a diabetic patient complains of visual fluctuations. Their blood sugar levels are probably out of control, causing the crystalline lens to swell with the fluctuations. When the lens swells, it gets thicker in the middle and gets a shorter radius of curvature (i.e., gets a steeper curved surface.)

This increases the refractive power of the lens, which causes myopic shifts in the patient's vision. A patient can also have myopic shifts if he or she is using certain medications. Patients on the glaucoma drug Pilocarpine experience an increase in accommodation because the Pilocarpine stimulates the ciliary body. This causes the ciliary innervation and loosens its tension on the Zonules of Zinn, allowing the crystalline lens to thicken in the middle and become more rounded. As a result, the increased refractive power in the lens leads to a myopic condition because light rays are now focused much too soon.

### Myopia (nearsightedness)



### Normal eye





Complete the content above before moving on.

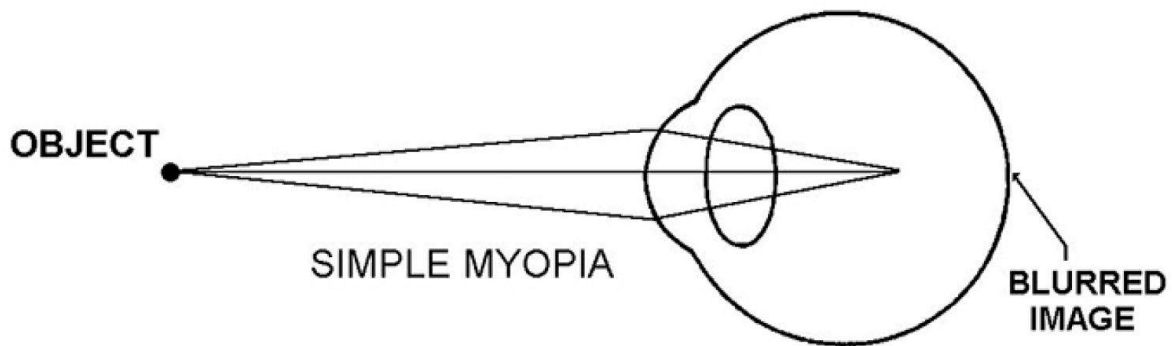


Figure 1-22. Diagram of light rays in a myopic eye.

## Myopia (Nearsightedness)

Simple myopia (SM) is often referred to as nearsightedness, because myopes generally see things near them the clearest. For a myope, the distant objects are blurry.

Myopia is defined as an overpowered eye in which parallel light rays from distant objects are brought to focus in front of the retina. So, with the eye at rest, and looking at a distant object, the light rays come to a focus before reaching the retina.

Look at figure 1-22. By the time the light rays get to the retina, they have already come to a focal point and are now diverging, causing blurry vision. Myopia, like hyperopia, can be attributed to an axial or curvature problem.

When myopia is due to an axial problem, it means the eye is too long. Remember, the average adult eye has an axial length of approximately 23 mm. In an eye with myopia due to excessive axial length, the eye is more than 23 mm long. If an eye is too long, the distant light rays entering are refracted the appropriate amount, but end up focusing before the retina since the retina is farther back than normal.

If the myopia is not due to the length of the eye, then the radius of curvature of the cornea or crystalline lens is probably the cause. A short radius of curvature makes for a steeper curve on the cornea or lens, leading to greater refractive power. Greater refraction of light results in the distant light rays coming to a

focus before reaching the retina. Recall the normal radius of curvature for the average adult cornea is 7.5 mm.

In myopia caused by excessive corneal curvature, the radius of curvature of the cornea is less than 7.5 mm long. This results in a steeply curved cornea with more refractive power than is needed. Also recall for every mm change in the radius of curvature of the cornea, there is a 7.00D change in refractive error. So, if a person has a normal length eye, but a cornea with a 6.5 mm radius of curvature, you can expect this person to be about -7.00D myopic, requiring a -7.00D lens to see clearly.

In some cases, myopia can be caused by an increase in thickness or density of the crystalline lens. This is usually the case when a diabetic patient complains of visual fluctuations. Their blood sugar levels are probably out of control, causing the crystalline lens to swell with the fluctuations. When the lens swells, it gets thicker in the middle and gets a shorter radius of curvature (i.e., gets a steeper curved surface.) This increases the refractive power of the lens, which causes myopic shifts in the patient's vision.

A patient can also have myopic shifts if he or she is using certain medications. Patients on the glaucoma drug Pilocarpine experience an increase in accommodation because the Pilocarpine stimulates the ciliary body. This causes the ciliary innervation and loosens its tension on the Zonules of Zinn, allowing the crystalline lens to thicken in the middle and become more rounded. As a result, the increased refractive power in the lens leads to a myopic condition because light rays are now focused much too soon.

Patients developing cataracts often experience a myopic shift because the cataracts thicken the lens and the density of the lens, giving it slightly more curvature and a greater index of refraction, both of which increase the refractive power of the lens in its relaxed state.

Pregnancy often causes myopic fluctuations in vision due to hormonal changes. The hormones affect the crystalline lens and degree of accommodation. As long as a woman is still pregnant or breast feeding, the hormone levels are high and an accurate refraction may not be possible. It's best to wait until the pregnancy is over or the mother has stopped breastfeeding before trying to determine the need for a prescription. Waiting isn't always possible though, so just be aware this is one category of patient who may never be completely satisfied with the corrective lenses prescribed. At least not until her body chemistry has returned to a more stable state.



Unlike facultative hyperopia, myopia cannot be corrected through accommodation by the patient. You may ask why not? Well remember, the myopic eye is focusing the light rays too much in its relaxed state. Any accommodation by the eye simply worsens the condition and results in the light rays coming to a focus even farther in front of the retina, making things worse.

For a myope to see clearly in the distance, he or she needs minus (-) lenses. Minus lenses actually diverge light about to enter the eye, compensating for the eyes overfocusing of the light. A good way to remember what kind of lenses nearsighted people need is to think myopes need minus. An example of a simple myopic prescription is -1.00 sphere (SPH).

The positive side of myopia is there is no big strain on the eyes while reading as they are already focused for near-sighted work. Imagine a person who is a -2.50D myope. This means the eyes naturally focus at 16". Anything beyond 16" begins to blur. At 16" the person is very comfortable, can see clearly, and the eyes do not need to accommodate. If the person brings material in closer than 16", he or she can still see it clearly, but the eyes must do some accommodating.

If a person has a moderate degree of myopia, glasses are, of course, required for distant vision and may become necessary for near vision as well. The amount of myopia considered moderate is subjective, but realistically anyone with a prescription (Rx) of -3.50D or more, needs glasses for distance and near vision.

Focal length is a key reason a person with moderate myopia needs glasses for near vision. Let's say we have a patient named Bob who is a -3.50D myope. Bob's eye has a natural focal length of 11.4" without glasses. This means his eyes, without glasses, can see clearly at 11.4" and closer. For Bob to see at the standard reading distance of 16", he needs corrective lenses. Yes, Bob is myopic, but he is so myopic, the range of focus (11.4" or less) is not very useful in the real world. It's true Bob's near vision is not as poor as his distant vision, but he surely notices an improvement in his near VA if he wears his glasses all the time.

What about a person with high myopia? High myopia is usually considered anything more than - 6.00D. A - 6.25D myope has a focal length, without glasses, of 6.4" and closer. This patient needs full-time corrective lenses for distant and near vision. Think of the patient as an absolute myope (though you won't find this term in the eye dictionary). The person absolutely needs corrective lenses, regardless of the distance the patient wants to see.

Checking the vision of a moderate myope generally shows poor distance vision and good near vision. High myopes have really poor distant vision and some decreased near vision, but the relationship is the same; distant vision is very poor and near vision is good, or at least better than the distant vision. Common complaints by new or current myopes who need an Rx update are decreased night vision and an inability to see distant road signs while driving.

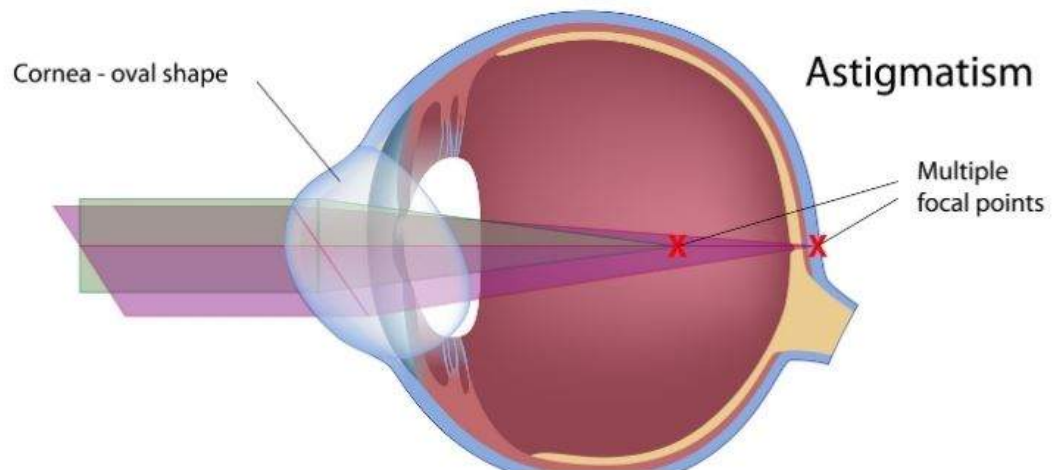
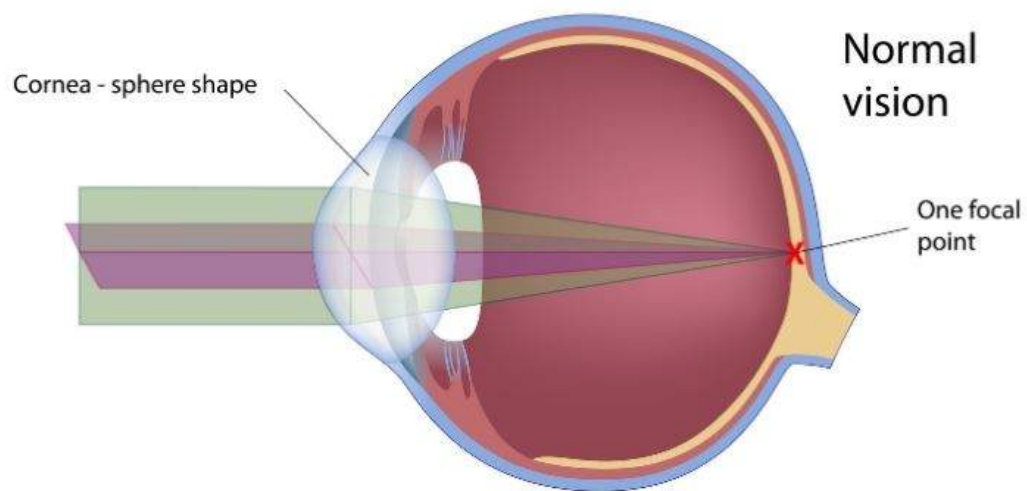
## Astigmatism

Astigmatism is probably one of the most misunderstood ametropias. Patients often tell you they have stigmatism or stigma, or tell you they have astigmatism. Some actually have a grave look on their face, as if they have some really rare and serious eye condition. Astigmatism is simply a blurring in one meridian of an eye. It can be a mild blurring rarely even noticeable or it can be severe, as in people with keratoconus. Astigmatism is usually correctable with glasses or contacts.

Astigmatism is defined as an optical defect in which refractive power is not uniform in all meridians of the eye. This means the light entering the eye is not coming to the desirable single point of focus on the retina. Instead, one meridian of the eye is refracting light more than the meridian 90° away. This causes the light rays entering the eye to focus at different distances from each other, so, instead of coming to a point of focus, the separate meridians each form a line focus, resulting in two separate line foci forming 90° apart. The brain interprets these two lines of focus as distortion and blurriness.

A person who has astigmatism generally has decreased distance and near VA. This is because the eye is distorting the light rays entering it, regardless of whether the light rays are from a near or a distant object. Astigmatism is classified as simple, compound, or mixed.

Simple astigmatism occurs when one meridian of the eye focuses the light rays correctly on the retina, while the meridian 90° away focuses the light rays too soon or too late. If the light rays are focused too soon, it's called simple myopic astigmatism (SMA). If the light rays are focused too late, it's called simple hyperopic astigmatism (SHA).



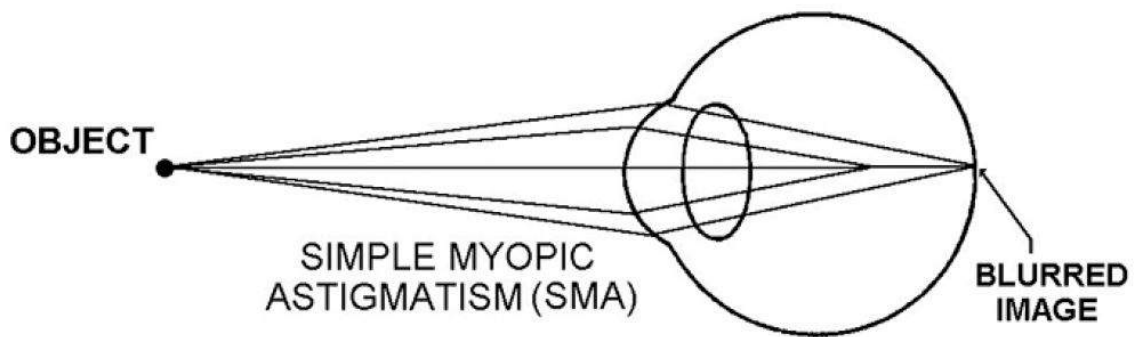


Figure 1–23. Diagram of light rays in a simple myopic astigmatic eye.

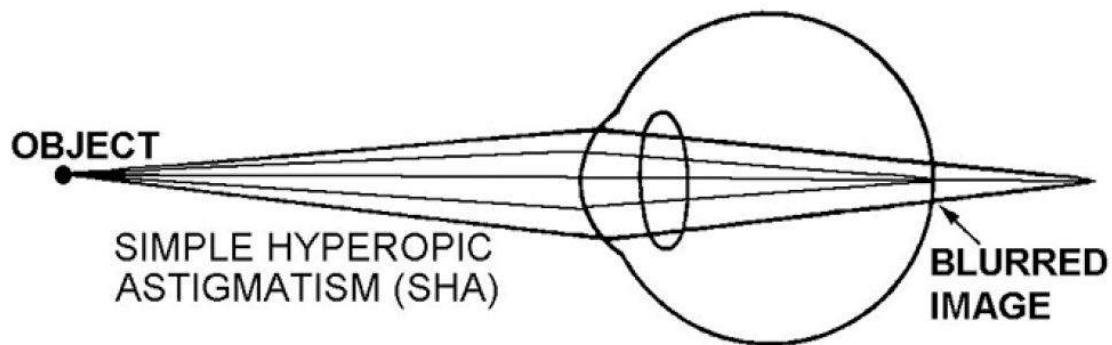


Figure 1–24. Diagram of light rays in a simple hyperopic astigmatic eye.

## Astigmatism

Simple astigmatism is simple because one meridian of the eye is correctly focusing the light. It's only the meridian 90° away focusing the light too soon or too late.

A prescription for someone with SMA looks something like PL  $-1.00 \times 045$  (if written in plus cylinder form  $-1.00 +1.00 \times 135$ ).

A prescription for a person with SHA looks something like  $+1.00 -1.00 \times 075$  (if written in plus cylinder form PL  $+1.00 \times 165$ ). If you put these Rx on an optical cross, you can easily see one meridian has plano (PL), or zero power, and the meridian 90° away has minus (for SMA) or plus (for SHA) power. This makes it simple to see what kind of prescription you have.

Compound astigmatism occurs when the focal lines from each of the two main meridians focus in front of the retina (compound myopic astigmatism [CMA]) or behind the retina (compound hyperopic astigmatism [CHA]).

## Astigmatism

It's a compound problem because none of the light rays are being focused on the retina. The two-line foci are both focusing before the retina (CMA) or beyond the retina (CHA). None of the light rays are focusing on the retina, which compounds the blurriness and distortion of vision. Though irritating and not desirable, CMA and CHA can be corrected with lenses. An example of a CMA prescription is  $-2.00 -1.00 \times 030$  (in plus cylinder form, it is  $-3.00 +1.00 \times 120$ ). An example of a CHA prescription is  $+2.50 -1.50 \times 056$  (in plus cylinder form, it's  $+1.00 +1.50 \times 146$ ).

If you put these prescriptions on an optical cross, you see with a CMA Rx one meridian is minus power and the meridian  $90^\circ$  away is even more or less minus power. If it's a CHA Rx, one meridian is plus power and the other is more or less plus power. A person with a compound astigmatism is farsighted or nearsighted, but then he or she has a distortion in his or her eyes causing one meridian to be even more farsighted or nearsighted. The person's visual problems are compounded.

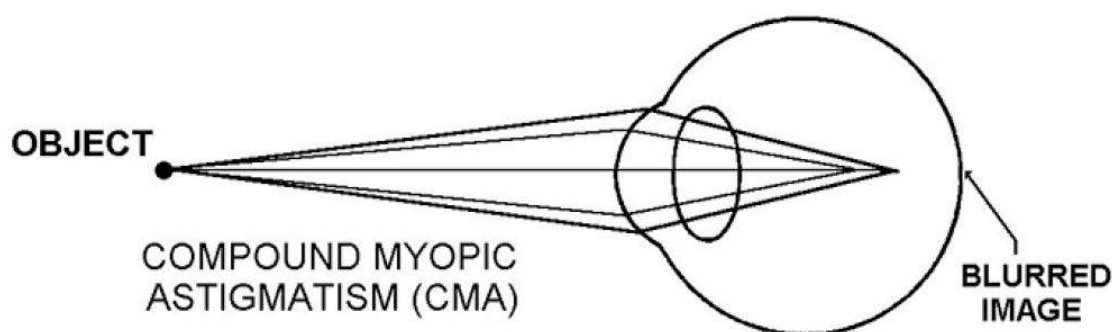


Figure 1–25. Diagram of light rays in a compound myopic astigmatic eye.

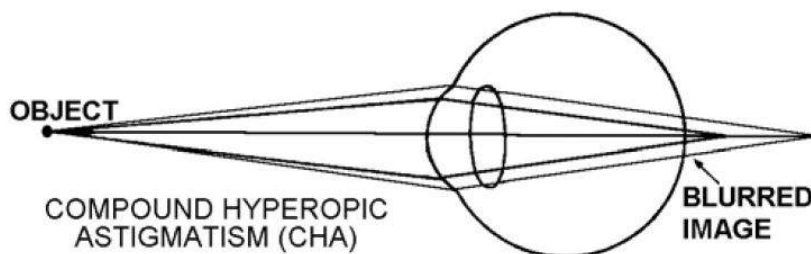


Figure 1–26. Diagram of light ray in a compound hyperopic astigmatic eye.

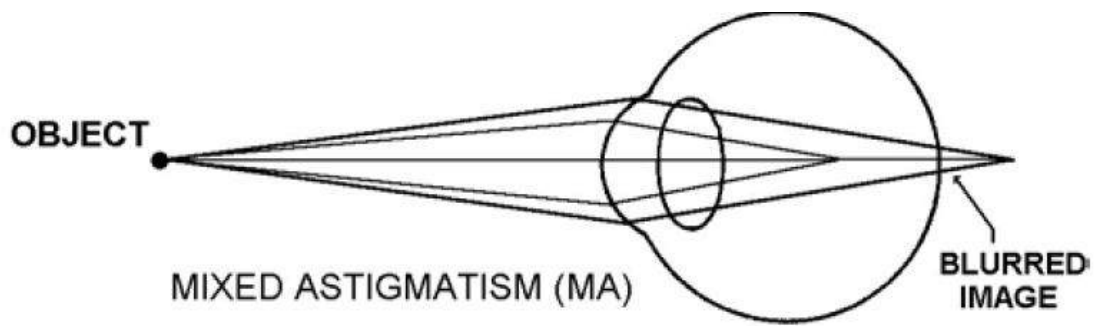


Figure 1-27. Diagram of light rays in a mixed astigmatic eye.

Mixed astigmatism (MA) (fig. 1-27) occurs when one meridian of the eye focuses the light rays too soon (i.e., in front of the retina), and the meridian 90° away focuses the light rays too late (behind the retina). In essence, one meridian of the eye is myopic, and the meridian 90° away is hyperopic. The refractive state of the eye is all mixed up, hence, MA.

An example of an MA Rx is  $+1.50 -2.00 \times 085$  (in plus cylinder form, it is  $-0.50 + 2.00 \times 175$ ). If you diagram an MA Rx on an optical cross, you see one meridian has plus power and the meridian 90° away has minus power.

#### NOTE:

Astigmats (people with astigmatism) normally see things in their own blurry way, so when their condition is first identified and corrected with lenses, they may not like the look of their new world. It may take a little while for their brains to reprogram mentally for what they now see.

To lessen the shock on these people who are getting their astigmatism corrected for the first time, the doctor may only give them part of the total amount of astigmatic correction needed (i.e., if a person who has never worn corrective lenses before is found to need  $-2.00D$  of cylinder (astigmatism) correction, the doctor may only prescribe  $-1.00D$  initially).

This is to break the person in slowly to the actual prescription. Once the person adjusts to this amount of correction, the doctor gives the remaining amount in a following prescription. You can tell very easily if a person has astigmatism--their glasses have a cylinder power. The axis of the prescription tells where the cylinder power is needed to correct the blurriness in their vision.

The following table gives a quick breakdown of the basic ametropias and an example of the prescription correcting each.

Ametropias and Correcting Prescription		
Condition	Rx Example in Minus Cylinder Form	Rx Example in Plus Cylinder Form
SM	-3.25 SPH	-3.25 SPH
SH	+3.25 SPH	+3.25 SPH
SMA	PL -1.25 × 029	-1.25 +1.25 × 119
SHA	+3.00 -3.00 × 100	PL +3.00 × 010
CMA	-1.00 -2.00 × 045	-3.00 +2.00 × 135
CHA	+4.75 -1.00 × 086	+3.75 +1.00 × 176
MA	+2.50 -3.50 × 140	-1.00 +3.50 × 050

## Relationship Between Ametropias and Patient Complaints

The relationship of ametropias to patient complaints is not always as consistent as those we've discussed. Patient complaints are very individualistic. Some patients with higher degrees of ametropia have the least complaints because they are accustomed to blurred vision. Conversely, many patients with very low degrees of ametropia have the most severe complaints, probably because they know what it is to see very well, and any change is very noticeable to them.

In general terms, hyperopes complain of eyestrain with near work, headaches after reading, or tired eyes. Myopes often complain of decreased distant visual acuity (DVA), decreased night vision, or needing to squint to see objects. Astigmats complain of blurred vision at near and in the distance, fluctuations in vision, and headaches at times.

All the ametropias discussed are correctable with glasses or CLs. If a person has decreased vision not correctable with lenses, the person has a condition called amblyopia, or an infection or injury preventing them from experiencing good vision. Remember: "A-metropia is A-refractive error."

Range Of Accommodation Based On Age		
Age	Closest Range the Eyes can Focus (without Rx)	Useable Accommodative Power of the Crystalline Lens (in Diopters)
10	14 cm (5½")	+7.00
20	18 cm (7")	+5.50
30	25 cm (10")	+4.00
40	44 cm (17½")	+2.25
45	57 cm (23")	+1.75
50	80 cm (32")	+1.25
55	115 cm (46")	+0.87
60	200 cm (80" in)	+0.50
65	270 cm (108")	+0.37
70	833 cm (333")	+0.12
75	Infinity	0.00

## Presbyopia and Accommodation

Presbyopia is not an ametropia. It's a condition of age, not a refractive error. As we get older, our ability to accommodate decreases. Most theorists agree infants have an extremely high amplitude of accommodation. Accurate measurements have shown the average amplitude of accommodation of a 10-year-old is about +14.00D. At age 70, the amplitude has dropped to +0.12D.

When a person reaches an age where his or her eyes can no longer accommodate enough to see near objects clearly, this person has become presbyopic, or more commonly referred to as a presbyope. Usually, presbyopia becomes noticeable around age 40. The correction for presbyopia involves replacing the lost accommodative power of the eye with plus lenses for near work (e.g., reading glasses or bifocals).

The following table shows the age, closest range of accommodation a person's age has (measured in centimeters and inches), and the usable accommodative power of the patient. The key word is usable, as some books may show this information, but they often list total accommodative power. The fact is, people can only utilize 50 percent of the total accommodative power available; therefore, the table has been converted to reflect usable accommodative power.

Look at the 40-year-old patient using the above table. This person can only come up with +2.25D of power. To read something at 16", a person needs +2.50D of power. So you can see when this 40-year-old is trying to read at the standard 16", the eye strains slightly because, even after the eye accommodates as much as it can (+2.25 at age 40), the image is still slightly blurry. The person needs another +0.25D of focusing



power to clear the image at 16", but the eyes can't do it. This is the reason the he or she starts holding things farther away. The person needs less accommodative power to see an object farther away. According to the table, our 40-year-old starts to see pretty good once the reading material is out to about 17 1/2".

It's a fact people need less accommodative power to see things farther away. People who are losing their accommodative ability (presbyopia) start moving their reading material farther away, which proves this principle. This works for a while, but soon their arms get "too short." You've probably heard that complaint once or twice by now from some of your maturing patients.

The fix is reading glasses, or bifocals if they're already wearing spectacles to correct their distance vision. The following table shows the decrease in accommodative ability of our mature patients and approximately how much dioptric power their reading glasses need to allow them to see clearly at 16". This assumes they are emmetropic of course.

Decrease In Accommodative Ability and Dioptric Power		
Age	Useable Accommodative Power	Approximate Spectacle Rx Needed to see Clearly at 16"
45	+1.75	+0.75
50	+1.25	+1.25
55	+0.87	+1.75

Decrease In Accommodative Ability and Dioptric Power		
Age	Useable Accommodative Power	Approximate Spectacle Rx Needed to see Clearly at 16"
60	+0.50	+2.00
65	+0.37	+2.25
70	+0.12	+2.50

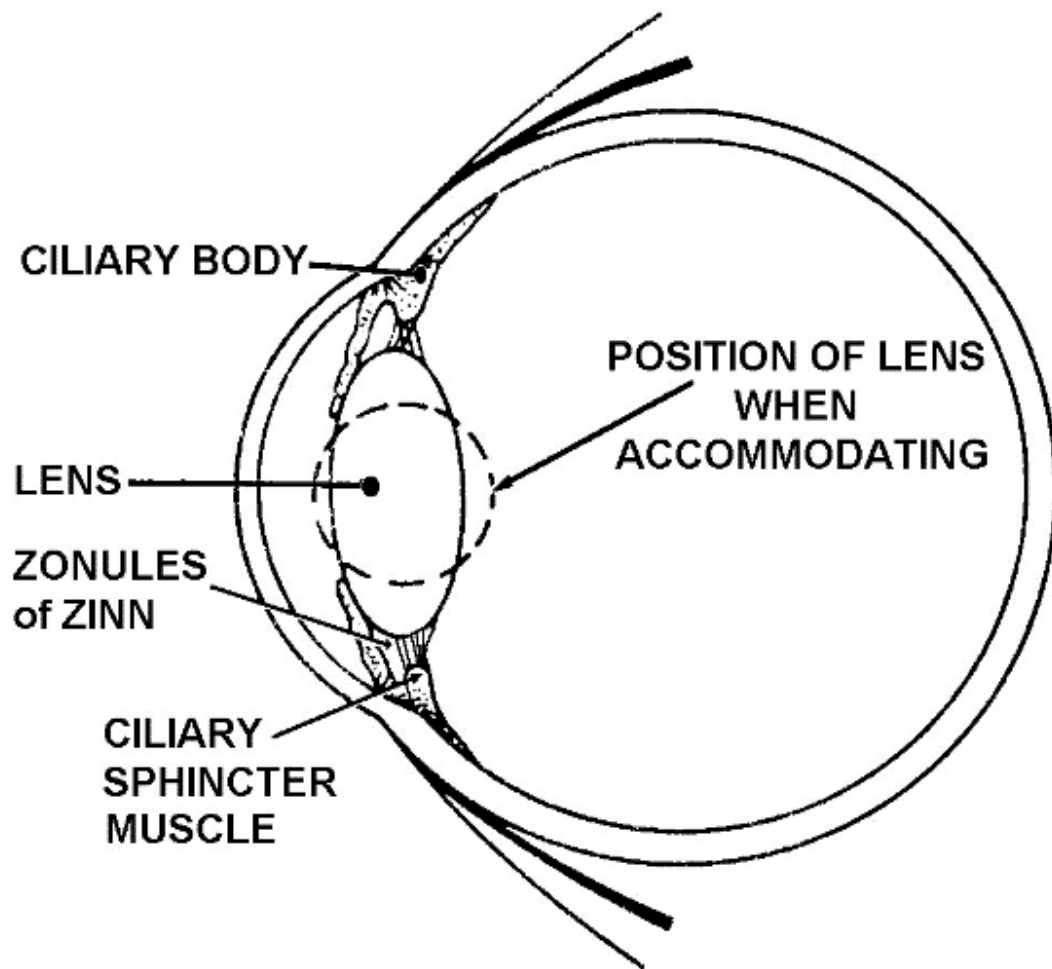


Figure 1-28. Figure 1-28. Crystalline lens action.

If you live 40 years or longer, presbyopia is going to occur. Presbyopes experience difficulty seeing near objects. This is caused by a loss of accommodative power because the crystalline lens is losing elasticity. It cannot change shape (fatten in the middle and get more curvature) enough to focus the divergent light rays coming off near objects (fig. 1-28).

Presbyopia is a near-vision problem. Although patients may have been emmetropic all their life, he or she will still experience presbyopia, but their distant vision will remain unaffected.

There is one category of ametropia causing a person to experience decreased distant vision as a result of presbyopia. The facultative hyperope manages to see well in the distance without glasses because their eyes accommodate to correct for the hyperopia. As the facultative hyperope loses accommodative ability,

his or her near vision decreases as presbyopia sets in (as it does with everyone), only he or she tends to notice the problem sooner in life than the emmetrope or myope.

As more time passes and more accommodative ability is lost, the facultative hyperope may no longer be able to accommodate enough to see distant objects clearly anymore either. These are the folks usually complaining their reading glasses ruined their eyes.

Facultative hyperopes seem to complain the most when presbyopia strikes them. Unfortunately, there is nothing you can say to make them any happier about the situation, but educating them on their condition may relieve some of their anxiety.

Just remember the decline in accommodative amplitude (power) is associated with age. Presbyopia advances regardless of whether or not a patient wears glasses.

**Self-Test Questions. After you complete these questions pertaining to visual acuity and refractive status of the eye, you may check your answers at the end of this module.**

1. Define VA and describe how it is assessed.

Type your answer here

SUBMIT

2. What does visual efficiency refer to?

Type your answer here

---

SUBMIT

3. Name the 10 factors that influence VA.

Type your answer here

---

SUBMIT

4. What is the nm range of the electromagnetic spectrum the eye can generally see as light?

Type your answer here

---

SUBMIT

5. What is the VA of a newborn?

Type your answer here

---

SUBMIT

6. What is ametropia?

Type your answer here

---

SUBMIT

7. What happens to light rays that enter an emmetropic eye?

Type your answer here

---

SUBMIT

8. What two problems can cause hyperopia?

Type your answer here

---

SUBMIT

9. What does a facultative hyperope do naturally to correct for their ametropia?

Type your answer here

---

SUBMIT

10. What is a facultative hyperope likely to complain of?

Type your answer here

---

SUBMIT

11. What kind of vision does an absolute hyperope have in the distance and at near?

Type your answer here

---

SUBMIT

12. Where do the light rays focus in the eye of a myope?

Type your answer here

---

SUBMIT

13. What types of lenses do myopes need?

Type your answer here

---

SUBMIT

14. What is considered to be high myopia?

Type your answer here

---

SUBMIT

15. Define astigmatism.

Type your answer here

---



SUBMIT

16. What is simple astigmatism?

Type your answer here

SUBMIT

17. What does CMA and CHA stand for?

Type your answer here

SUBMIT

18. What kind of Rx is  $-2.00 -4.00 \times 001$  an example of?

Type your answer here

---

SUBMIT

19. What does the mixed astigmatic eye do with light rays?

Type your answer here

---

SUBMIT

20. What does the axis of the Rx tell you?

Type your answer here

---

SUBMIT

21. What do myopes complain of?

Type your answer here

---

SUBMIT

22. Are ametropias correctable with CLs?

---

☐

Yes

☐

No

SUBMIT

23. What is presbyopia?

Type your answer here

---

SUBMIT

24. When does presbyopia usually become noticeable?

Type your answer here

---

SUBMIT

25. What kind of glasses does a presbyope need?

Type your answer here

---

SUBMIT

26. How much usable accommodation does a 70-year-old person have?

---

☐ +0.15D

☐ -0.10D

☐ +0.25D

☐ +0.12D

SUBMIT

27. How much refractive power does a 70-year old person need to see clearly at 16"?

---

☐ -2.00D

☐ -1.25DD

☐ +2.50D

☐ +2.00D

SUBMIT

28. What does an uncorrected presbyope usually do with reading material?

Type your answer here

---

SUBMIT

29. Can a person avoid presbyopia?

Type your answer here

---

SUBMIT

30. Does presbyopia affect distant vision?

☐

Yes


☐

No

SUBMIT



Complete the knowledge check questions before moving forward in the lesson.



## Depth Perception, Color, and Night Vision

### Depth Perception, Color, and Night Vision

Now we'll discuss how the eye works in regards to depth perception, color vision, and night vision. Make sure you pay close attention to these lessons as they are the foundation for more advanced testing procedures still to be covered.

### Depth Perception

In flying, driving, and many other performance functions relying on visual cues, the ability to perceive depth is critical. An individual can determine the relative distance of objects by using a total of six visual cues. Five of the cues are monocular, meaning only one eye is needed to use these cues. The monocular cues are magnification (relative size), confluence of parallel lines to a point (perspective), interposition of shadows (overlay), blue-gray mistiness of objects at a great distance (distant haze), and parallax.

There is one binocular cue, and this is our primary and greatest cue to depth perception—stereopsis. Before we get into stereopsis, you'll first explore each secondary monocular cue to depth perception.

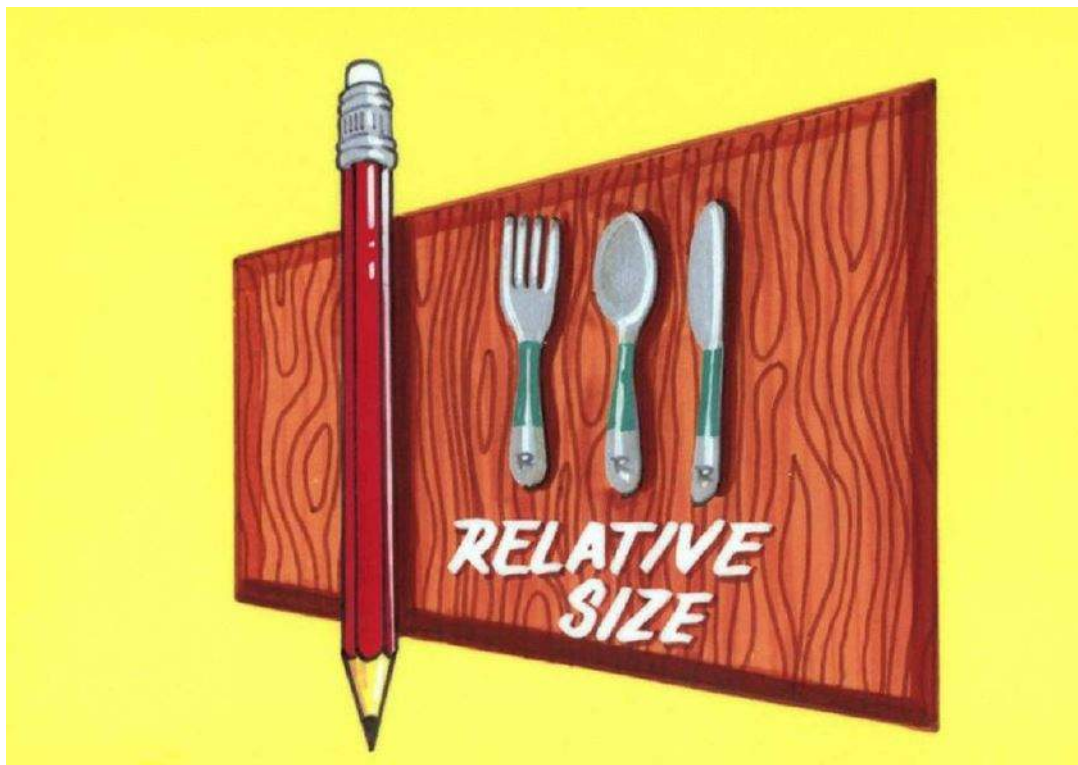
Everyone uses monocular cues, but they are most important to a monocular (one-eyed) patient because they are the only cues these patients can use to gauge depth. Monocular cues never give the same fine, detailed, and accurate depth perception a binocular patient experiences, but they allow some functional ability in judging depth.

The five monocular cues are:

1. MAGNIFICATION	2. CONFLUENCE	3. INTERPOSITION OF SHADOWS	4. BLUE-GRAY MISTINESS OF OBJ...	5.



Magnification (relative size) – Relatively speaking, the larger an object appears, the closer it must be (fig. 1–29).



1. MAGNIFICATION

2. CONFLUENCE

3. INTERPOSITION  
OF SHADOWS

4. BLUE-GRAY  
MISTINESS OF  
OBJ...

5.

Confluence of parallel lines to a point (perspective) – Two-dimensional drawings and photographs give the illusion of depth by proper use of perspective (e.g., railroad tracks converging toward the horizon or walls converging towards the end of a room [fig. 1–30]).



1. MAGNIFICATION

2. CONFLUENCE

3. INTERPOSITION  
OF SHADOWS

4. BLUE-GRAY  
MISTINESS OF  
OBJ...

5.

Interposition of shadows (overlay) – If an object overlaps another object, the overlapping object is closer (fig. 1-31).



1. MAGNIFICATION

2. CONFLUENCE

3. INTERPOSITION  
OF SHADOWS

4. BLUE-GRAY  
MISTINESS OF  
OBJ...

5.

Blue-gray mistiness of objects at a great distance (distant haze) – An object located in the distance loses clarity due to dust, moisture, heat waves, and so forth. This haziness is used as a cue to an object's relative distance (fig. 1–32).



**1. MAGNIFICATION**

**2. CONFLUENCE**

**3. INTERPOSITION  
OF SHADOWS**

**4. BLUE-GRAY  
MISTINESS OF  
OBJ...**

**5.**

Parallax -When two objects situated at different points in space are aligned, and the head of the observer is moved in one direction, the nearer object appears to move in the opposite direction (fig. 1-33). Parallax can also be defined as a relative change in position of objects with movement of an observer. Imagine driving down the road.

You look out the window at the beautiful trees. As you drive along looking at the trees, they appear to be moving; however, we know the trees are not moving--you are. This is an example of relative change in position of objects with movement of the observer. The objects appear to move, when in reality, the observer is actually moving.





Complete the content above before moving on.

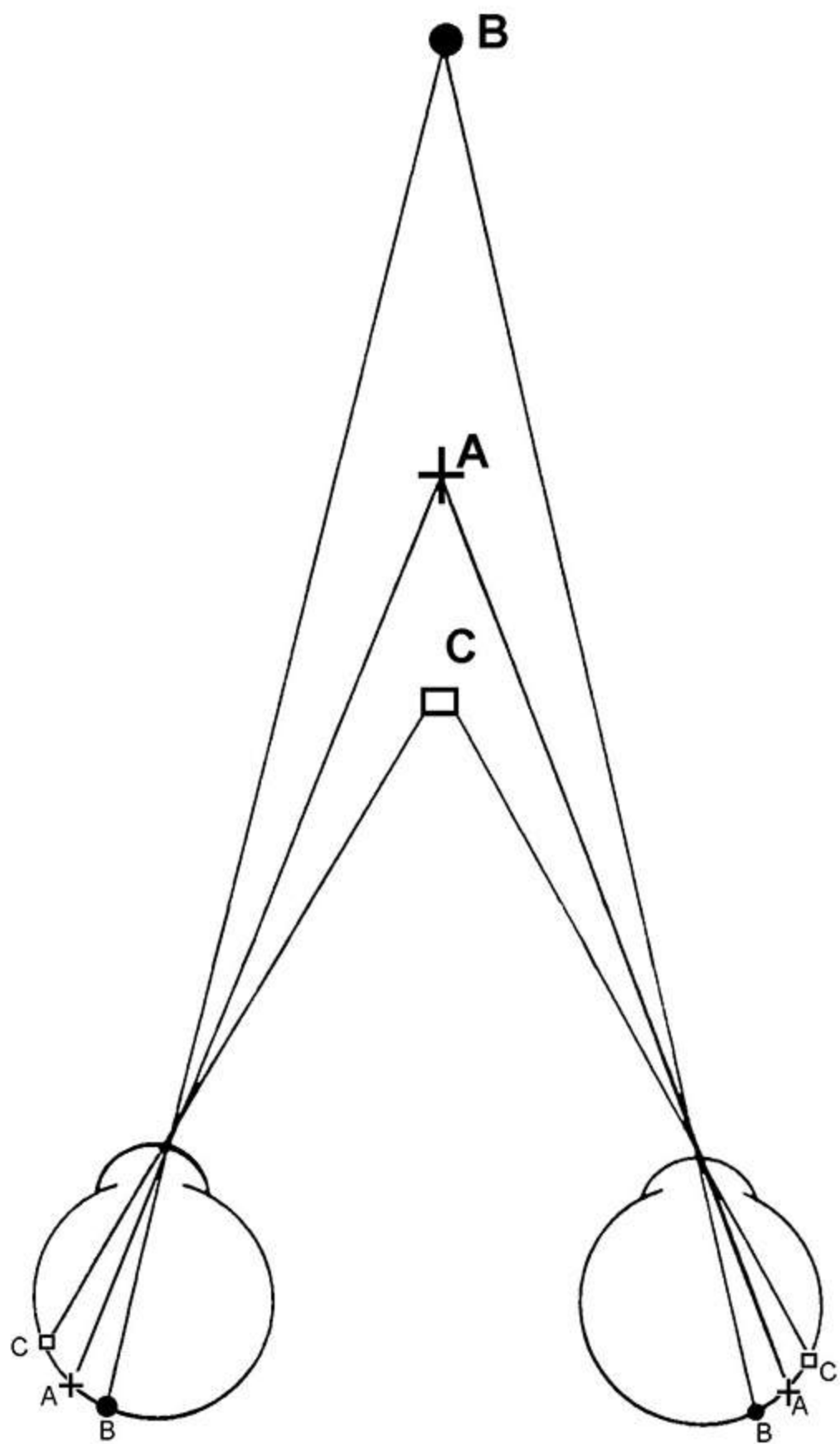


Figure 1–34. Retinal image displacement that leads to stereopsis.

---

To experience really fine and accurate depth perception at medium to near distances, a person needs two eyes (binocularity), working together in proper alignment, with good VA. Only under these conditions can a person be in a position to experience the primary cue to depth--stereopsis.

Stereopsis is achieved because the eyes are separated by approximately 60–70 mm (think pupillary distance). When the light from an object enters the eye and is focused on the retina, there is an ever so slight difference of placement of the image in each eye. Look at figure 1–34.

Based on the location of the image on each retina, the amount of convergence of the eyes to line up on the object, and the amount of accommodation (fig. 1–35) required by the eyes to focus on the object, the brain can process depth to a high degree of accuracy.

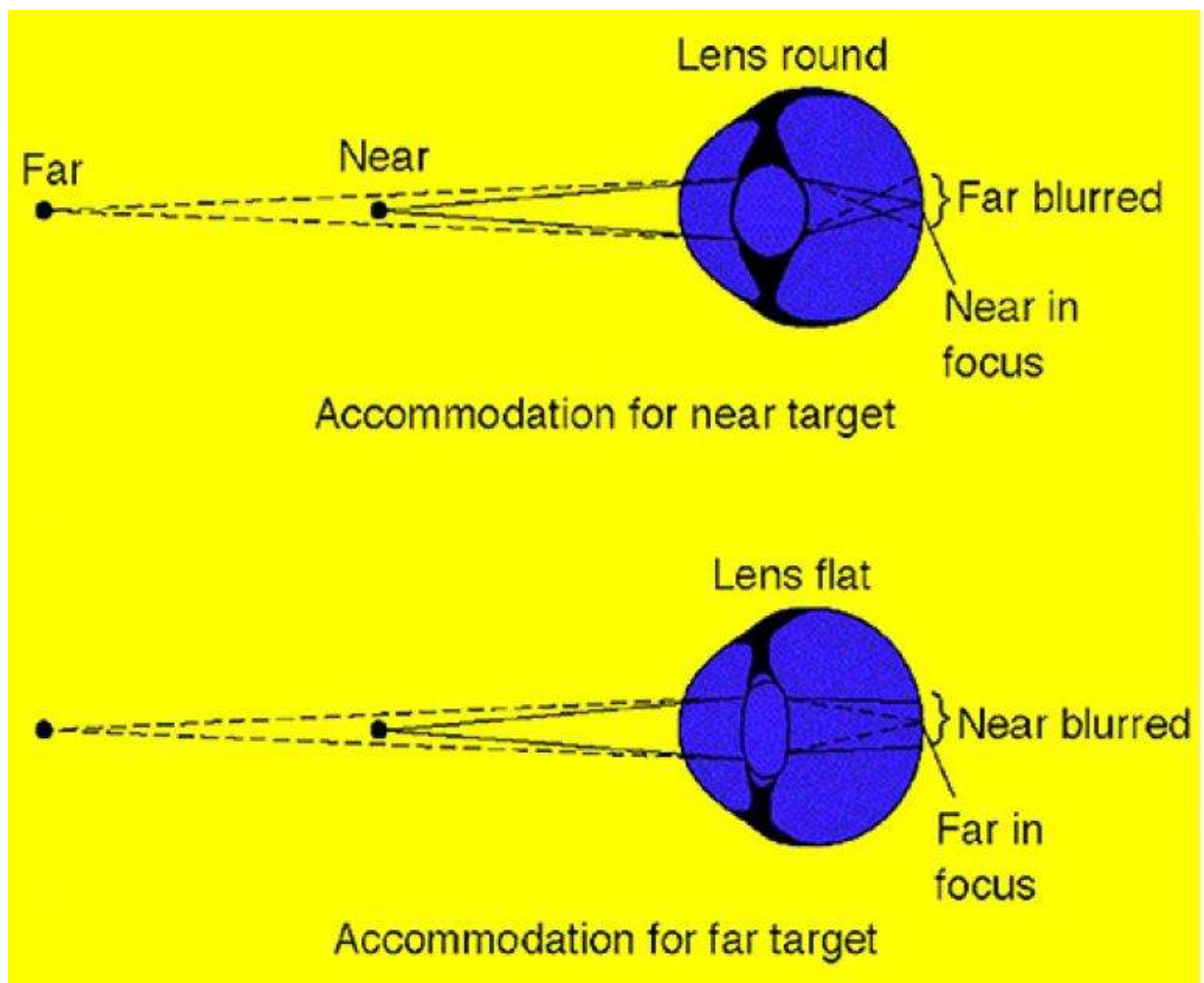


Figure 1-35. Accommodation.



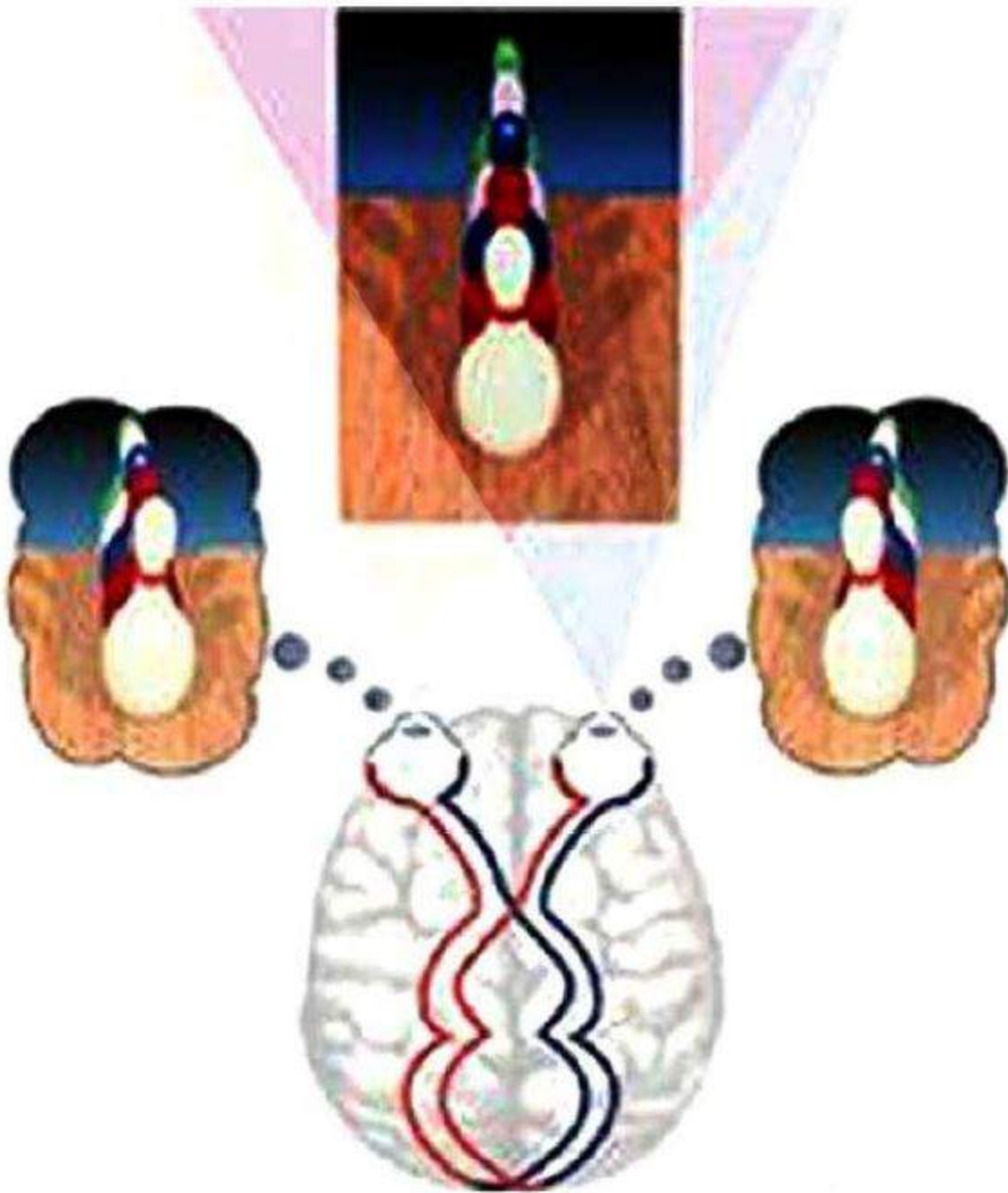


Figure 1-36. Stereopsis.

### Stereoscopic Depth Perception

It is measured in seconds of arc. Think about  $1^\circ$  of axis in a pair of glasses. It's not very much, is it? Now, imagine there are 60 minutes (') of arc in each degree. Each minute of arc must be extremely small,

considering how slight  $1^\circ$  is. Now, go one step further. Each minute of arc has 60 seconds (") in it.

That means  $1^\circ = 60'$  and  $1' = 60''$ . Therefore,  $1^\circ = 3,600''$ . This should give you an idea how small a unit of measurement a second of arc really is.

What's amazing is the human eye has been able to distinguish a separation between objects of as little as  $5'$  of arc.

Remember, everyone with at least one eye can have some degree of depth perception, but only people who can use both eyes together can have stereopsis (fig. 1–36). Patients with suppression, amblyopia, tropias, or other eye problems limiting them to only one functional eye use monocular cues.

Would a patient with a constant unilateral right exotropia have depth perception? Yes, but only to a gross degree because the person's depth perception would need to rely on monocular visual cues. This patient could not have stereopsis, because stereopsis requires binocularity and a heterotropic patient does not have SBV.

## Color Vision

The perception of color by the human eye is one of the most misunderstood concepts by patients. Many people who claim to be color blind are more likely color deficient.

They can still identify the basic colors. So what is color and how do we see it? The information in this part of our lesson is written to bring color vision into perspective, and the place to begin is with color itself. Color depends on three elements—hue, saturation, and brightness.

- Hue is related to the basic color of an object. Put another way, it's related to the wavelength of light reflecting off or emitted by an object. If the wavelength of visible light coming off a car is 400 nm in length, you'll perceive the car is violet. Hue equals color. When someone says the grass is green, the person is telling you its hue, based on the wavelength of light reflected from the grass entering the eye.
- Saturation refers to the purity of the color being seen. The more saturated a color is, the more pure it is. Think of a white rag. You quickly dip it in red paint. When you pull the rag out, it has absorbed a little bit of the paint and looks pink. Now, dunk the rag in the paint and let it absorb lots of paint. The rag is saturated with paint over time, and when you pull it out, it looks very red. The more saturated the rag is, the redder it looks. When you start mixing white into a color, you are desaturating the color.
- Brightness is related to the rate of transfer of light energy coming off a particular color. It's related to the amplitude (amount of energy) of the light reaching our eye. Some colors seem brighter than

others. Think about fluorescent colors. They have higher amplitudes of energy reflecting from them, making them appear brighter. Brightness can affect the color perceived. A bright red is a different shade than a dull red because the bright red reflects higher amplitudes of light energy to the eye.

Most people can differentiate 128 separate hues. At the blue-green end of the visible spectrum, the eye can detect a change of as little as one nm in wavelength (color), but at the red end of the spectrum, 20 nm may be needed to discriminate a different hue. If saturation, as well as hue, is varied, the eye may be able to differentiate as many as 500,000 different color variations. Throw brightness into the equation, and you can see what an incredible instrument the eye is in differentiating colors.

## White Light and Color Perception

The color white consists of a mixture of all the other hues (e.g., red, orange, yellow, green, blue, indigo, and violet). The color black lacks all of these hues. The color we perceive an object to be is the color reflected or emitted from the object. A white piece of paper is white because it reflects all the white light striking it. A black piece of paper absorbs all the light striking it, failing to reflect anything. We notice this absence of color as being black. The grass is green because it absorbs all the different hues from the sun (white light) and reflects only the green wavelength light. Remember, the colors we see are the ones reflected or emitted.

Although there are still many unanswered questions about human color perception, you've learned quite a bit. Using the three primary colors of light (red, green, and blue), any other color of light can be made.

**NOTE:** *Red, green, and blue are the three primary colors of light, which are not to be confused with the three primary colors of pigments used by artists.*

We know the cones of the retina are the primary color receptors and are most functional under photopic (bright) conditions. The darker (scotopic) it gets, the less color we can see. This is because the cones don't work well in dim light, and the rods start to take over. The problem is rods can't differentiate color; they can only see things as "black and white" with varying shades of gray. When lighting conditions brighten up again, the cones start to function once more and our perception of color returns.

Each cone is selectively sensitive to some wavelengths and not to others. We have cones sensitive to red (700 nm wavelength) light, others to green (530 nm wavelength) light, and still others to blue (450 nm

wavelength) light. We know those who have normal color vision interpret the three primary wavelengths of light (red, green, and blue) equally, and they can match all the other colors correctly because of this balance in cone function and perception.

## Normal and Abnormal Color Vision

The person with normal color vision is called a trichromat or three colored. This means the person can see the three primary colors in equal amounts, and depending on how much the various cones of the retina are stimulated, the person can see any color in the visible spectrum. Trichromats make up the majority of the population. Approximately 92 percent of men, and 99.5 percent of women are normal trichromats.

Some trichromats can see the three primary colors, but have problems with one particular color. They see one of the colors in the wrong amount, and have trouble matching a particular color accurately. These people are termed anomalous trichromats--literally, irregular three colors. About 5.4 percent of the population seems to have this problem. Anomalous trichromats can be attributed to a faulty amount of visual pigment in the affected cones. The specific term used to classify a person with an anomalous trichromatic condition is dependent on the cones affected.

A person having trouble with the cones containing the red visual pigment (erythrolabe) is a protanomalous (red-weak) trichromat. A tool to help remember this: "pros drive red race cars." A protanomalous person can see red, but doesn't see it the same as a normal trichromat. These individuals have poor red-green and blue-green discrimination.

A person who has trouble with the cones containing the green visual pigment (chlorolabe) is a deuteranomalous (green-weak) trichromat. A tool to help remember this: "dew is on the green grass." Again, these people can see green, just not the same as a normal trichromat. They have poor green- purple and red-purple discrimination. Deuteranomalous people are by far the most common of the anomalous trichromats.

A person who has trouble with the cones containing the blue visual pigment (cyanolabe) is a tritanomalous (blue-weak) trichromat. A tool to help remember is you can "tri to make me blue." These people can see blue, but not like a normal trichromat sees it. They have trouble with blue-green and yellow-green discrimination.

The thing to keep in mind about anomalous trichromats is they still see all three colors. They just see one of the three colors “differently”, and this causes them some difficulty in discriminating subtle differences between certain hues, depending on the type of cones affected.

A person who can only see two of the three primary light colors is called dichromats or two-colored. About 2.6 percent of the population is dichromatic. The visual pigment they are missing classifies dichromats: protanopes (red-blind) can't see red, deuteranopes (green-blind) can't see green, and tritanopes (blue-blind) can't see blue. Think of it this way, can these people see all three colors? NOPE! Hence prota-nope, deutra-nope, and trita-nope. Take a closer look at how each dichromats vision would be affected.

- **Protanopes (red-blind)** have difficulty discriminating between the longer wavelengths. Red, orange, and yellow may all appear to have the same hue.
- **Deuteranopes (green-blind)** can identify green, but they don't actually see it. The reason they can identify it is interesting. Think of the visible spectrum: red, green, blue. A deuteranope can see red (one end of the spectrum), and they can see blue (the other end of the spectrum). Green is bracketed in the middle, so if a deuteranope looks at a color, and it's not red and it's not blue, it must be green! Relative to the protanopes and tritanopes, the deuteranope is not quite as bad off. Still, deuteranopes tend to confuse oranges and yellows.
- **Tritanopes (blue-blind)** have trouble with yellow and blue. Tritanopes are quite rare.

The only group truly color blind can only see one color. We call this group monochromat. Their entire color perception consists of black, white, and shades in between. Only about one in 13 million people actually has this problem. Remember that the next time someone tells you they are color blind. More than likely, the person has a color deficiency or defect, not true color blindness.

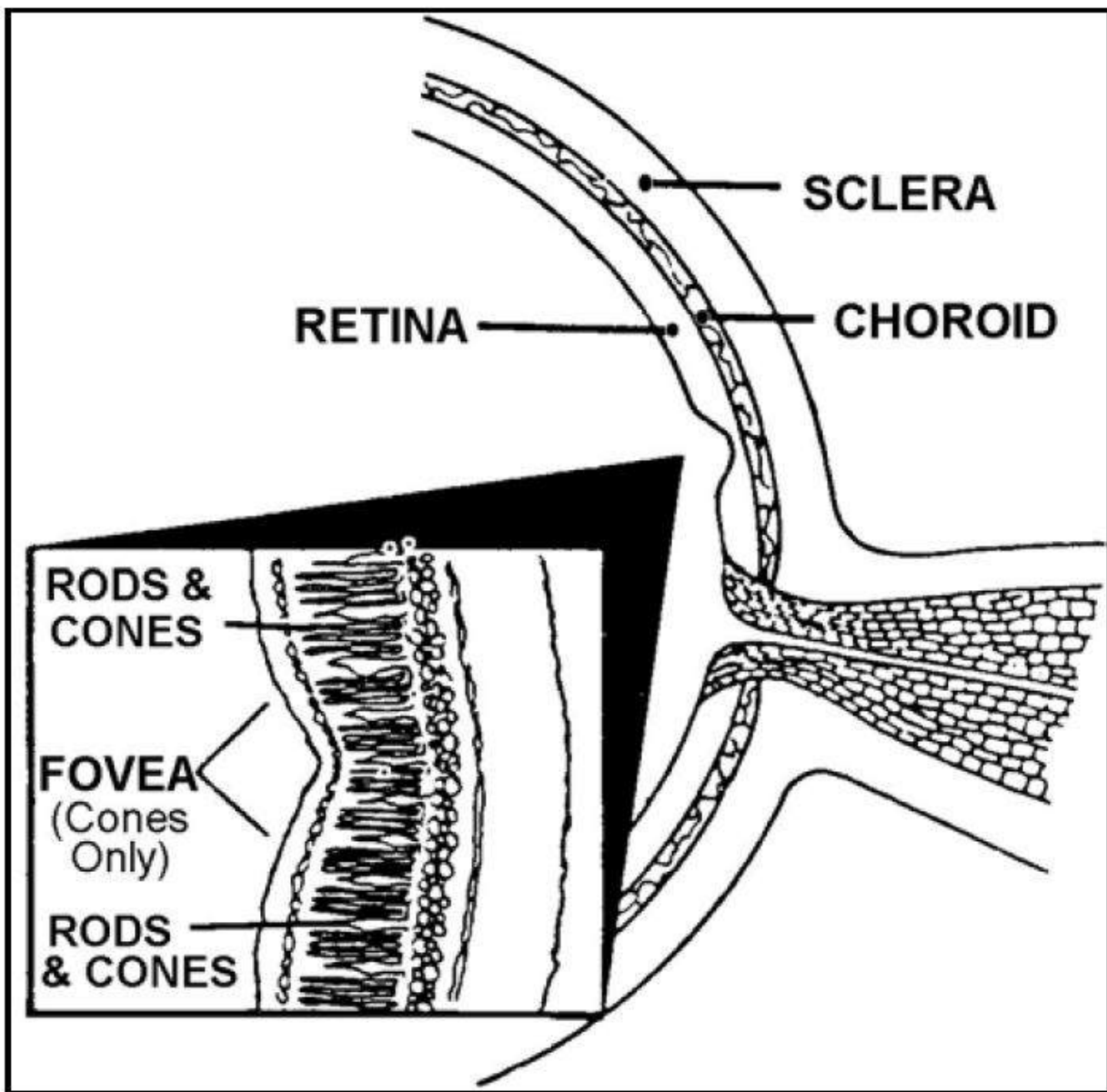
Color defects usually do not change much throughout life. If a person has a color defect, the defect has probably been there since birth since most defective color vision is hereditary. You see, humans possess 23 pairs of chromosomes in each cell of their body. The characteristic for color deficiency is carried on the sex-linked X chromosome. Females have two X chromosomes (XX), while males have an X and a Y chromosome

(XY). If you are a female, you received an X chromosome from your mother and an X chromosome from your father.

If your mother's X chromosome carried the color defect and your father's did not, then you would not have a color vision defect. For a female to inherit a color vision problem, both X chromosomes must have the defect. There is a very slim chance of that. This is the reason only 0.5 percent of females have congenital (hereditary) color vision defects.

On the other hand, if you are a male, you received the X chromosome from your mother and the Y chromosome from your father. If mom gave you the defective X chromosome carrying the color defect, you'll have the defect, as this is the only X chromosome you have. Generally, females carry the defective color vision trait as a hidden characteristic on one of their X chromosomes, and they pass these hidden characteristics on to their sons. We call these sex-linked defects, and since the male only gets one X chromosome whereas girls get two, men end up having defective color vision more often than women. Approximately 8-10 percent of males inherit a color vision defect.

When defective color vision is acquired (i.e., not congenital) it usually indicates a pathological condition, meaning it's due to some eye disease or systemic physical problem. It's interesting that most acquired color deficiencies are of the blue variety, whereas red or green deficiencies are usually congenital. Almost all monocular (one-eyed) color deficiencies are pathological. This is the reason we perform color vision tests in the eye clinic one eye at a time. We are looking for pathological (acquired) color problems because they are indicators of eye or systemic ailments. Congenital (hereditary) defects are present in both eyes, not just one.



## Night (Scotopic) Vision

The retina or nervous tunic of the human eye is composed of photoreceptors called rods and cones. Sound familiar? The cones are located throughout the retina, but are mostly concentrated in the macular area of the retina. Within the macula is the center of our vision, the fovea. The fovea is the area where our best vision occurs. The fovea is exclusively made up of cones, no rods. This is fine in well-lit conditions (photopic), and even pretty good under dim light conditions (mesopic), but is not good for dark conditions (scotopic).

Experimenters have found cones are hooked up to the neural pathway in such a manner they transmit a very fine-grained picture, but they need substantial light levels to operate. When it gets dark, we need rods to see. Where is our finest vision? The fovea of course, but you knew that. What receptors are in the fovea? Only cones, so to see under scotopic conditions we must rely on the rods.

The highest concentration of rods is just outside the macular area. This explains why shifting our gaze slightly to the side under really dark conditions allows us to see things not visible to us when we look directly at them. The rods just outside the fovea are sensitive enough to see what isn't visible to the less sensitive cones.

The downside of rod vision is rods only give a coarse-grained picture to the brain. The best VA achievable by using just our rods is only about 20/200–20/400. Additionally, rods lack the visual pigments necessary to perceive color. Rods contain the chemical rhodopsin, and this chemical produces a monochrome view. What all this means is, under scotopic conditions, our VA is dramatically poorer than normal and we are colorblind. And yet, we see enough to avoid being completely blind under most dark conditions.

Cones as a whole are most sensitive to a yellow-green light (about 555 nm wavelength), while rods seem to have a higher sensitivity to a greenish-blue light (about 508 nm wavelength). This is one of the reasons blue lights seem brighter at night and are used along flight line taxiways for pilots to follow. Reds appear to become dimmer as light levels decrease. Rods are seemingly insensitive to reds, so red goggles are often used to dark-adapt eyes. Seeing red light uses the cones and does not seem to stimulate the rods, so their rhodopsin doesn't get washed out. This preserves night vision.

When a person cannot dark-adapt, the person has nyctalopia or night blindness. Nyctalopia can be caused by glaucoma, retinitis pigmentosa, vitamin A deficiency, excessive alcohol consumption, or any other condition damaging the rods or their functioning.

**Self-Test Questions. After you complete these questions pertaining to depth perception, color, and night vision, you may check your answers at the end of this module.**

1. Name the six cues to depth perception.



Type your answer here

---

SUBMIT

2. Are monocular cues to depth perception considered primary or secondary cues?

---

☐

Primary

☐

Secondary

SUBMIT

3. What is the primary cue to depth perception?

---

☐

Magnification

☐ Confluence

☐ Interposition

☐ Blue-gray

☐ Parallax

☐ Stereopsis

SUBMIT

4. What is the greatest level of depth perception (i.e., smallest amount of separation) the human eye has been able to distinguish?

Type your answer here

---

SUBMIT

5. Which patients can only use monocular cues for depth perception?

Type your answer here

---

SUBMIT

6. Can a person with heterotropia have stereopsis?

---

☐

Yes

☐

No

SUBMIT

7. Select the three elements that color depends on?

---

☐

Hue

☐

Dimness

☐

Saturation

☐

Brightness

☐

None of the above

SUBMIT

8. What is hue determined by?

Type your answer here

---

SUBMIT

9. What does saturation refer to?

Type your answer here

---

SUBMIT

10. If you have one fire engine red object, and a pink object, which is considered to be a more saturated color?

Type your answer here

---

SUBMIT

11. How is a color desaturated?

Type your answer here

---

SUBMIT

12. What is the brightness of a color related to?

Type your answer here

---

SUBMIT

13. If saturation and hues are varied, how many color differentiations can the human eye discern?

---

☐

20,000

☐

100,000

☐

500,000

☐

300,000

SUBMIT

14. White light consists of what colors?

Type your answer here

---

SUBMIT

15. What are the three primary colors of light?

Type your answer here

---

SUBMIT

16. Under what conditions do cones see? How about rods?

Type your answer here

---

SUBMIT

17. What is the term used to describe a person with normal color vision?

Type your answer here

---

SUBMIT



18. What percentage of men have normal color vision? What percentage of women?

Type your answer here

---

SUBMIT

19. What term is used to describe people who see all three primary colors, but see one of the colors in the wrong amount?

Type your answer here

---

SUBMIT

20. A deuteranomalous person has trouble with which color?

---

☐

Blue

☐

Red

☐

Green

SUBMIT

21. What percent of the population is dichromatic?

---

☐

2.0

☐

2.6

☐

3.2

☐

3.0

SUBMIT

22. What is wrong with a tritanope?

Type your answer here

---

SUBMIT

23. What term is used to describe a person who is truly colorblind?

Type your answer here

---

SUBMIT

24. How many people are truly colorblind?

Type your answer here

---

SUBMIT

25. What chromosome carries the color defect?

---

☐

X

☐

XY

☐

Y

SUBMIT

26. Congenital color defects usually affect perception of which color or colors?

---

☐

Blue

☐

Red

☐

Green

☐

Blue-green

SUBMIT

27. If a person only has a color vision defect in one eye, what would you suspect as the cause?

Type your answer here

SUBMIT

28. What could a person do to see an object in very dim illumination?

Type your answer here

---

SUBMIT

29. What level of VA do rods provide?

Type your answer here

---

SUBMIT

30. What color light seems brighter at night?

---

☐

Blue

☐

Red

☐

Blue-green



Green

SUBMIT

31. What is nyctalopia?

Type your answer here

---

SUBMIT



Complete the knowledge check questions before moving to the next lesson.  
The next lesson will cover the ocular terminology, conditions, and disorders.

**COMPLETED**



# Lesson 2: Ocular Terminology, Conditions, and Disorders

---

## Main Points

### 1. Ocular Terminology

- a. Basic parts of medical terminology
- b. Combining forms

### 2. External Conditions and Disorders

- a. Lid disorders
- b. External tumors
- c. Conjunctival and corneal disorders
- d. Eye infections

### 3. Internal Conditions and Disorders

- a. Inflammatory conditions and disorders
- b. Systemic medical conditions with ocular disorders


- c. Conditions and disorders causing sudden vision loss or vision degradation
- d. Other internal conditions and disorders

---

The eye is a complex sensory instrument of the body. When it's healthy and working correctly, it provides the brain vast amounts of information about the world around us. When the eye is working incorrectly, it can be very distressing and traumatic to the patient. Sight is considered critical to normal functioning in our fast-paced society.

Patients who are having problems with their eyes are in need of the best care and information you and your doctor can give them. This unit covers many of the conditions and disorders that can occur within and around the eye; however, before you can identify and understand these eye ailments, you'll first need a basic knowledge of key medical terminology; therefore, we'll start the unit by going over some fundamental ocular terminology. The more you know, the better equipped you'll be to help your patients.

[Click here to start Module 2, Lesson 2.](#)





## Ocular Terminology

To be able to do your job well, you'll need a working knowledge of the language associated with your new career field; therefore, there are many medical terms you'll need to know. Without knowing these terms, you're severely hampered in your work.

## Basic Parts of Medical Terminology

We combine words to understand what medical functions we need to carry out as ophthalmic technicians. The process of learning medical terminology is facilitated by learning basic rules. One approach is to break down the word by evaluating the suffix first, then prefix, and finally the root word.

The lessons that follow go over the more commonly used terms you'll encounter in the medical community. You may already know some of these terms from books, television, or previous experience. These terms evolved over time from Greek and Latin words. Prefixes and suffixes, primarily in Greek, but also in Latin, have a droppable -o-. Generally, this -o- usually acts as a joint- stem to connect two consonant roots (e.g. arthr + o + logy = arthrology). But generally, the -o- is dropped when connecting to a vowel-stem (e.g. arthr + itis = arthritis). Medical root words generally go together according to language: Greek prefixes go with Greek suffixes and Latin prefixes with Latin suffixes. There are hundreds, but we're only going to learn some basic terms to get you started. Once you gain experience evaluating suffixes, prefixes, and root words for their meaning, the process becomes easier.

## Prefixes

A prefix is a letter or a group of letters placed before a root word. Adding a prefix to the beginning of a word changes it into another word. The prefix describes the root word. It tends to indicate size, quantity, position, presence of, and location. Never use a prefix by itself. The following are prefixes you should study so you become familiar with their meanings.

Prefixes	
a/an -	without, not
ab -	away from
ad -	toward, to
ante -	before (location)
anti -	against
auto	self
bi -	two
circum -	around
dys -	difficult
ecto -	on the outside
endo -	on the inside
epi -	on, outer
exo -	external, on the outside
extra -	outside
hemi -	half
hyper -	above or excessive
hypo -	beneath, deficient
infra -	below
inter -	between
intra -	within
mal -	bad, wrong
pan -	all
para -	beside, beyond, related to, altered
patho -	suffering, disease
peri -	around
post -	after
pre -	before (time)
pseudo -	false
quadri -	four
retro -	behind
semi -	half
sub -	under, below
super/supra -	above, over

Prefixes	
tri -	three
un -	not
uni -	one

## Root Words

In medical terminology, root words are words pertaining to the body part, tissue, or organ in which you're referring. The root of a word is its main part and provides its core meaning. Root words can be used alone or can be joined with a prefix, suffix, or both. Study the following root words related to specific body parts.

Most are from the Latin or Greek word for the body organ.

Root Words	
aden(o) –	gland
angi -	blood vessel
arteri(o) –	artery
arthr(o) –	joint
blephar(o) -	eyelid
bronch(o) –	bronchus (division of the trachea)
cardi(o) –	heart
cephal(o) –	head
chondr(o) –	cartilage
cost(o) –	rib
crani(o) –	skull
derm(o) –	skin
encephal(o) –	brain
gastr(o) -	stomach
gloss(o) -	tongue
hepat(o) -	liver
my(o) -	muscle
neur(o) -	nerves
ocul(o) -	eye
ophthalm(o) -	eye
oste(o) -	bone
parei -	cheek
phleb(o) -	vein
pneum(o) -	lung
rhin(o) -	nose
ten(o) -	tendon

Root Words	
thorac(o) -	chest
vas(o) -	blood vessel

## Suffixes

Suffixes are letters added to the end of root words to make a whole word with a specific meaning. Some suffixes form both verbs and nouns so it's important to look at the sentence in which it appears to determine the exact meaning. For example, hemorrhage can mean both "to bleed profusely" (verb) or "profuse bleeding" (noun). In the sentence, "It's possible to hemorrhage profusely from certain injuries," hemorrhage is a verb. In the sentence, "The hemorrhage was caused by an injury to his leg," hemorrhage is a noun.

Additionally, many suffixes have several variations that can make the compound word a noun, verb, adjective, or adverb. For example, in the sentence, "An intense fear of closed spaces is claustrophobia," claustrophobia is a noun. In the phrase, "Relating to or having such a condition is claustrophobic," claustrophobic is an adjective. Study the table below, because you'll hear these suffixes used at your base.



Suffixes	
- ary	connected with or belonging to
- centesis	surgical puncture
- derma	skin
- desis	fusion of two parts into one
-ectasia	expansion, dilation
- ectomy	surgical removal
-edema	swelling
- ema	condition
- ic	pertaining to
- ism	condition, disease, doctrine
- ist	specialist
- itis	inflammation
- lithiasis	formation of calculi or stones
- logy	study of
- metry	measurement
- oma	tumor
- opia	vision
- opsia	vision
- opsy	view with a microscope
- orrhaphy	to suture or repair
- oscopy	to visually inspect
- osis	abnormal condition
- ostomy	formation on an artificial opening into the wall of an organ
- otomy	to cut into an organ
- pathy	disease condition
- pexy	to fasten or fix
- phoria	feeling, carrying
- plasia	formation

Suffixes	
- plasty	to form or mold
- ptosis	falling down, drooping
- rrhaphy	to strengthen, usually with suture
- scope	instrument to visually exam
- scopy	viewing with an endoscope
- sis	state of
- stasis	stopping, constant
- static	maintaining a state
- tomy	process of cutting, incision
- tropia	turning

## Combining Forms

All medical terms have a root word that gives the essential meaning of the word. The word may have a combination of a prefix, root word, and/or suffix to further define its meaning. Before we combine roots with suffixes, there are some rules to follow. Did you notice the root words listed above have a vowel after them (-o-)?

Did you wonder what it meant? English pronunciation demands the following rules be applied for combining words.

- If the suffix does not start with a vowel, we use the vowel with the root word.
  - *Example: arthroplasty*
- If the suffix has a vowel, we do not use the vowel with the root word. It drops off.
  - *Example: nephrectomy*
- If the root word and its suffix both have vowels, insert a consonant between the vowels.

- *Example: pneumonectomy*

***NOTE: There are a few exceptions to these rules.***

An example of one of the above rules is card-, a root word meaning heart. In the word pericarditis, the prefix peri- and the suffix -itis are added to the root word to form the whole word meaning an inflammation (-itis) of the area surrounding (peri-) the heart (card-). The root word can also appear in a combining form, which is the root word plus a combining vowel or vowels. For example, cardiology is formed from cardio- (the root word card- plus the combining vowels -i- and -o-) plus the suffix -logy meaning the study of the heart.

The following are combined medical terms of common operative procedures you should study to become familiar with their meanings. The root word and its meaning are underlined. There may be some new root words not on the previous list.

Combined Medical Terms	
<u>Arthro</u> plasty	Reconstruction of a <u>joint</u> .
<u>Capsu</u> lectomy	Removal of part of the lens <u>capsule</u> .
<u>Capsu</u> lotomy	Incision into the lens <u>capsule</u> .
<u>Crani</u> otomy	Making an incision into the <u>skull</u> .
<u>Kerate</u> ctomy	Removal of <u>corneal</u> layers.
<u>Kerat</u> oplasty	Replacement of scarred/diseased <u>cornea</u> with donor tissue.
<u>Rhino</u> plasty	Reshaping/reforming the <u>nose</u> .
<u>Retino</u> scopy	Visual inspection of the <u>retina</u> .
<u>Retin</u> itis	Inflammation of the <u>retina</u> .

Combined Medical Terms	
<u>Retino</u> pexy	Fasten/seal a <u>retinal</u> hole or tear.
<u>Teno</u> tomy	Cutting a <u>tendon</u> .
<u>Tarsor</u> rhexy	Repair of <u>eyelids</u> (stitching upper and lower lids together).
<u>Trabecu</u> lectomy	Removal of the <u>trabecular</u> meshwork.
<u>Trabecu</u> loplasty	Reshaping the <u>trabecular</u> meshwork.
<u>Trabecu</u> lotomy	Incision into the <u>trabecular</u> meshwork.

Again, as stated before, if a suffix begins with a vowel, do not use the -o-. If the suffix begins with a consonant, retain the -o-. The root word will contain a combining vowel if the suffix begins with a consonant. If not, the combining vowel (usually -o-) is removed. An example is neuritis. The suffix -itis means "inflammation of." The root word neur-, nerve, does not need a combining vowel because -itis begins with a vowel; therefore, this combination of a root word and suffix creates neuritis, meaning inflammation of a nerve.

Having a better understanding of medical terminology will assist you as you continue through the lessons and further explore the various parts and conditions of the eyes. Before moving on, test your knowledge of this lesson by answering the following self-test questions.

**Self-Test Questions. After you complete these questions pertaining to medical terminology and combining forms, you may check your answers at the end of this module**

1. What is a prefix?

Type your answer here

---

SUBMIT

2. What is a root word?

Type your answer here

---

SUBMIT

3. What is a suffix?

Type your answer here

SUBMIT

4. How do you determine the exact meaning of a word that has a suffix?

Type your answer here

SUBMIT



Complete the content above before moving on to the questions in the next section.

1. What is the rule if a suffix does not start with a vowel?

Type your answer here

---

SUBMIT

2. If a suffix begins with a vowel, do you use an -o- to connect the suffix to the root word?


Type your answer here

---

SUBMIT



Complete the content above before moving on to the questions in the lesson.





## External Conditions and Disorders

### External Conditions and Disorders

Although glasses and contact lenses (CL) are a big part of eye-care, there is a greater focus these days for clinics in the military to handle eye infections, disorders, and diseases. As an ophthalmic technician, you may be the first line of care for a patient. You must know what to do, what to avoid, and how to stay calm if you are to help those that come into the clinic.

Additionally, patients will ask you about eye redness, discharge, and other symptoms they might experience. They want your advice. They call you at the clinic, stop you in the commissary, and pull you aside at parties to get your take on what's wrong with their eyes. You are the eye guru, and they want your input; therefore, it would benefit you to understand various eye conditions and disorders and know some of the signs and symptoms of each type. Patients need your help, and you need to have accurate, quality information to ensure they get the proper care.

### Lid Disorders

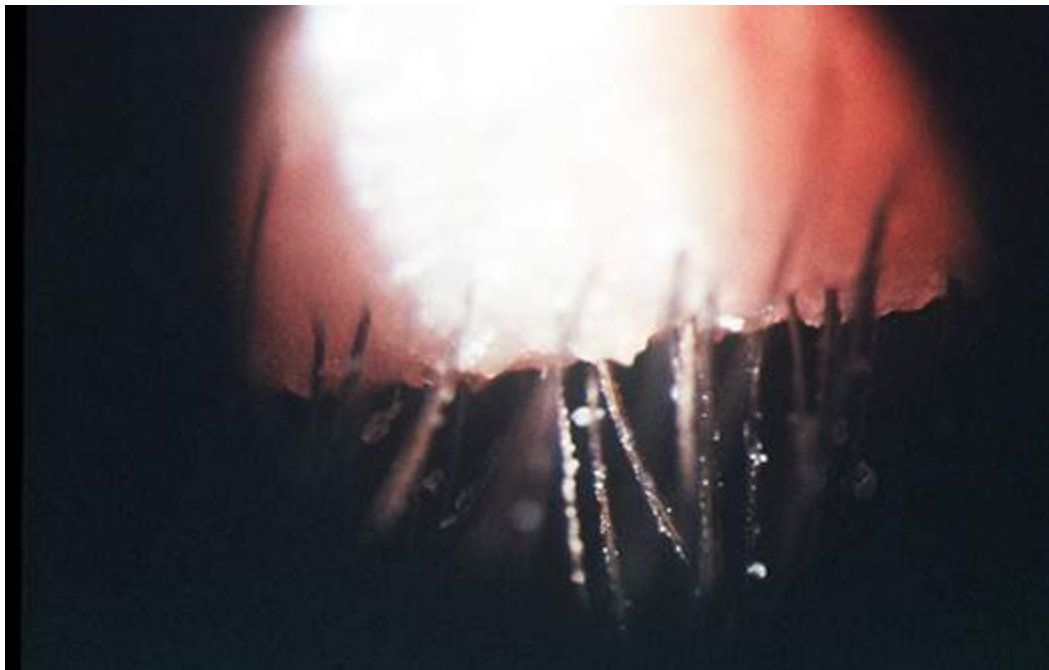
Eye problems external to the globe are quite common. They are usually visible upon screening and a sharp ophthalmic technician will note in the medical record any external ocular disorders observed. This gives the doctor a “heads up” and ensures there is documentation in the medical record of the possible condition. Let's look at some of the more common external eye conditions and disorders you may come across.

Blepharitis is a very common inflammation of the eyelid margins (Blephar = lids; itis = inflammation), usually caused by the bacteria staphylococcus present around the base of the eye lashes. This is why it's often referred to as staph lid disease. It can frequently lead to a bacterial conjunctivitis as the bacteria fall into the eye. The signs of blepharitis are swollen, congested, red eyelid margins, eyelid crusting, and itching (fig. 2-1).

Treatment consists of having the patient scrub the eyelid margins clean with a warm, moist washcloth with a 10:1 ratio of diluted baby shampoo (10 parts water to one part baby shampoo). The patient needs to do this every day and even more than once a day if necessary. The patient also needs to remove the bacteria and the associated debris around the base of the eyelashes. Frequently, the doctor prescribes an antibiotic ointment to use on the eyelid margins after the patient has scrubbed them. This helps kill any remaining bacteria.

If blepharitis is ignored, the eyelid margins can become so infected that eyelashes are lost and scarring occurs, causing the eyelid margins to become uneven and rough. This inhibits the necessary flow of oils from the glands in the eyelids and prevents the eye from receiving proper lubrication. This can lead to corneal problems. Don't let your patients blow off the importance of good eyelid hygiene.

Seborrheic blepharitis is caused by seborrhea (a common cause of dandruff) and is usually treated with daily scrubbing of the eyelid margin alone. In more advanced cases of seborrheic blepharitis, treatment may include using a good dandruff shampoo on the eyebrows and scalp as well. The hazards of non-compliance are the same as previously stated.



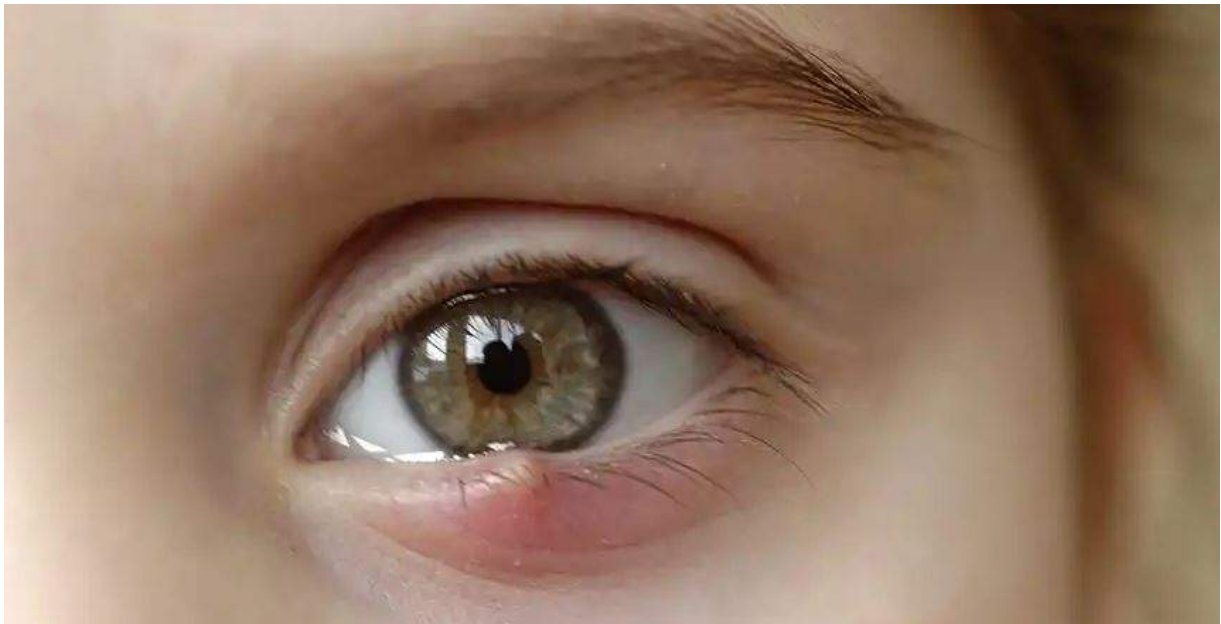## Hordeolum (Stye) —



Hordeolums or styes (which is also spelled sty) are categorized as internal or external. An internal hordeolum is an infection of the meibomian gland. An external hordeolum is an infection of the glands of Zeis, and is usually right near the eyelid margin. Both are caused by an acute infection in the sebaceous (oil) glands of the eyelids. The infection of sebaceous glands usually comes from the bacteria *Staphylococcal aureus*.

This is the same “bug” that causes most blepharitis. The symptoms usually include pain, redness, and swelling. Initial treatment usually consists of warm, moist compresses on the affected eyelid three or four times a day for about 10 minutes each time. The problem with this treatment is most people run a washcloth under some hot water and stick it on their eyelid, where it cools off entirely too quickly; therefore, unless they are persistent at reheating the washcloth, and actually doing it for 10 minutes, this method isn’t very effective.

A tip you can pass on to patients is to boil an egg, wrap it in a wet washcloth, and hold it against the affected area. The egg stays hot for a long time and the continuous heat is much more effective in getting the plugged gland to open up and drain. They can reboil the same egg repeatedly, so they don’t waste eggs. This treatment is designed to encourage the rupture and drainage of the abscess without surgical intervention. If the warm compresses are unsuccessful, an ophthalmologist may cut into (incise) and drain the hordeolum. Fortunately, this treatment is rarely required. Medication used in the treatment of a hordeolum is generally limited to topical antibiotic ointment.



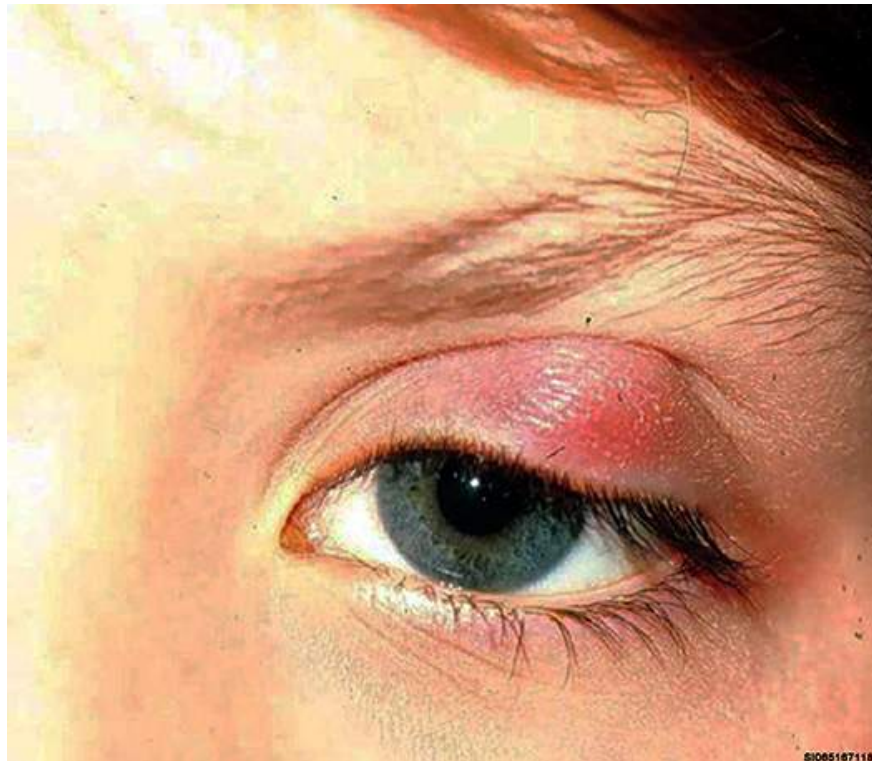## Chalazion —

Chalazion is a Greek word and is pronounced “kah-lazion,” but so many people pronounce it “sha-lazion” that it has become an accepted pronunciation. A chalazion is very similar to an internal hordeolum in location and appearance. The major difference is a hordeolum is a bacterial acute infection in the meibomian gland of the eyelid, whereas the chalazion is a chronic inflammation of the gland with no infection. A way to tell the

difference is that a hordeolum hurts, and a chalazion usually does not. This is not 100 percent foolproof, but it's fairly accurate.

A chalazion begins when a meibomian gland is blocked by some minor inflammation. The sebum (oil) continues to try to flow out of the gland, but backs up due to the blockage. This causes an internal, sterile lump in the eyelid (fig. 2-2). Over time, this lump turns into a cyst and remains on the eyelid.

Initial treatment for chalazion is warm, moist compresses on the affected area three or four times a day for about 10 minutes (the same as hordeolum). If the chalazion has been present for a while, the compresses won't work as the cystic formation may have already taken place. If the compresses don't clear up the chalazion, it must be incised and cleaned out by an ophthalmologist.



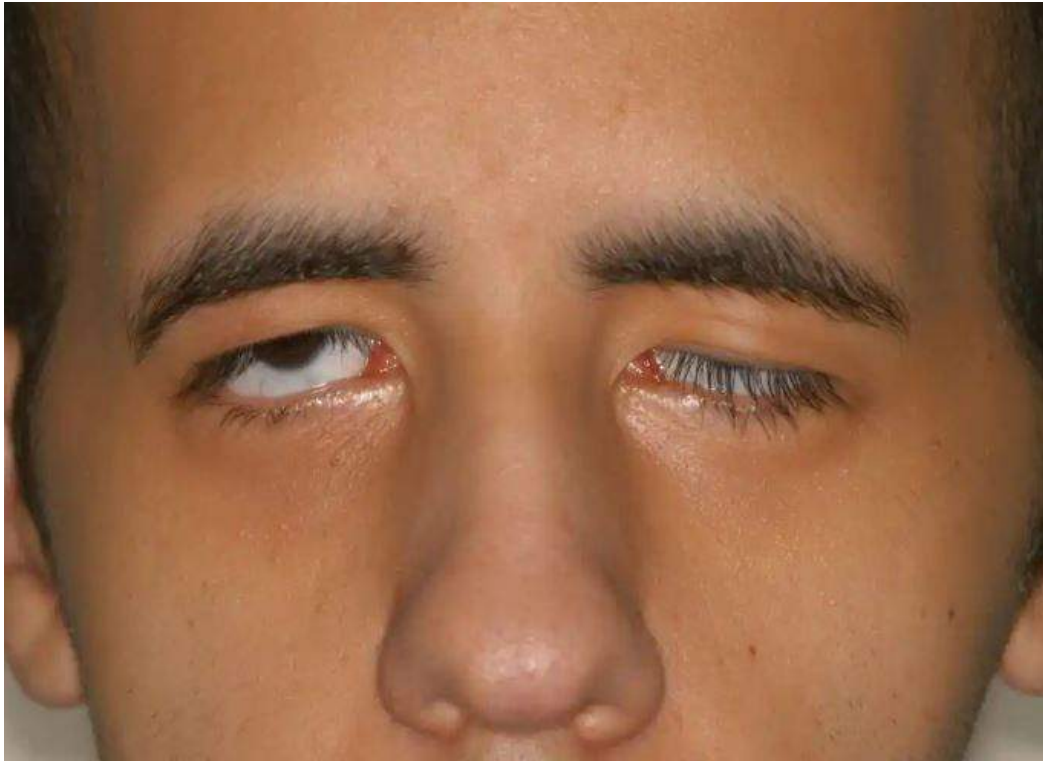## Ptosis —

Simply put, ptosis (pronounced "toe-sis") is eyelid droop. A normal upper eyelid rests about 2 millimeters (mm) below the upper limbus. In ptosis, the eyelid droops farther down the eye (fig. 2-3).

Ptosis can be unilateral (one sided) or bilateral (two sided). There are two kinds of ptosis:

- Congenital (from birth) ptosis is caused by weakness of the levator palpebrae superior muscle in the upper eyelid and is generally corrected with surgical resection (shortening) of the levator muscle. The outcome is usually good and normal eyelid appearance is often achieved.

- Acquired (secondary to another problem) ptosis is best categorized by history. How and when did the ptosis develop? Knowing the root cause of the ptosis allows treatment of the problem. This, in turn, fixes the acquired ptosis. Acquired ptosis can be caused by systemic neuromuscular problems (e.g., myasthenia gravis), trauma to the eyelid, nerve palsy (paralysis), or physical muscle interference (e.g., a tumor in the upper eyelid).



## Orbital Cellulitis —

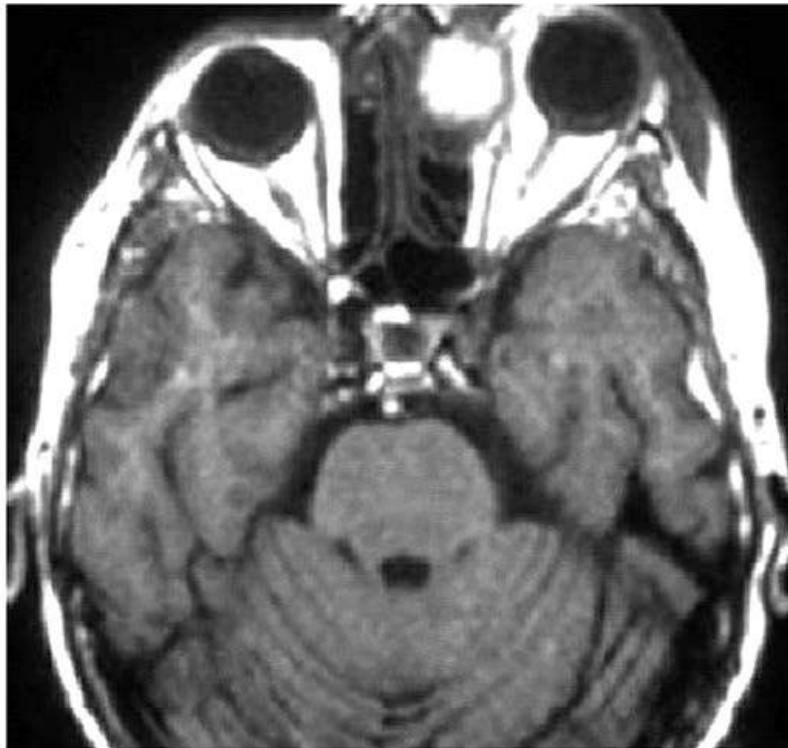This is a critical medical emergency. Orbital cellulitis left untreated can be fatal within just a few days. In most cases, orbital cellulitis is caused by the migration of infection from the sinus area through the thin ethmoid bone. This is why it's sometimes called an ethmoiditis. Because the ethmoid bone is still under development in children; orbital cellulitis is more often found in children with sinus infections. Other possible sources of infection include dental abscess or trauma. Orbital cellulitis is characterized by red eye, pain, blurred vision, headache, and double vision.

However, orbital cellulitis can also be present with some proptosis (displacement of the eye out of the socket), loss of eye movement, and possible decreased vision. Because the diagnosis is difficult, but extremely important, always refer orbital cellulitis cases to an ophthalmologist with no exceptions! Computed tomography (CT) scans and magnetic resonance images (MRI) are quite helpful in diagnosing orbital cellulitis.

The treatment for orbital cellulitis is very aggressive due to the natural path the infection can take directly into the brain and nervous system. Because of the physical positioning of the optic nerve and other structures, the infection can move rapidly to the brain, causing meningitis and death. Treatment includes hospitalization, IV, and oral and topical antibiotics.

If you're not quite sure why orbital cellulitis would cause the globe to protrude out of the socket (proptosis), remember the orbital cavity is quite strong. The only place for the swollen orbital contents to go is out the front opening of the orbit. A sign of orbital cellulitis is swelling of the eyelids and surrounding tissue of the eye, as if an allergic reaction has occurred because of a bug bite.

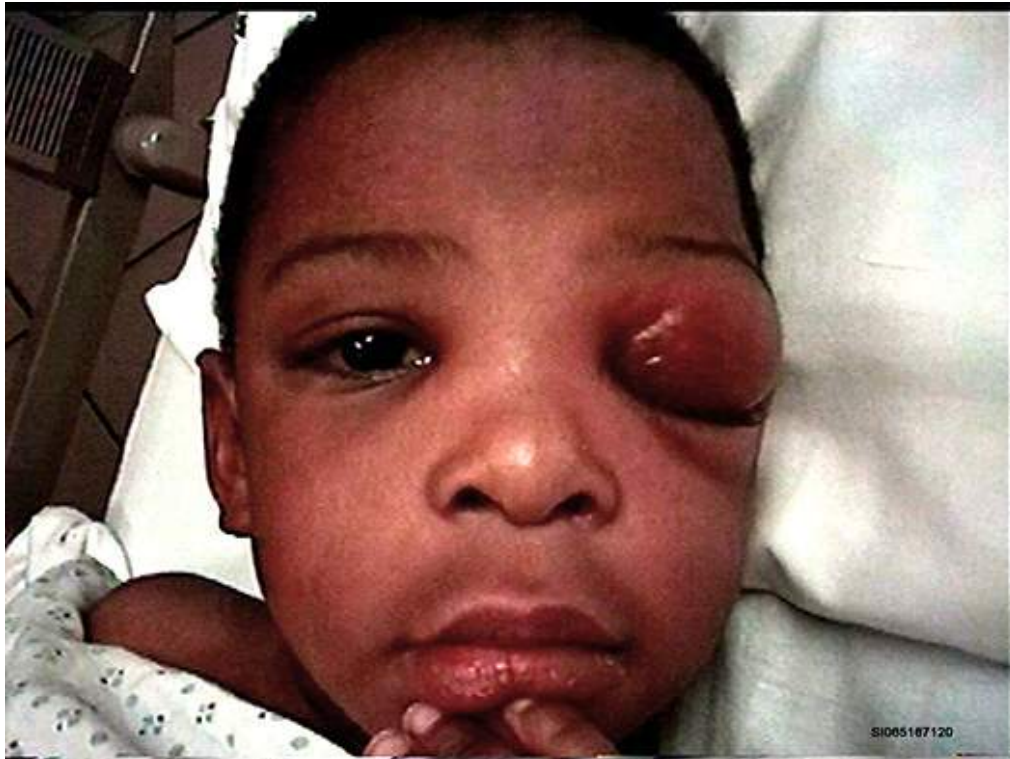The area is sore, and again, it's more likely in kids. If you see a kid with swollen eyelids, question the child and the parents at length to see if there is an obvious cause, such as a bee sting or something similar. If there isn't a good explanation, ask the patient how long the eyelid has been swollen. Is it painful? Has there been an increase in discharge from the eye? You could save a life by being alert and curious.



## Preseptal Cellulitis —

Though it tends to be a less severe condition, preseptal cellulitis (also called periorbital cellulitis) closely resembles orbital cellulitis in its initial stages. Some of the symptoms are similar (e.g., tenderness, redness, and swelling [fig. 2–5]), and both conditions are more common in children than in adults. Preseptal cellulitis is much more common than orbital cellulitis.

In preseptal cellulitis, the infection is confined to the soft tissues that are anterior to the tarsal plate, unlike orbital cellulitis, which can be found posterior to the tarsal plate and involve the whole orbital cavity. Preseptal cellulitis is treated with oral antibiotics. Without treatment, preseptal cellulitis can spread to other orbital tissues.

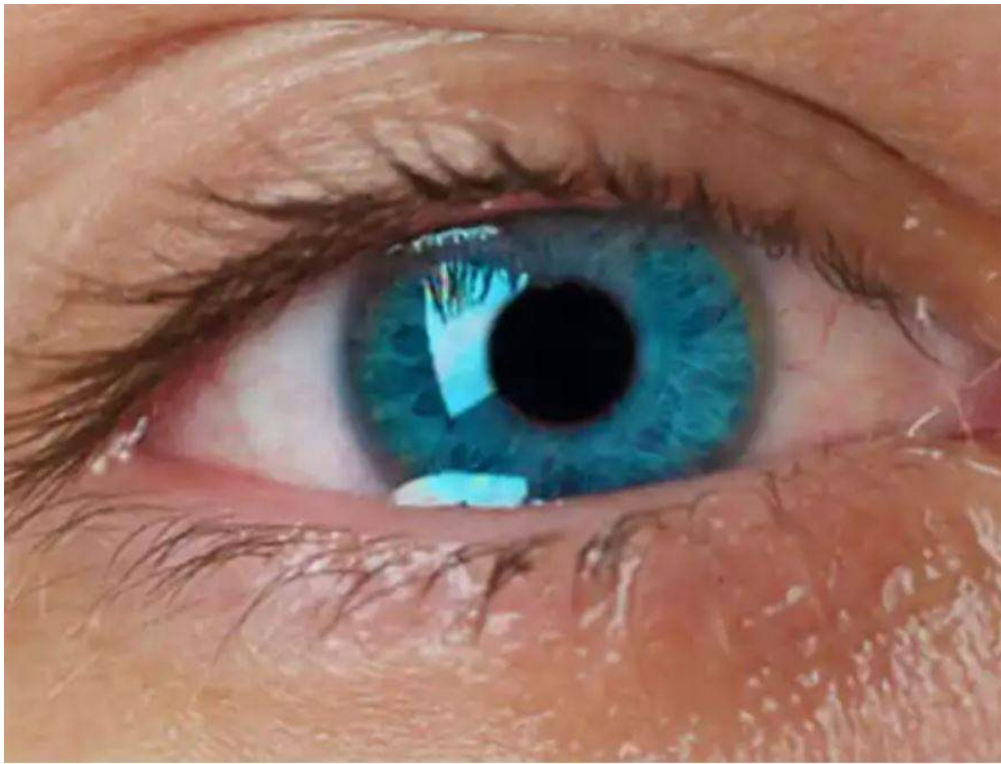


## Epiphora

This is another one of those medical terms making you wonder, wouldn't it be easier to just call the problem what it is—overflow of tears? Epiphora has two causes: overproduction of tears or a poor tear drainage system. Epiphora will cause tears to run down the patient's cheek uncontrollably. As previously stated, this is due to overproduction of tears, or the tears not draining properly, causing the tears to overflow, and make the patient look like he or she is crying.

Overproduction occurs when the lacrimal system goes into overdrive and puts out more tears than a properly functioning tear drainage system can handle. The bottom eyelid sagging away from the globe of the eye (ectropion) or a blockage of the canaliculi can cause a poor tear drainage system. Both of these causes are corrected surgically.



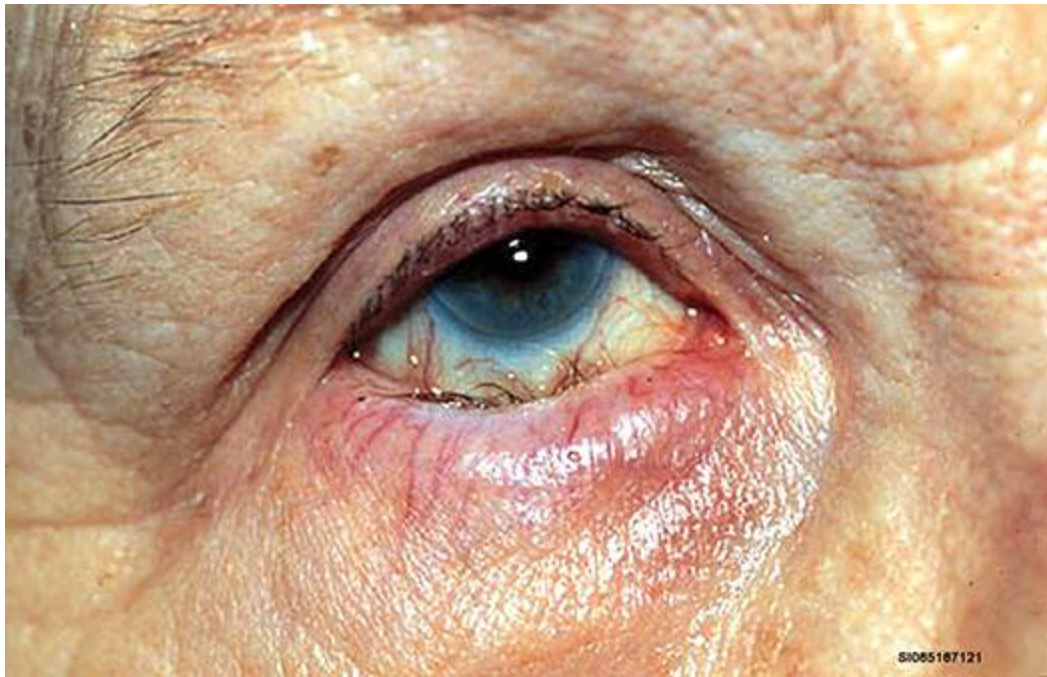


## Entropion —

Entropion is the condition when the eyelid margins turn in towards the globe. This may not sound bad, but think about it. If the eyelid margins are turned in toward the globe, where are the eyelashes? They are now rubbing against the cornea (fig. 2-6).

This can be very irritating to the patient and can lead to more severe problems. With the eyelashes constantly rubbing against the cornea, the patient may suffer from corneal abrasions, ulcerations, and scarring.

There are many causes of entropion, but the most common are laxity of the lower eyelid retractors and buckling of the upper tarsal plate border. Surgical correction to evert the eyelids is an effective treatment for entropion minimizing associated harmful effects.

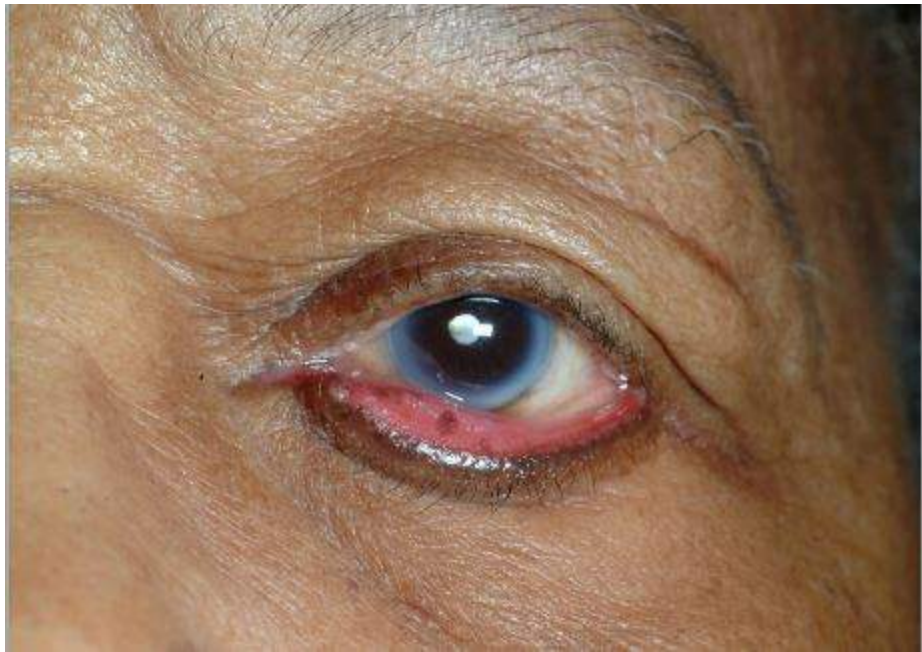

## Ectropion —

Ectropion is the opposite of entropion. Ectropion is the turning out of the eyelids (fig. 2-7) and is a common cause of epiphora. Since the lids are no longer up against the eye, the tears can no longer drain into the puncta properly and end up running down the patient's face.

Tearing itself may not be very harmful, but the constant corneal exposure can be. Without protection from the eyelids and proper lubrication of the cornea, many problems can arise. One such condition is exposure keratitis. Exposure keratitis develops because the eyelids are no longer providing adequate protection of the cornea.

Ectropion is usually found in older patients and is usually seen bilaterally. The orbicularis oculi muscle may have weakened or relaxed over time, and can no longer hold the eyelid in place. When this happens, it results in the eyelid turning out. Surgical repair and even skin grafting may be necessary for more advanced cases.



Complete the content above before moving on.

**Self-Test Questions. After you complete these questions pertaining to lid disorders, you may check your answers at the end of this module.**

1. What is blepharitis?

Type your answer here

SUBMIT



2. How is blepharitis treated?

Type your answer here

---

SUBMIT

3. What is a hordeolum?

Type your answer here

---

SUBMIT

4. How is a chalazion different from a hordeolum?

Type your answer here

---

SUBMIT

5. What types of things can cause acquired ptosis?

Type your answer here

---

SUBMIT

6. Why is orbital cellulitis a medical emergency?

Type your answer here

---

SUBMIT

7. What does treatment of orbital cellulitis include?

Type your answer here

---

SUBMIT

8. What is the difference between preseptal and orbital cellulitis?

Type your answer here

SUBMIT

9. What is epiphora?

Type your answer here

SUBMIT

10. Name severe conditions to which entropion can lead.

Type your answer here

---

SUBMIT

11. What are the most common causes of entropion?

Type your answer here

---

SUBMIT

12. What is ectropion? What can it lead to?

Type your answer here

---

SUBMIT



Complete the knowledge check questions before moving forward in the lesson.

## External Tumors

A tumor is an abnormal growth of cells that serves no purpose. All categories of tumors can be classified as malignant or benign. A malignant tumor is one that continues to grow and invades healthy tissue if not treated. It may or may not spread to other body systems. A benign tumor generally is nonfatal, nonmalignant, and is usually localized.

Fortunately, most tumors in the eyelid area are benign (despite the unsightly appearance they present). The key word in the last sentence is “most.” Not all tumors are harmless, so you want to know which are malignant and can lead to serious visual impairment or death if left untreated.

## Benign Eyelid Tumors

Various types of benign tumors are listed and described in the table below; they increase in appearance as we age. If they are excised (removed), it’s usually for cosmetic reasons or to have a biopsy of the tumor to make sure it’s benign and harmless.

Types and Description of Benign Eyelid Tumors	
Type	Description
Nevus	Are small growths usually present at birth. They may enlarge and darken (become pigmented) during adolescence. They can be removed with minor surgery for cosmetic reasons if desired by the patient. In cases where the nevus does not darken, it can often be confused with a papilloma.
Papillomas	Are the most common benign eyelid tumors. There are two types—seborrheic keratosis and squamous epithelial. Seborrheic keratosis are also known as senile verruca and are generally found in older individuals. They are small brownish/black, raised lesions, much like a button flush on the skin surface. It's removed for cosmetic reasons only. Conjunctival papillomas, a type of squamous epithelial tumor, are common and they generally occur on the caruncle, close to the limbus, and in the eyelid margin area. They can be removed for cosmetic reasons, but have a high recurrence rate after removal.
Molluscum contagiosum	A waxy, raised nodule (lesion) often seen on individuals with a low immunity system. Lesions are caused by the pox virus group. It can cause chronic conjunctivitis because toxic debris from the lesion can end up in the tears, and thus, affect the conjunctiva. It's usually removed by surgery or cauterization (burning).
Xanthelasma	Are yellow, fatty (lipid) deposits (fig. 2–8) on the upper and lower eyelids on the medial side. This is largely a cosmetic tumor, but can indicate a more serious lipid disorder because it means there is a tendency for the body to deposit circulating cholesterol or other lipids.
Keratoacanthoma	A benign lesion that grows rapidly and is often mistaken for a malignant tumor. It reaches its maximum size in 6–8 weeks and may have some spontaneous regression. It's usually excised.

Types and Description of Benign Eyelid Tumors

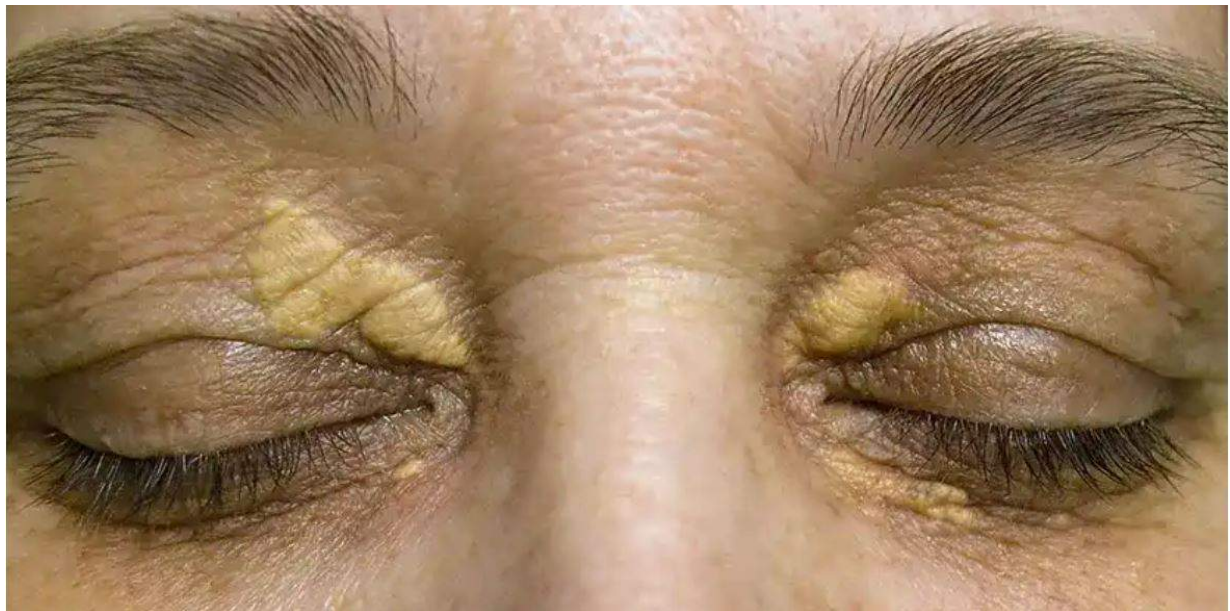

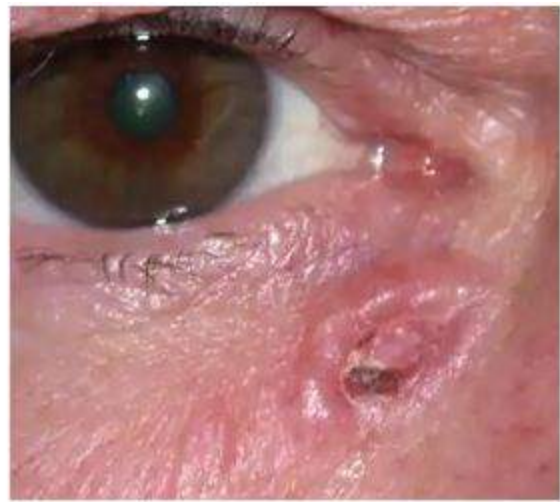
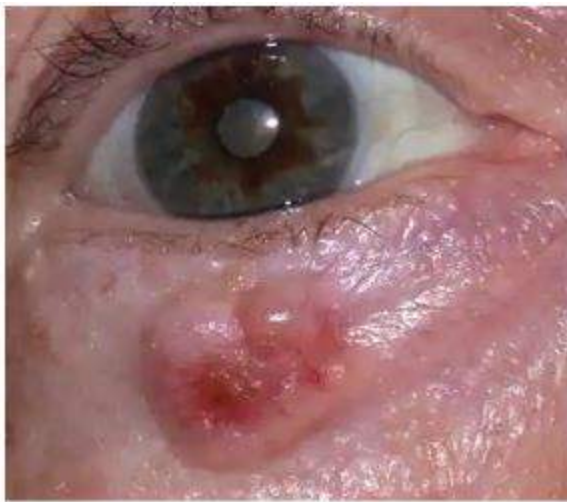Figure 2–8. Xanthelasma.

## Malignant Lid Tumors

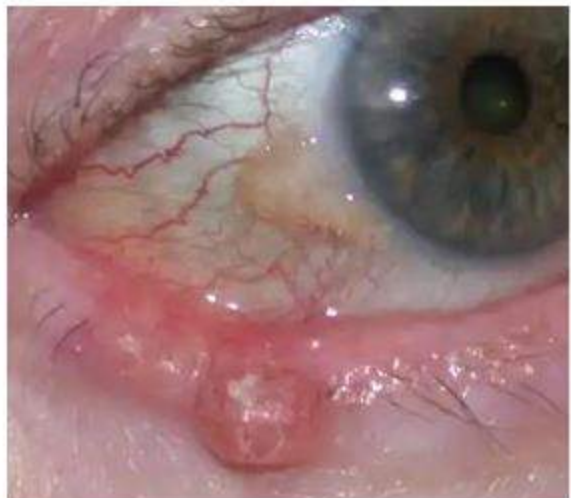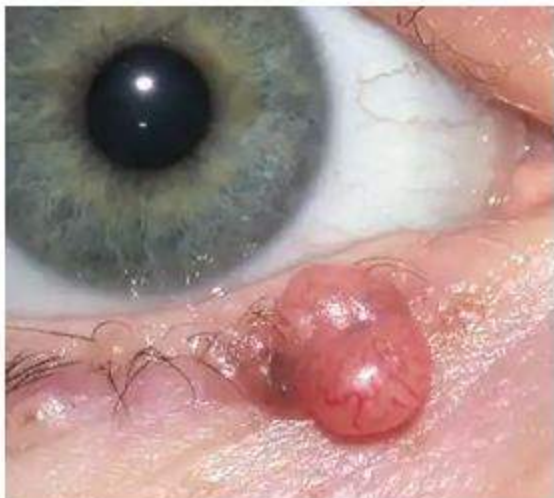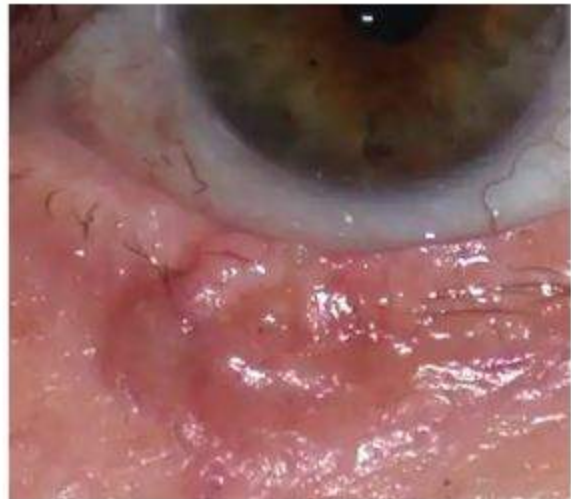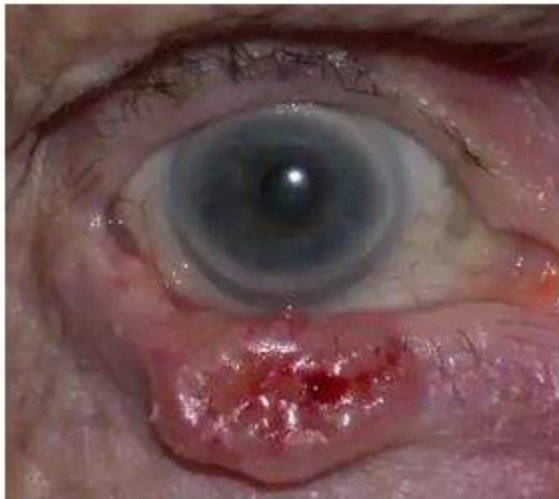Malignant tumors are bad. If you know Spanish or have taken any Spanish classes, you'll remember—mal means bad. The reason they are bad is they are cancerous and destroy tissue, and some even spread to the rest of the body (metastasize).

Treatment of malignant tumors (carcinomas) is by completely excising them. This often means the amount of removed tissue is much larger than the apparent size of the tumor. This ensures no cancerous cells are left behind. Any tumor excised is sent out for biopsy. The reason is many harmless looking tumors removed simply for cosmetic reasons may very well turn out to be cancerous.





If the growth involves the eyelid margin, the eyelashes are usually absent.\* (below)



## Basal Cell Carcinoma



This type of carcinoma is a slow-growing, painless nodule, comprising the highest percentage of all malignant eyelid growths. It most often occurs as a small nodule at the inner aspect of the eye (medial canthus) on the bottom eyelid; it's a very treatable tumor because it does not metastasize.

However, if a basal cell carcinoma is left untreated, it's very invasive and spreads to surrounding tissue. Prompt treatment by surgical removal, radiation treatment, or freezing with liquid nitrogen, can achieve a complete recovery.

It has a very characteristic "donut" appearance and is easily identifiable (fig. 2-9). It typically has a raised ulcerated surface with its margin being pearly white. Exposure to ultra violet (UV) radiation is the main cause, but there is also a hereditary component to getting basal cell carcinoma.

## **Squamous Cell Carcinoma**

This tumor is slow growing and painless. It appears as a red and scaly growth with an ulcer in the center (fig. 2-10). It's prone to spread to surrounding tissue and eventually metastasizes via the lymphatic system, so it must be excised as soon as possible.

Because squamous cell carcinoma is more malignant and can spread throughout the body, the tumor must be completely removed. Excisional biopsy is often the only way to tell the difference between it and basal cell carcinoma.

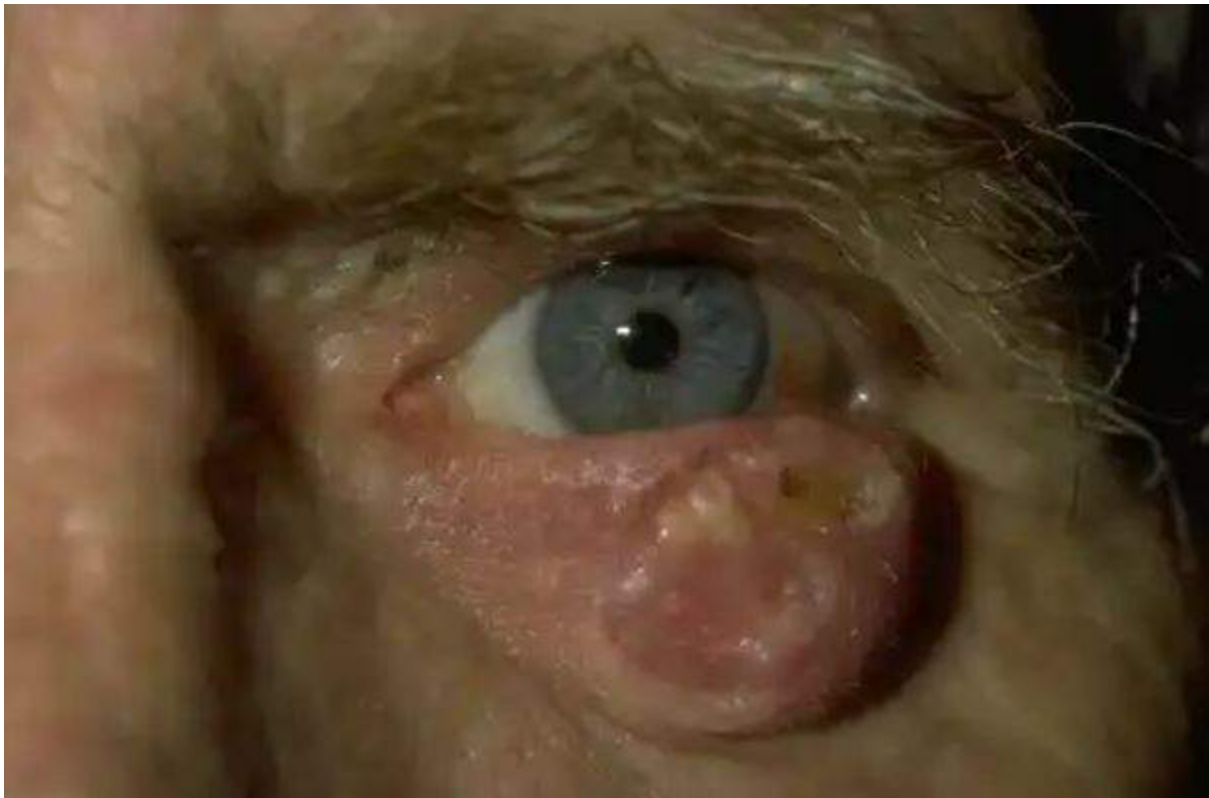

Figure 2–10. Squamous cell carcinoma on upper lid.

## Sebaceous Gland Carcinoma

This tumor develops from the sebaceous (oil) glands of the eyelids and it's often seen in the elderly. It resembles a chalazion or chronic blepharitis about 50 percent of the time. This is even more aggressive than the squamous cell carcinoma, often extending into the orbit, invading the lymphatic system, and metastasizing.

## When to Biopsy

Factors to consider when deciding to biopsy:

- Increased skin growth
- Sore spot that fails to heal
- 6 mm large lesion with pigment, appearing after age 20
- Mole or birthmark with irregular border and changes in size, thickness, or texture.

**Self-Test Questions. After you complete these questions pertaining to external tumors, you may check your answers at the end of this module."**

1. What is the difference between malignant and benign tumors?

Type your answer here

---

SUBMIT

2. List the five benign tumors associated with the eyes.

Type your answer here

---

SUBMIT

3. What benign tumor can cause chronic conjunctivitis? Why?

Type your answer here

---

SUBMIT

4. What benign tumor is indicative of a lipid disorder?

Type your answer here

---

SUBMIT

5. What does it mean when a malignant tumor metastasizes?

Type your answer here

---

SUBMIT

6. When excising a carcinoma, why is more tissue removed than just the area that includes the tumor?

Type your answer here

SUBMIT

7. Which malignant tumor is the most common growth on the eyelids?

Type your answer here

SUBMIT

8. Squamous cell carcinomas metastasize via what system?

Type your answer here

SUBMIT

9. Sebaceous gland carcinomas come from what area of the eyelids?

Type your answer here

SUBMIT



Complete the knowledge check questions before moving forward in the lesson.

## Conjunctival and Corneal Disorders

The conjunctiva is a thin, mucous membrane lining on the inside of the eyelids and the anterior sclera of the eye. In case you forgot, conjunctiva is continuous between the eyelids and the eye. Connected to the cornea via the epithelial cell border, it's continuous between the conjunctiva and the cornea. Because of this, infections and inflammatory conditions and trauma can all potentially extend from one structure to the other.

Conjunctivitis is simply the inflammation of the conjunctiva. Generally, conjunctivitis is characterized by some discharge, grittiness, redness (which is why it's often called pink eye), and swelling. These signs and symptoms vary depending on what causes the conjunctivitis. A good case history can be of great assistance in making an initial diagnosis of what type of infection a person may have. Generally, conjunctivitis falls into three basic categories: bacterial, viral, and allergic (atopic). This lesson covers only allergic conjunctivitis and other non-infective disorders. The next lesson covers bacterial and viral infections of the eye.

## Allergic Conjunctivitis

Allergic conjunctivitis is an inflammation of the conjunctiva due to an allergic reaction (hypersensitivity) of an outside substance. Pollen, makeup, pet dander, dust, or many other things may cause it. People suffering from allergies almost always manifest at least a minor conjunctivitis when exposed to the substance to which they are allergic. Depending on the amount of exposure and the person's sensitivity to the allergen, the reaction can be quite severe.

Allergic conjunctivitis is usually bilateral, as the allergic substance is usually airborne, and therefore, finds its way to both eyes. The exception is when someone gets something on his or her hands, and then touches his or her eye. The reaction may only show up in the eye he or she touched. Some classic characteristics of an allergic conjunctivitis are itching, mild to moderate redness of the eye, and stringy discharge.

Treatment is to remove the person from the allergen if possible. If it's "Fido" the wonder dog, he may need to go. If it's mold and dust from the heating or air-conditioning ducts of the house, a new filter should be installed, and the heater or A/C run for a while without the person being there. If it's pollen outside, the person may need to be treated with an anti-inflammatory medication. Cool compresses help the itching, and over-the-counter antihistamines and decongestants (oral and topical) are helpful. Severe or chronic allergic reactions may require medical work-up to determine the actual substance causing the reaction.

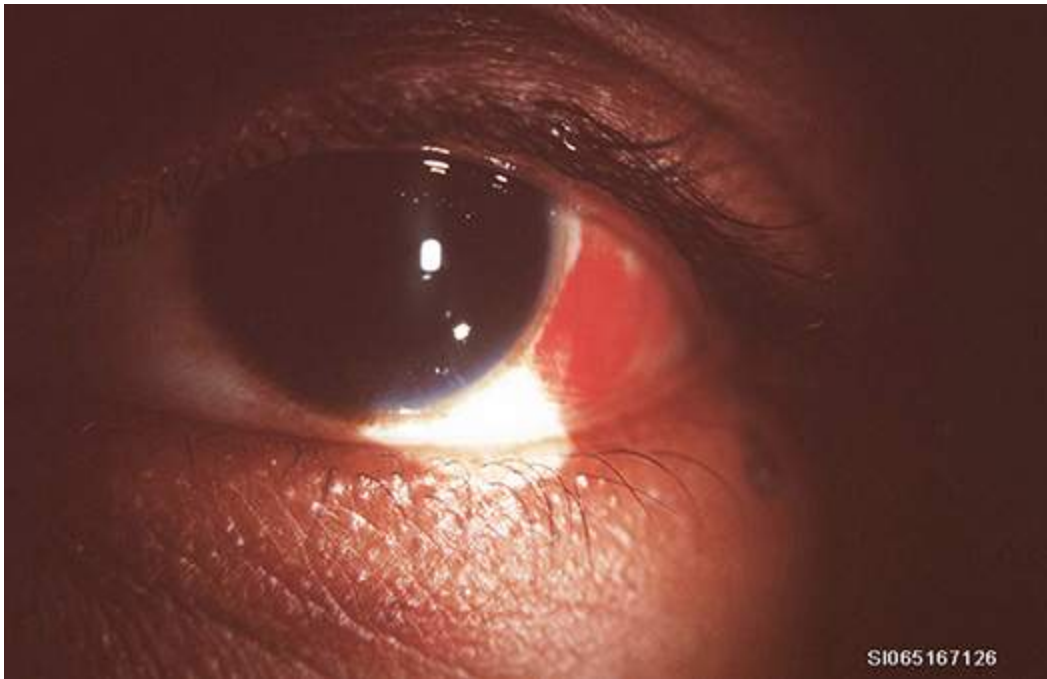


Figure 2–11. Subconjunctival hemorrhage.

---

## Subconjunctival Hemorrhage

A subconjunctival hemorrhage occurs when one or more of the small conjunctival blood vessels ruptures. The blood is then trapped between the conjunctiva and the sclera. Due to the whiteness of the sclera, the blood released upon rupture is quite obvious (fig. 2–11). Simply put, part of the sclera looks bloody! This bloody spot normally prompts a frantic call to the clinic. While quite harmless, it's cosmetically disturbing and just seems too ugly to be harmless.

Coughing, straining, vomiting, or vigorous sneezing can cause a subconjunctival hemorrhage. It's more common in patients with diabetes or hypertension (HTN), and those on a blood thinner (e.g., aspirin or Coumadin). There are no secondary complications, and the hemorrhage normally resolves on its own in about a week or two. Just like a black and blue mark or bruise anywhere else on the body, the blood pigment breaks down and is reabsorbed.

Despite its harmlessness, most doctors want to check the patient anyway, just in case there was a rupture of a blood vessel inside the eye or an unknown foreign body (FB). Additionally, a subconjunctival hemorrhage may indicate uncontrolled high blood pressure, which should not be left untreated.



# Pinguecula

A pinguecula is a benign (harmless) thickening of the conjunctiva. It's usually, but not always, located in the medial canthus area (fig. 2-12).

These yellowish-brown, non-vascularized, sub-epithelial deposits of abnormal collagen are common where people spend a great deal of time outdoors in dry, dusty environments and possibly exposed to the harmful effects of (UV) light.

Normally, there are no symptoms other than they look bad; however, a pinguecula may cause some irritation. If they become symptomatic, artificial tears or vasoconstrictors are the normal treatment. In extremely rare cases, they can be removed surgically. Generally, a pinguecula is a harmless deposit and has no effect on vision. Sometimes a pinguecula may become inflamed and cause irritation, but it's rare.

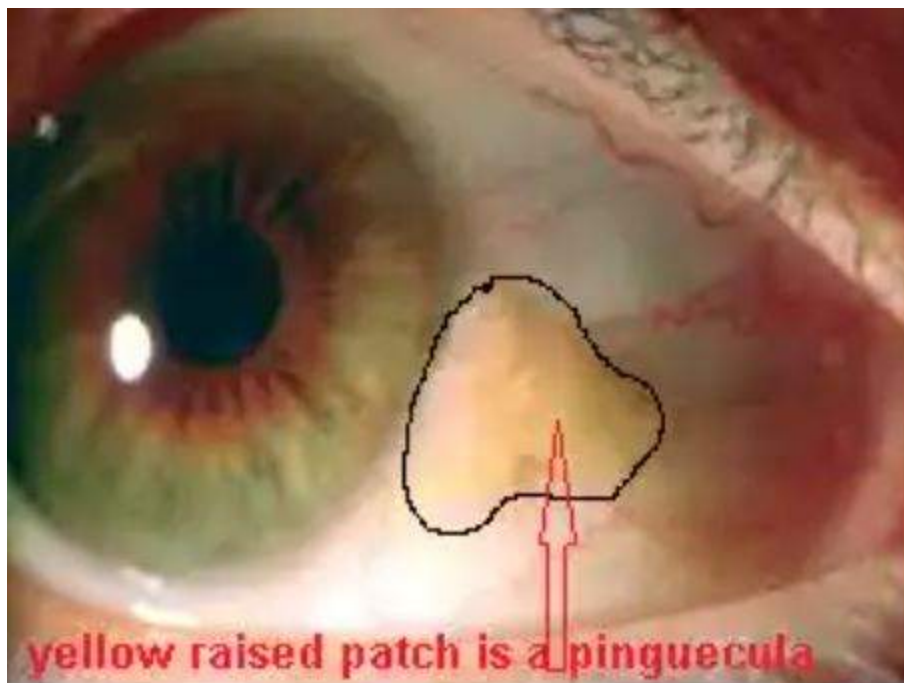


Figure 2-12. Pinguecula.

---

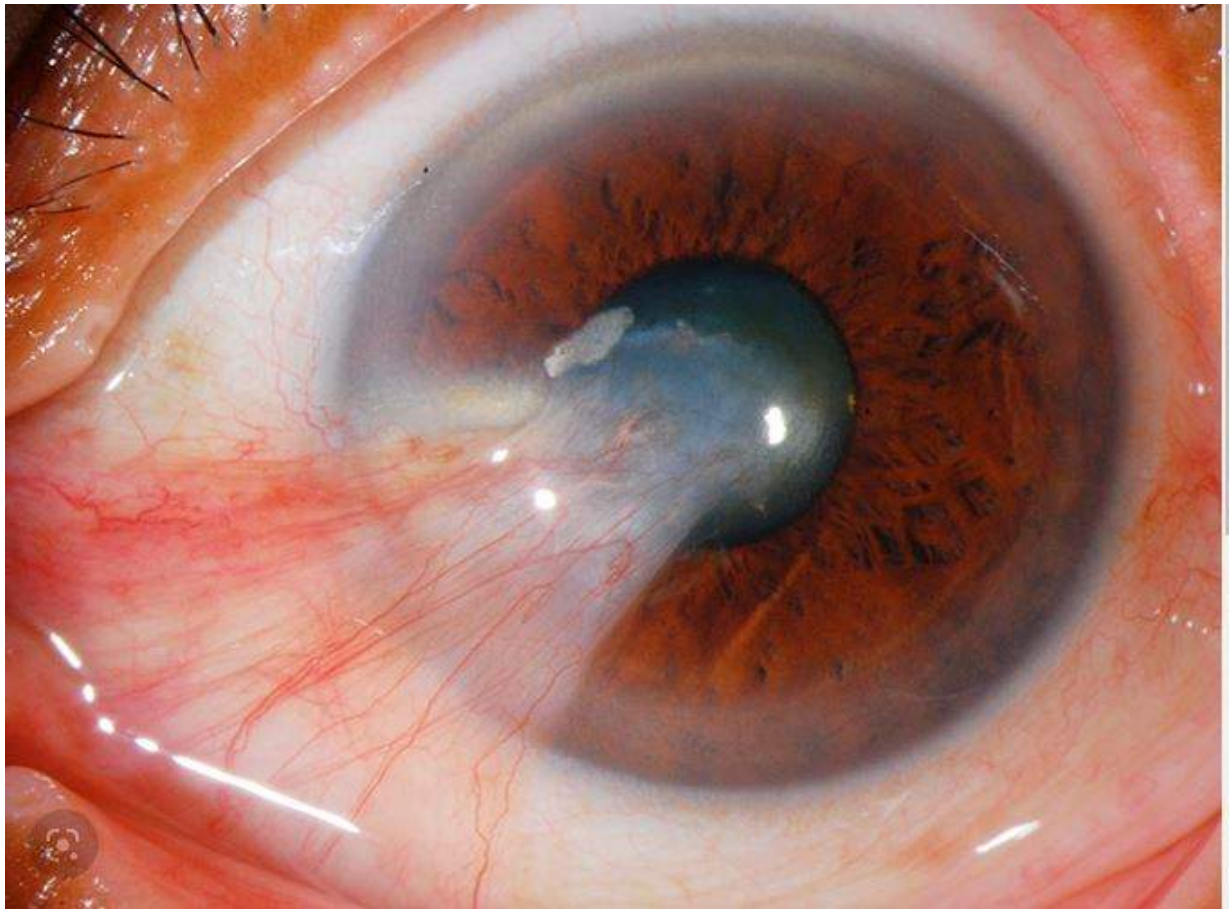


Figure 2–13. Pterygium.

---

## Pterygium

A pterygium is a growth of abnormal conjunctival tissue onto the cornea (fig. 2–13). The pterygium is vascular and involves all the layers of the bulbar conjunctiva. Unlike a pinguecula, which is harmless, pterygia grow on to the cornea and may cause visual problems.

The pterygium's growth on the cornea can create tension, which can lead to abnormal astigmatism. Additionally, if the growth keeps migrating across the cornea, it can interfere with the visual axis of the eye (the area in front of the pupil) and threaten the patient's vision.

Until a pterygium becomes visually threatening, most doctors elect to just monitor its growth and leave it alone. Since a pterygium may be the result of, or encouraged by, dry dusty environments and UV exposure, most doctors prescribe artificial tears, and recommend patients wear a quality pair of UV-blocking sunglasses when outdoors.

You may wonder or have patients ask why the pterygium isn't removed the minute it gets on the cornea, or better yet, before it even gets to the cornea? Well, some pterygiums just seem to go to a certain point and stop, so until there is a reason, most doctors don't want to do an unnecessary procedure.

Second, after removing a pterygium, reoccurrence is about 40 percent. If it does reoccur, it often comes back quicker and bigger than before. Continual removal is risky. Every time it's removed, there is a chance of infection, or corneal, scleral, and conjunctival scarring.

If the pterygium comes back repeatedly, the doctor must consider how many times a person can have surgery in the same place without complications. In hopes of preventing future reoccurrence, post excision studies have been conducted using cautery (burning the old vessels), lasers (also to burn the old vessels), beta radiation treatment, and drugs. These preventative procedures work to some degree, but their effectiveness hasn't been proven, and some even have negative consequences of their own if used (i.e., steroids can slow regrowth, but long-term steroid use can lead to cataracts, and there is often a rebound effect when their use is discontinued). There are no easy answer to pterygiums.

## Dry Eye Syndrome

Dry eye syndrome is pretty much what its name implies. Severe dry eye is also known as keratoconjunctivitis sicca (K-sicca for short). A dry eye is an eye with a tear deficiency. Due to lowered lacrimal production the conjunctiva and cornea are chronically irritated. This may lead to erosions and eventual scarring of the cornea.

Treatment of dry eye consists of artificial tears during the day and ointment at night. If drops or ointments are not adequate, plugging the puncta is another approach. The punctum can be plugged with plugs (temporary) or cauterized shut (permanent). Another possible treatment is with a medical device known as Lipiflow that uses heat and pressure on the eyelids to unclog blocked glands.

These glands produce oil as part of the tear film. The oil lubricates the eye and prevents the tears from evaporating. Another treatment for dry eye is the use of the eye drop Restasis. This prescription eye drop helps your eyes increase their own tear production. Additionally, there is growing evidence that taking fish oil and omega-3 via supplement or diet may help to alleviate dry eye symptoms.

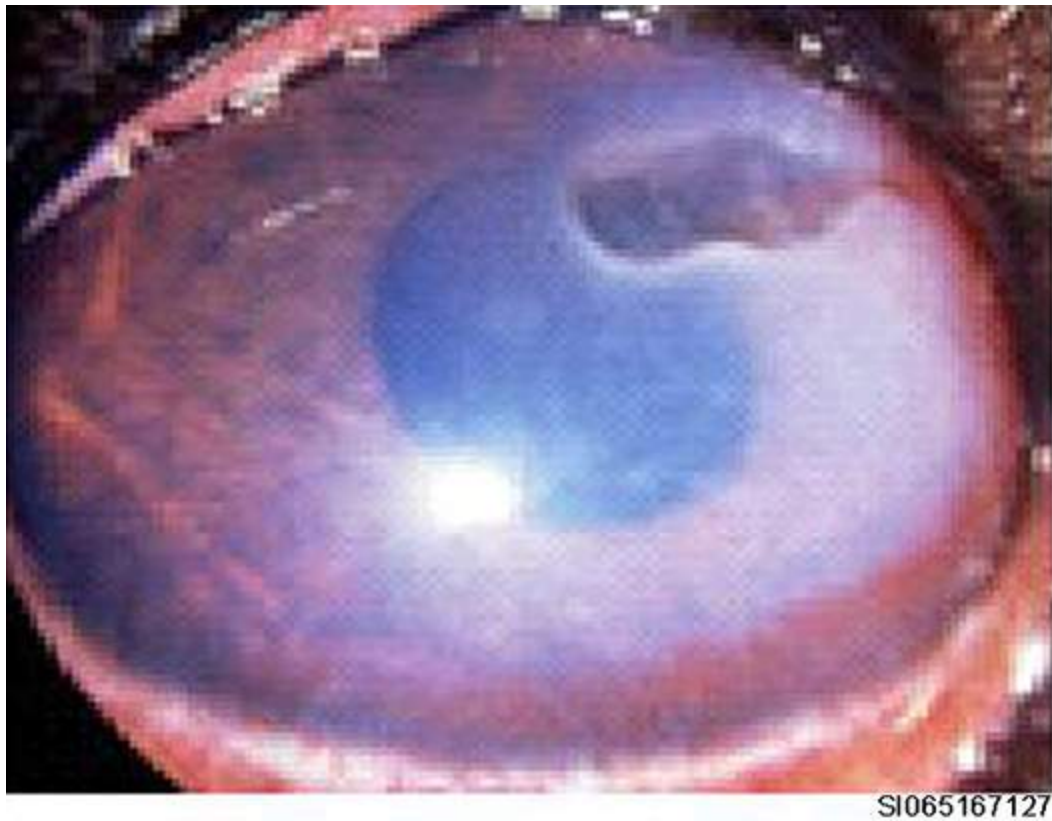


Figure 2-14. Corneal ulcer.

## Corneal Ulcers

A corneal ulcer is an area of epithelial tissue loss (fig.2-14) from the corneal surface associated with parasitic, bacterial, viral, or fungal infection of the eye. A corneal abrasion is not a corneal ulcer, though if infected, an abrasion could easily turn into an ulcer.

Ulcers are not an everyday occurrence, but they are a serious and urgent problem. Permanent visual loss and even loss of an eye can occur due to a corneal ulcer, especially if the cause of the ulcer is a nasty parasite called *Acanthamoeba*.

*Acanthamoeba* is a serious infection. It can penetrate the cornea completely, causing infections of the inner eye and leakage of aqueous. *Acanthamoeba* is a single-celled protozoan found in soil and contaminated water. Typically, it's more common in patients who wear extended-wear soft CLs or who had exposure to hot tubs, communal baths, and even plain tap water.

## Corneal Ulcers

The risk of infection for soft CL wearers increases when they use homemade saline solution, rinse their lenses with tap water, or swim with their soft CLs in. The number of acanthamoebic infections, thankfully, is rare, but those who do acquire this parasite are in immense danger. It's very tough to kill. It can even live through hydrogen peroxide disinfection, but is most effectively killed by heat disinfection. Now imagine it in your eye. You cannot "cook" your cornea to kill the parasite, and most medications presently available have a minimal effect on destroying it. Swift medical attention by an ophthalmologist and hospitalization is the usual course of action for acanthamoebic ulcers.

Corneal ulcers can also occur due to ignored bacterial infections. One of the most infectious and contagious of the bacteria-causing germs is the *pseudomonas aeruginosa*.

You'll learn more about infections in the eye in the next lesson, but for now just be aware that *pseudomonas aeruginosa* is a bacterium found frequently in contaminated fluorescein solutions, saline, and other CL solutions. It's the most common cause of corneal ulcers in patients wearing CLs. If the pseudomonal bacteria is not treated, it can cause severe eye infections with corneal "melting" and rapid loss of the eye within days. Another common cause of corneal ulcers is a viral infection (e.g., herpes simplex virus [HSV]).

Recurrent corneal erosions cause other common corneal ulcers. If an organic material (e.g., paper, tree branch, or fingernail) injures a cornea, the epithelium often heals poorly, and then spontaneously sloughs off cells, leaving an exposed area on the cornea. Patients notice this erosion, or ulceration, most frequently first thing in the morning when they awaken and notice they have severe pain in their eye and it's very red. Treatment generally consists of an antibiotic ointment, and possibly, a pressure patch.

For any of the corneal ulcers, use aggressive treatment to prevent permanent vision loss. Ulcers caused by *acanthamoeba* and *pseudomonas aeruginosa* can be especially hazardous, as these organisms could actually penetrate through all five layers of the cornea and infect the inside of the eye (endophthalmitis). This is extremely damaging because the eye may require surgical removal to prevent further infection of the body. Ulcers can be very serious business.

## Keratitis

Keratitis is a corneal inflammation, characterized by a loss of luster and transparency, with accompanying cellular infiltration of the cornea. The cornea is usually compromised in some manner prior to this condition. The cornea can be compromised by certain infectious organisms, mechanical injury (e.g., corneal abrasion), or acidic and alkalotic chemicals. Some of the more common keratitides are listed below.

- **Herpetic keratitis** is caused by an HSV infection. It's essentially dendritic keratitis and can develop into disciform keratitis. Dendritic keratitis is a recurrent corneal epithelial inflammation. Consisting of branch-like lesions (dendrites), it can sometimes lead to formation of larger, irregularly shaped ulcers. Disciform keratitis is an inflammation of the stroma and appears as a disc-shaped, gray, opaque lesion.
- **Exposure keratitis** occurs when the cornea dries out, which is caused by the eyelids not fully closing during sleep. Also called lagophthalmos (inability to fully close eyelids), it's generally caused by a 7th CN (facial nerve) palsy, affecting the orbicularis oculi's ability to fully close the eye. Another cause of exposure keratitis is from proptosis of the eye, often due to a hyperthyroid condition.
- **Filamentary keratitis** occurs when loose epithelial cells break free, leaving small painful ulcers in the cornea. It's associated with keratoconjunctivitis sicca (i.e., dry eye syndrome) and trachoma, an infection caused by a chlamydial parasite.
- **Superficial punctate keratitis (SPK)** is a condition in which the cornea develops epithelial erosions caused by bacterial, viral, or fungal infections. It's also associated with severe dry eye conditions. The erosions are painful and can be seen quite easily using rose bengal and fluorescein stains.

Since keratitis may be the result of so many different conditions, the treatment is dependent on the cause of the corneal inflammation.



Figure 2–15. Keratoconus.

---

## Keratoconus

Thinning of the cornea and development of a cone-shaped protrusion of the central cornea characterizes this degenerative corneal disorder called keratoconus (fig. 2–15). It usually affects both eyes and occurs most often in the second decade of life (ages 20–29). The “coning” of the cornea results in large amounts of irregular myopic astigmatism not adequately correctable with spectacles.

In the early stages of keratoconus, rigid gas permeable (RGP) CLs are a significant help in correcting vision and have been found to seemingly slow the progression of this condition.

Advanced keratoconus patients with decreased vision that can no longer be corrected with RGP CLs may be considered as candidates for possible corneal transplant.

**Self-Test Questions. After you complete these questions pertaining to conjunctival and corneal disorders, you may check your answers at the end of this module.**

1. What are some classic signs of allergic conjunctivitis?

Type your answer here

---

SUBMIT

2. What is a subconjunctival hemorrhage?

Type your answer here

---

SUBMIT

3. What are some causes of a subconjunctival hemorrhage?

Type your answer here

---

SUBMIT

4. Describe a pinguecula. Who commonly gets them?

Type your answer here

---

SUBMIT



5. Describe a pterygium.

Type your answer here

---

SUBMIT

6. What is another name for dry eye syndrome? What exactly is a dry eye?

Type your answer here

---

SUBMIT

7. What are some problems associated with dry eye syndrome?

Type your answer here

---

SUBMIT

8. What is a corneal ulcer?

Type your answer here

---

SUBMIT

9. When associated with the eye, where has the single-celled protozoan acanthamoeba typically been found?

Type your answer here

---

SUBMIT

10. If pseudomonal bacteria is not treated, what severe consequences can occur?

Type your answer here

---

SUBMIT

11. What is keratitis?

Type your answer here

---

SUBMIT

12. Describe disciform keratitis.

Type your answer here

---

SUBMIT

13. What is lagophthalmos?

Type your answer here

---

SUBMIT

14. What is keratoconus?

Type your answer here

---

SUBMIT

15. How is keratoconus treated in its early stage? Advanced stage?

Type your answer here

---

SUBMIT



Complete the knowledge check questions before moving forward in the lesson.

## Eye Infections

Eye infections can be very destructive and vision threatening. In this lesson, you'll learn about microbes that cause some of the more common eye infections. You'll also learn that "pathogenic" describes organisms that cause diseases in normally healthy tissue and "virulence" describes how persistently and quickly the pathogenic organism spreads. As stated in the previous lesson, generally conjunctivitis is characterized by some discharge, grittiness, redness (which is why it is often called pink eye), and swelling.

These signs and symptoms vary depending on what causes the conjunctivitis. Specific signs and symptoms of bacterial conjunctivitis are a very red eye or eyes (doctors often use the term injected, because the blood vessels are injected or full of blood); mucus discharge; eyelids stuck together in the morning; FB sensation; and a gritty feeling. The infection usually starts in one eye, then infects the other eye. This occurs from patients touching their eyes. Since family members may also become infected, instruct them to wash their hands, and use separate towels than the infected patient.

We are lucky that our tears contain proteins with anti-infective qualities. These proteins, along with blinking, minimize the chances of an infective organism getting a foothold in the eye. Obviously, the system is not foolproof, or we would never see an eye infection. Unfortunately, people still get infections because there are some very persistent organisms out there. So, what are the various bacteria, viruses, and fungi affecting the eyes? Read on and find out.




Figure 2–16. Morphology (shapes) of bacteria.

## Bacteria

The morphology (shape) of the bacteria is an important differentiation in classification. Some are round (cocci), some are rod-shaped (bacilli), and some are spiral shaped (spirochetes) (fig. 2–16). Bacteria can also be classified by their arrangement. If they are clustered like grapes, we consider them staph; if they are forming in chains, they are considered strep.

A gram stain traditionally classifies bacteria. Bacteria can be gram-positive or -negative. Gram-positive means the bacterial cell walls stain blue when tested. Gram-negative means the cell wall stain pink or red when tested.

The differentiation of gram-positive or -negative bacteria becomes important when choosing an antibiotic to fight the infection. Some drugs are good at killing gram-negative bacteria, while others are better at killing gram-positive bacteria. Since lab work to determine what kind of bacteria is infecting an eye takes time, most doctors start with a broad-spectrum antibiotic to try to encompass as many different bacteria as possible. When the lab work comes back, the doctor can then begin to target the bacteria more specifically and effectively. Determining whether a bacterium is gram-positive or -negative does matter when it comes to specific treatments.

### Staphylococcus

Staphylococcus is a round-shaped, gram-positive, pus-producing bacterium. It's often responsible for the following conditions:

- Blepharitis
- Hordeolum
- Bacterial keratitis
- Bacterial conjunctivitis

*Staphylococcus aureus* is the most common cause of bacterial conjunctivitis. *Staphylococcus epidermidis* usually is a harmless inhabitant of the eyelids and conjunctiva, but it can also produce blepharoconjunctivitis (inflammation of the eyelids and conjunctiva). This bacterium tends to colonize in eye cosmetics.

This is why you should not share eye makeup! Occasionally, staph is responsible for keratitis (inflammation of the cornea), but it usually is not the major player in these cases.

## Streptococcus

*Streptococcus* (strep) is also a gram-positive bacterium with a chain or rod shape. Of all the streptococci organisms, the most common one affecting the eye is *Streptococcus pneumoniae*. It can be the cause of the following conditions:

- Conjunctivitis
- Corneal ulcers
- Endophthalmitis (inflammation of internal eye tissues)

Strep is usually found in the respiratory tract, but this doesn't necessarily mean the organism is causing harm in that location; however, if it spreads from the respiratory tract into the eye, the eye is affected.

## Gonococcus

*Gonococcus* is a gram-negative organism with a characteristic kidney-bean shape. This infection produces a profuse oozing discharge.

Ever heard of gonorrhea? This is the responsible bacterium. It's a nasty bug we surely do not want infecting the eye. It's capable of significant ocular infection and subsequent damage. Gonococcal bacteria are one of the organisms responsible for neonatal conjunctivitis, also known as ophthalmia neonatorum. This occurs

when newborns are exposed to the organism while traveling through the birth canal. Gonococcus can also cause

- blindness
- corneal ulcers
- endophthalmitis
- severe lid and conjunctival swelling

Infections usually become noticeable within two to four days of contact with the organism. To minimize harm, prompt action and appropriate treatment is required.

## **Hemophilus Aegyptius (Koch-Weeks Bacillus)**

This organism is a slender gram-negative rod-shaped bacterium. It's the same organism that causes pneumonia in people. In the eye, it normally causes an acute, pus-producing conjunctivitis; it's also highly contagious. It can be the cause of post-traumatic preseptal cellulitis in children between the ages of six months and three years of age. It can also cause orbital cellulitis in children with sinus infections.

The clinical signs of eyelid and conjunctival edema are also common to preseptal and orbital cellulitis. Preseptal cellulitis is inflammation of the tissue just beneath the skin, yet anterior to the orbital septum (roughly the tarsal plate layer of the lid). The septum acts as a barrier to prevent organisms from spreading more posterior (closer to the eye). If there is involvement posterior to the septum, it's orbital cellulitis.

The clinical signs of orbital cellulitis include ocular motility defects, proptosis, and visual loss. Orbital cellulitis can occur without preseptal cellulitis occurring first. It just depends on where the bacterium begins its invasion of the tissue surrounding the eye. An orbital cellulitis constitutes a true medical emergency; it can cause blindness and life-threatening intracranial infections.

## **Pseudomonas Aeruginosa**

Previously mentioned in the conjunctival disorder lesson, pseudomonas aeruginosa is a long, slender, gram-negative rod bacteria frequently found in contaminated fluorescein solutions, saline, and CL solutions. If not treated quickly and aggressively, it can cause severe eye infections with corneal melting and rapid loss of



the entire eye within days. This is the most virulent (fast spreading) of the bacterial causes of corneal ulcers.

*Pseudomonas* grows in any moist environment, including eye drops, cosmetics (mascara), sinks, hot tubs, and even distilled water. CL wearers seem to be at the greatest risk. It's also a good idea to emphasize to your CL patients they should leave their empty CL case open and on the counter so it dries out and gets some sunlight. Remember, *pseudomonas* likes warm, dark, moist places. Closing a wet CL case and putting it back up in the bathroom cabinet provides just that environment. Not a good move!

To treat bacterial conjunctivitis, use topical antibiotics (ointment or drops); it usually resolves within one to two weeks.

## Viruses

Viruses are extremely small organisms. Without an electron microscope, you cannot see them. They are really quite fragile outside a living host and die very quickly in air. Inside a living host however, they are hard to kill and cures for them are very difficult to find. They are also very destructive until they have run their course or are wiped out by one of those rare drugs actually having some effect on them. Some of the more common viruses you may come across as an ophthalmic technician are the herpes simplex and zoster viruses (HSV and HZV), adenovirus (ADV), and human immunodeficiency virus (HIV).

The symptoms of a viral conjunctivitis are moderate redness (pinkness), watery discharge, and a swollen, tender preauricular node (in front of the ear) on the affected side. There is usually a history of a recent viral illness (cold, flu, etc.). Viral conjunctivitis is not generally itchy.

Treatment consists of alleviating the symptoms and making the patient comfortable until the body fights off the virus. Cold compresses to the eyelids can also bring some relief. There is currently no medication to fight viral conjunctivitis; however, some doctors may prescribe an antibiotic to fight any bacteria that might also be present.

## Herpes Simplex Virus

HSV recurrently infects the cornea and produces branch-like ulcers (dendritic keratitis). HSV is the most common viral eye infection. Approximately 500,000 cases of HSV-type infections are treated annually.

Once herpes is acquired, a person always has it. It just fluctuates between being active or dormant. There are two classes of HSV:

- HSV-1 is associated mainly with lesions above the waist.
- HSV-2 is found primarily in and on the genitalia and surrounding areas.

It's not impossible to have HSV-2 in the eye, but it's pretty rare. Virtually all HSV involving the eye is the type-1 virus.

When the eye is infected with HSV-1, the cornea becomes very insensitive. You can touch it with a Q-tip, and the patient doesn't feel it because the virus affects the ophthalmic portion of the trigeminal (5th cranial) nerve.

So a patient having this infection could have dendritic, branch-like lesions growing on and in the cornea (see fig. 2-17), but may not feel much pain since the virus affects the nerve. Because of the infection, the cornea may also become inflamed (keratitis) and vision can be affected before the patient actually knows anything is wrong. Once vision is affected, treatment is way overdue.

Sometimes, the dendritic keratitis progresses into larger, irregularly shaped ulcers. These ulcers can lead to central, gray deposits forming in the stroma, known as disciform keratitis.

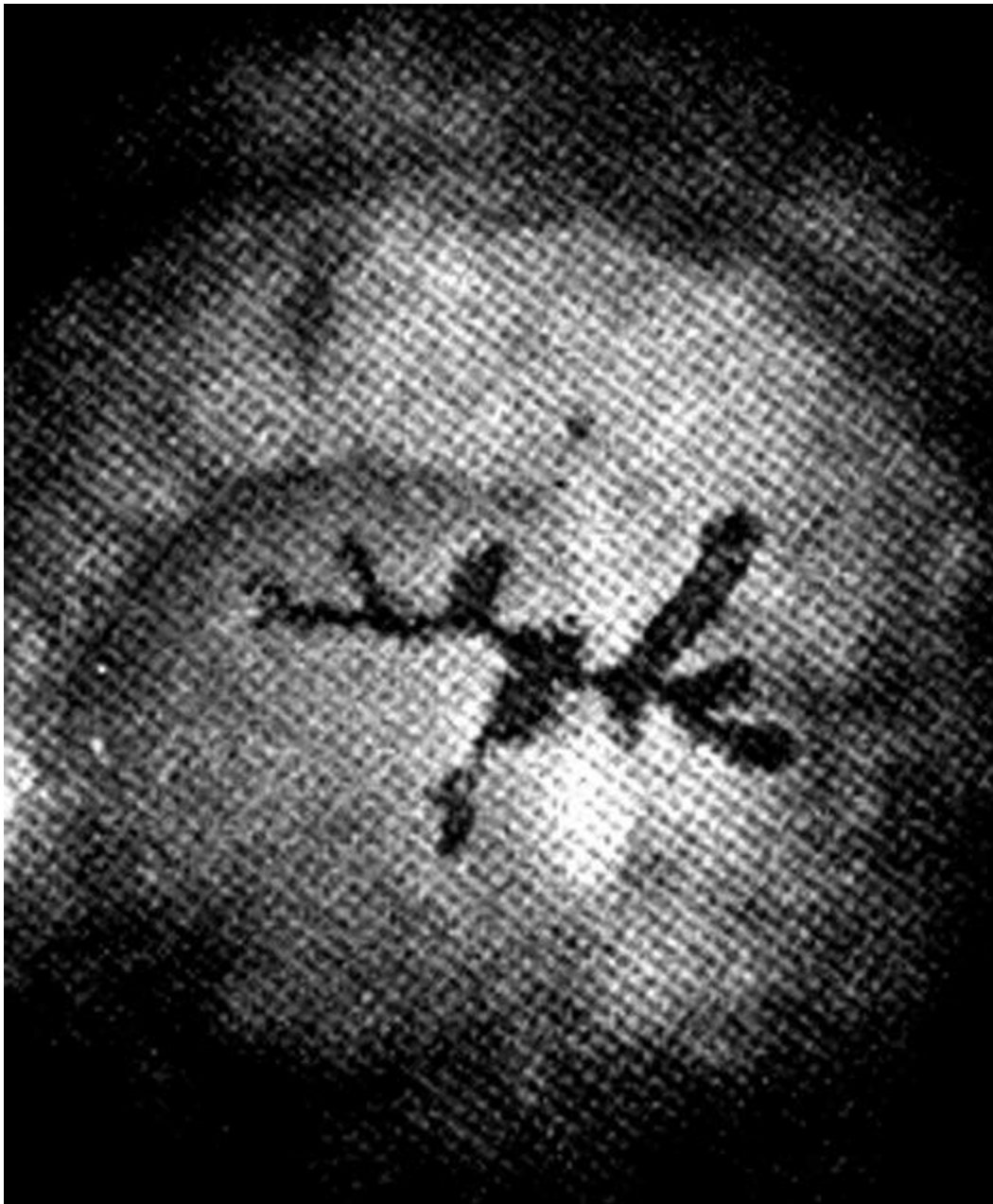


Figure 2-17. Dendrite on/in the cornea due to herpes simplex virus.

---

## Herpes Simplex Virus

In most cases, the clinical diagnosis of HSV is readily apparent, and a scraping and culturing of the eye is unnecessary. The presence of the HSV often leads to corneal scarring as the virus is damaging the cornea below the epithelial layer. Remember, any damage to the cornea below the epithelium leaves a scar. This is definitely not good for the patient's future vision.

Fortunately, HSV can be treated, though not cured, with antiviral medications. The sooner the HSV is treated, the higher the probability that growth of dendrites into the visual axis of the eye can be prevented. If an iritis is present, treatment can include dilation of the eyes. This improves the patient's comfort level. Unfortunately, as with most viruses, it essentially must run its course, as medication is not available to eradicate this disease-causing virus.

## Herpes Zoster Virus

HZV is the same virus that causes chicken pox--the varicella virus. HZV usually manifests itself with pain in the upper eyelid extending up beyond the brow through the forehead region. After the pain, the skin surface becomes swollen, red, and blistered. After the skin is healed, it often has pitted scars and is less sensitive (fig. 2-18).

HZV may occur in four sites that are supplied by the trigeminal nerve:

- Maxillary nerve
- Mandibular nerve
- Ophthalmic nerve (where it is most common)
- Upper lid, forehead, and superior conjunctiva

If the tip of the nose has blistering, there is a 50 percent chance of ocular involvement. Ocular conditions can include the following:

- Iritis
- Corneal ulcers
- Secondary glaucoma

Acyclovir medication has shown to be effective in shortening the course of HZV.

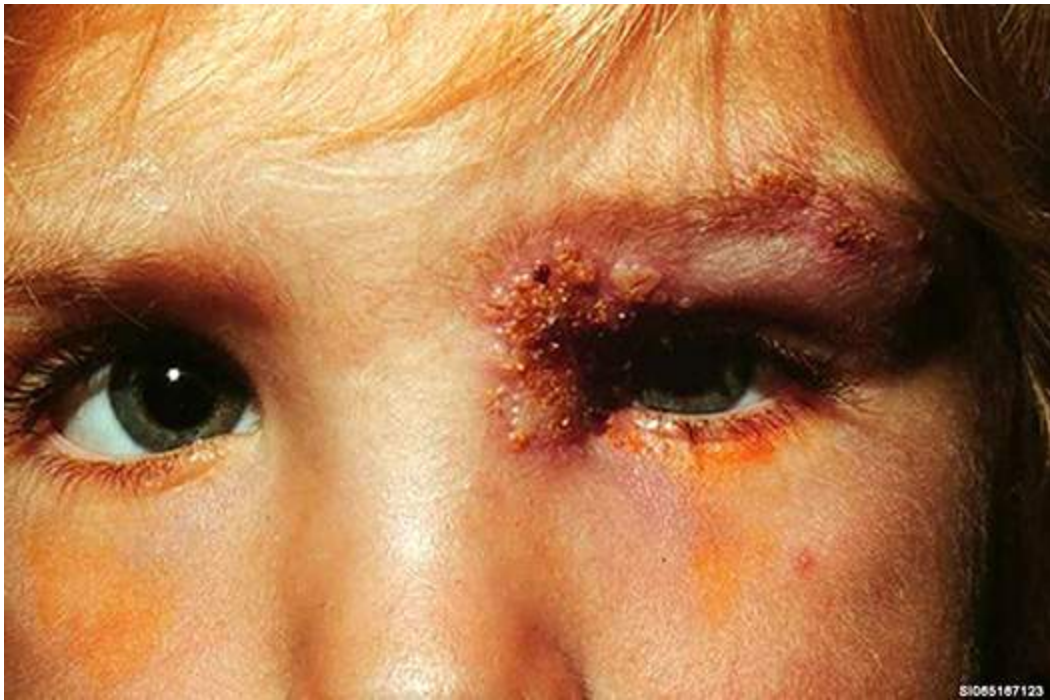

Figure 2–18. Blistering due to herpes zoster virus. Figure 2–18. Blistering due to herpes zoster virus.

---

## Adenovirus

ADV is really a family of 37 different viruses. Of the 37 types, only about a dozen have been linked to causing disease in humans (e.g., upper respiratory infections and inflammation of mucous membranes). Of this dozen, only seven cause eye infections, mostly conjunctivitis. This means there are seven different viruses leading to eye problems requiring an exam and possible treatment by you and your doctor.

ADV is quite contagious for 10–12 days. Instruct patients to wash their hands frequently and avoid rubbing their eyes; avoid close contact with others, and do not share towels with others. To prevent the spread of the virus, if possible, take a temporary leave of absence for infected patients who work with the public.

If a patient comes to your clinic with an ADV, use alcohol to wipe down everything the patient may have touched (e.g., chairs, tables, instruments, counters, etc.). If available, a 10 percent bleach solution is even better than alcohol for cleaning. You definitely do not want the ADV to spread to others. Two of the most common ADVs you'll come across are epidemic keratoconjunctivitis (EKC) and pharyngoconjunctival fever (PCF).

## Epidemic Keratoconjunctivitis

EKC is a significant type of viral conjunctivitis. This ADV is highly contagious, and causes the eye or eyes to be extremely red and produce profuse amounts of watery discharge. Conjunctiva and corneal involvements are the main characterizations.

EKC is associated with ADV types 8 and 19. It usually affects one eye, but is transferred to the other eye by the patient's hands, washcloth, or similar means. The conjunctivitis lasts seven to 14 days, with symptoms such as slightly elevated lesions on the cornea and the development of small corneal opacities. Small follicles (pus-like bumps in the palpebral conjunctiva) develop. The conjunctiva usually takes on a very bloody appearance. The redness of the eye and watery discharge are good signs of EKC.

In children, this virus can create systemic illness, while adults generally only experience eye problems. Resolution usually occurs within one to two weeks, but leaves visually impairing infiltrates (abnormal accumulation of cells and fluid) in the cornea. Recovery time is between six to eight months.

***NOTE:** The epidemic part of EKC is very real. By the time the doctor says, "The last patient had EKC; we need to wipe everything down," you probably have checked in several more patients, and you sure don't want them to be in a week later with EKC, too. It's contagious, so keep washing your hands and wiping off your equipment after every patient contact. This way, when the one patient actually infected comes through, you won't have as much to worry about because you habitually wash your hands and wipe off equipment after every patient anyway. Asepsis is important at all times, but is especially critical with an EKC patient.*

## Pharyngoconjunctival Fever

PCF is associated with ADV type 3. Patients with this virus have pharyngitis (sore throat), fever, and follicular conjunctivitis. This condition is usually unilateral (in one eye) and runs a course of 5–14 days. The keratitis produced is similar to EKC, but is usually milder.

Since PCF is associated with ADV we'll discuss how to treat ADV. ADV treatment is nothing more than letting the infection run its course. Antivirals have proven ineffective in treating this virus. Doctors often prescribe an antibiotic to prevent secondary infection by bacteria and placate the patients by giving them something to stick in their eyes so they feel as if they are "taking action" to help their condition.

Steroids can reduce the development of infiltrates below the epithelium of the cornea, but they just show up later when the steroid is discontinued. Artificial tears can help to dilute the viral load and provide comfort to the patient.

## Human Immunodeficiency Virus-1

HIV leads to acquired immunodeficiency syndrome (AIDS). HIV-1 is a retrovirus attacking the immune system by infecting and depleting the body of its T4 helper lymphocytes. Once these lymphocytes have been depleted, a number of various opportunistic infections can freely infect the body. HIV incapacitates the body's ability to fight off normal, everyday infections.

Eyes are involved in 30 percent of AIDS cases. Of those, 60 percent of the eye cases involve ocular lesions, most of those being follicular conjunctivitis and Kaposi's sarcoma. Kaposi's sarcoma is a deep purple-reddish soft malignant tumor of the conjunctiva.

Additionally, virtually all cases of HIV where the eye is affected involve the chorioretinal tissue--specifically, a condition called cytomegalovirus retinitis, causing retinitis and vasculitis with lesions destroying normal retinal and choroidal tissue (fig. 2-19). Retinal detachment may also occur.

This infection, caused by the condition cytomegalovirus retinitis, is called cytomegalic inclusion (CMI) disease, which is a grave sign when found. Involvement of the optic nerve results in optic disk edema (swelling) and severe, irreversible visual loss. Currently, the treatment of choice is a drug called Gancyclovir. This drug is virostatic, which means it prevents the virus from reproducing. So it doesn't kill the virus (as a viricidal drug would), it prevents the virus from reproducing more of the virus.

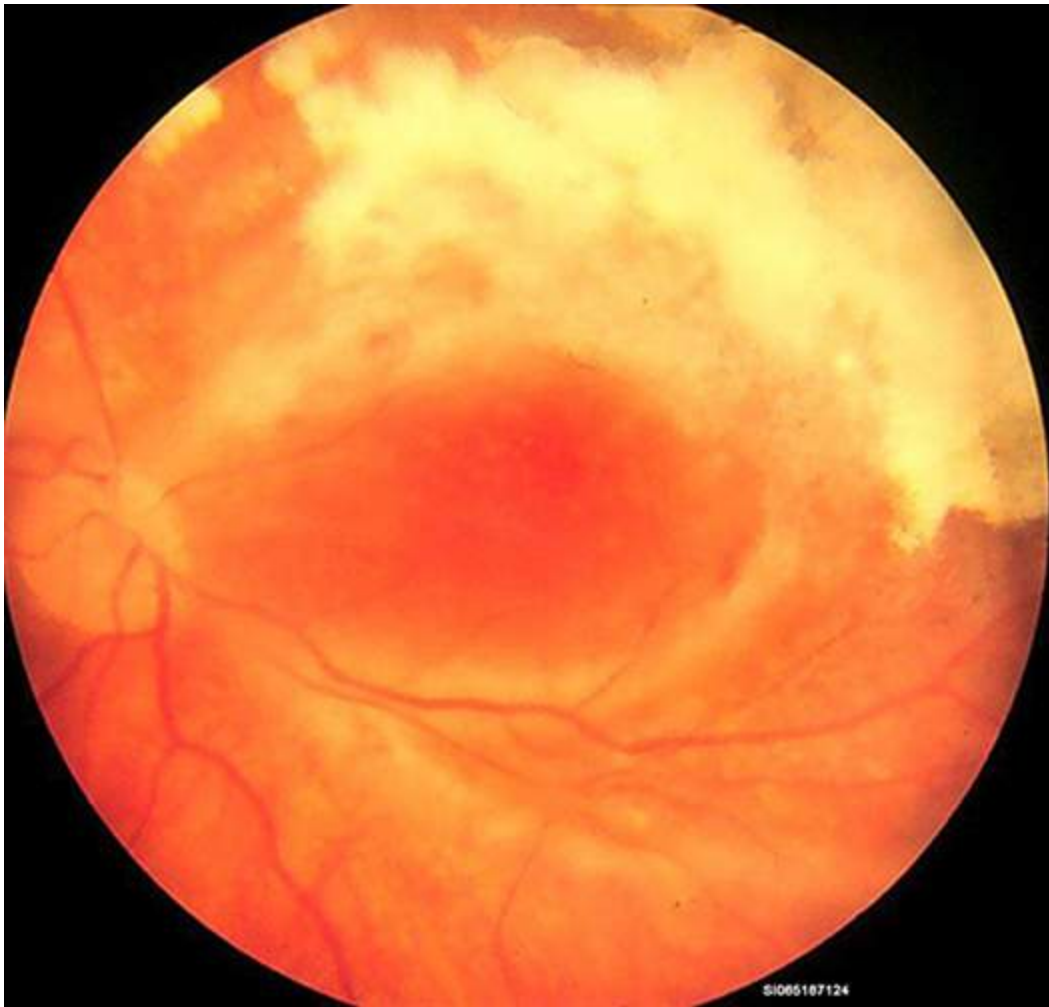

Figure 2–19. Cytomegalovirus retinitis.

## Transmission

Although the HIV virus is in all body fluids of infected individuals, there are no known cases of it spreading by casual contact; however, because it's found in tears, conjunctival cells, and blood, healthcare personnel must take reasonable precautions when treating patients and handling infectious waste, or when at risk of contact with body fluids.

According to The Federal Register, there is no evidence of transmitting HIV by shaking hands or talking; sharing food, eating utensils, plates, drinking glasses or towels; sharing the same house or household facilities; or personal interactions among family members, including hugging and kissing on the cheek or lips. Other studies referenced in The Federal Register have shown mosquitoes or other insects do not transmit



HIV. HIV is only transmitted by exposure to blood, its components, (e.g., during pregnancy from an infected mother to the child) and sexual contact. Only two percent of HIV cases are related to a blood transfusion.

Healthcare personnel are at risk for occupational exposure to bloodborne pathogens including HIV. Although HIV transmission is possible in healthcare settings, it's extremely rare. Medical experts emphasize that the careful practice of infection control procedures, including universal precautions (i.e., using protective practices and personal protective equipment to prevent transmission of HIV and other bloodborne infections), protects patients as well as healthcare providers from possible HIV transmission in medical settings.

## Post Exposure

Usually following exposure to the HIV virus (six days to seven weeks), an infected person experiences flu-like symptoms lasting from two to four weeks, leading to the development of antibodies. After the development of antibodies, the individual may be asymptomatic for months or years, although he or she can still transmit the disease to others; therefore, a person infected with HIV may take years to manifest and develop AIDS-related diseases.

As a final note on this destructive HIV virus, you must remember to remain nonjudgmental in your attitude when caring for patients with HIV. It's extremely important you treat all patients with care, understanding, concern, and professionalism.

## Fungal Infections

In the three-level course, we often tell students to remember you get "fungal from the jungle" and there is a lot of truth to that saying. Fungi are any vegetable organisms in the mushrooms or mold class. Fungi tend to develop on plant matter and dirt, and they seem to prosper best in hot, humid environments. A fungus causes athlete's foot and ringworm. Molds are fungi. Penicillin was discovered on a moldy piece of bread, so they aren't all bad; however, let's face it; a fungus in the eye just doesn't seem like a great thing to have.

There are 75,000 different fungi. Realistically, there are only about three major ones--ocular histoplasmosis, aspergillus, and candidiasis--you're likely to come across in the clinic having ocular significance.

## Ocular Histoplasmosis

This fungus is usually introduced to the body in an interesting way--bird "poop." Birds, especially in the Midwest along the Ohio River Valley, carry histoplasmosis. They defecate on the ground or on your car, and their feces dry out and turn to dust. The dusty feces blow around until someone breathes it in. Now, it's in a warm moist environment--the lungs.

The fungus gets into the blood stream and cruises around the body like some renegade looking to cause damage. Unfortunately, the eyes are one of the places the fungi may decide to hang out and wreak its havoc. Ninety-eight percent of histoplasmosis infections are benign (dormant) and cause no symptoms. Only a very small percentage of people (two percent) living in the Midwest Ohio River Valley area ever get histo spots on their retinas (fig. 2-20). Studies have shown patients with histo (histoplasmosis) have spots bilaterally (in both eyes) in two-thirds of the patients. The spots are usually irregular, round, and deeply pigmented.

Of those with the histo spots, only a few experience problems. Problems happen when the histo fungus comes alive and decides it's time to eat through part of the retina. Everywhere the fungus goes it leaves scars. If it gets to the macula, central vision will be lost. Unfortunately, there is not a lot the doctor can do. Antifungals are ineffective. Zapping it with a laser only makes it worse. Steroids can reduce swelling in the macular, but not much else. It must be waited out in hope the body can fight it back into a dormant state again.

To confirm a retinal spot is from histoplasmosis, a chest X-ray can be done to see if there is evidence of histo damage in the lungs. This may or may not be conclusive. There is also a skin test available to verify the presence of histo. The problem with the skin test is, for some reason, it reactivates the histoplasmosis fungus. Once reactivated, it does more damage and spreads further. For a patient with a histo spot (lesion) near the macula, this reawakening could lead to blindness. Since the consequences of confirming the presence of the histoplasmosis through empirical means can be hazardous, most doctors just trust what they see and refer to the disease as presumed ocular histoplasmosis (POH).

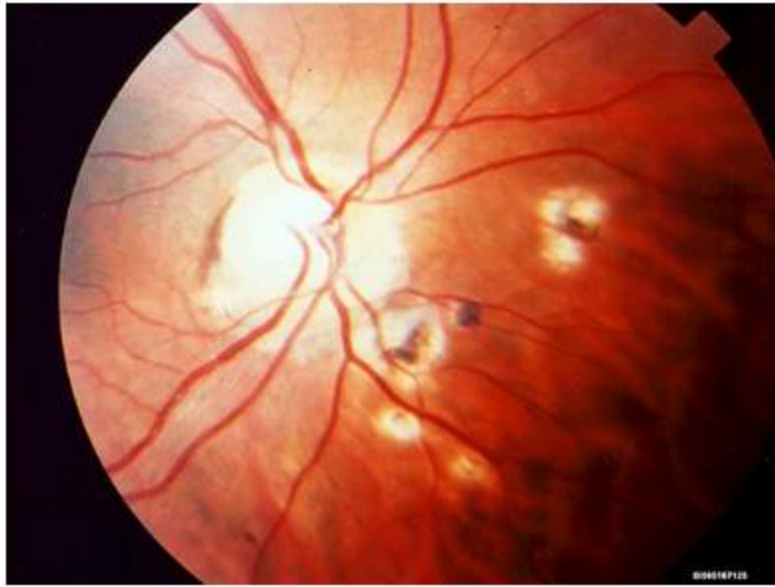


Figure 2-20. Ocular histoplasmosis.

## Aspergillus

This is a destructive fungus. Healthy people in tropical environments can acquire it, but it's more common in patients with a compromised immune system. Aspergillus is a fungus developing after getting a corneal abrasion by a twig, leaf, branch, or other plant matter. It's also found in drug addicts who use contaminated needles.

Aspergillus acquired via respiratory means (i.e., breathing it in) usually starts in the sinuses and evolves over months or even years. By the time a person notices something amiss, the fungus is well along. The fungus destroys the bone separating the sinuses from the ocular cavity, and then progresses rapidly to damage the eyes. Those who get it through a corneal abrasion see symptoms much quicker with keratitis, conjunctivitis, and infection in the conjunctival sac, canaliculi, lacrimal sac, and nasolacrimal duct.

Patients may develop proptosis, loss of vision, pain, and limited eye motility. Intraocular signs are vitritis (inflammation of the vitreous), "fluff balls," yellow-white retinal lesions, chorioretinitis, hemorrhages in the retina, and a pool of white blood cells sitting in the anterior chamber of the eye (a hypopyon).

Treatment consists of an intravenous (IV) administration of an antifungal medication, or even removing some of the infected vitreous to make room to inject the drug directly into the vitreous chamber. Orally, the patient can take an oral prednisone, and in select cases, oral itraconazole.

If these actions don't help, the eye may need to be removed entirely to prevent infection that is more widespread by the fungus and prevent additional infection by other opportunistic fungi, viruses, or bacteria.

## Candidiasis

Candidiasis is quite similar to aspergillus, but it doesn't seem to occur in healthy patients. It targets immunosuppressed and hospitalized patients who receive systemic antibiotics, especially those with an IV catheter. This fungus has been found in the ventilation ductwork of hospitals, so ironically, its located in close proximity to its victims. Intraocular findings are virtually identical to aspergillus and the treatment is the same.

Fungal infections, thankfully, are quite rare. They are highly destructive and tough to eradicate. The damage from fungal infections is often permanent, so a quick diagnose and aggressive treatment gives the patient the best visual outcome.

**Self-Test Questions. After you complete these questions pertaining to eye infections, you may check your answers at the end of this module.**

1. What do you call the organisms that cause disease in normally healthy tissue?

Type your answer here

SUBMIT

2. What are the general characterizations of conjunctivitis?

Type your answer here

---

SUBMIT

3. What term is used to describe the shape of bacteria?

Type your answer here

---

SUBMIT

4. What shapes do bacteria come in?

Type your answer here

---

SUBMIT

5. What type of gram stain is it if a bacteria cell wall stains blue?

Type your answer here

---

SUBMIT

6. What difference does it make whether a bacteria is gram-negative or gram-positive?

Type your answer here

---

SUBMIT

7. What bacteria is usually a harmless inhabitant of the eyelids and conjunctiva?

Type your answer here

---

SUBMIT

8. Which bacteria is usually found in the respiratory tract of people?

Type your answer here

---

SUBMIT

9. Which bacteria cause ophthalmia neonatorum (neonatal conjunctivitis)?

Type your answer here

---

SUBMIT

10. Which bacterium causes an acute, pus-producing conjunctivitis and is highly contagious?

Type your answer here

---

SUBMIT

11. What bacteria cause corneal melting and can grow in almost any moist environment?

Type your answer here

---

SUBMIT



12. What are the more common viruses with which ophthalmic technicians should be familiar?

Type your answer here

---

SUBMIT

13. What is the most common cause of viral eye infections? What is the estimated average of infections treated yearly?

Type your answer here

---

SUBMIT

14. What happens to corneal sensitivity when an eye is infected with the HSV?  
Why?

Type your answer here

---

SUBMIT

15. Which virus causes dendritic, branch-like lesions?

Type your answer here

---

SUBMIT

16. What is the significance of the tip of the nose blistering when referring to HZV?

Type your answer here

---

SUBMIT

17. What is it that makes ADVs a cause for concern for you in the eye clinic?

Type your answer here

---

SUBMIT

18. What are some significant signs that a patient has EKC? What are its main characterizations?

Type your answer here

---

SUBMIT

19. Which virus causes a sore throat, fever, and follicular conjunctivitis?

Type your answer here

---

SUBMIT

20. What treatment is provided to counter the ADV?

Type your answer here

SUBMIT

21. HIV-1 is a retrovirus that attacks the immune system by doing what?

Type your answer here

SUBMIT

22. AIDS directly affects the eye in what percentage of AIDS patients?

Type your answer here

---

SUBMIT

23. What is the condition called when chorioretinal tissue is involved due to an HIV infection?

Type your answer here

---

SUBMIT

24. How is HIV transmitted?

Type your answer here

---

SUBMIT

25. Where do fungi tend to develop?

Type your answer here

---

SUBMIT

26. How does an individual get histoplasmosis?

Type your answer here

---

SUBMIT

27. Why is a skin test to check a person for histoplasmosis a bad idea?

Type your answer here

---

SUBMIT

28. Which fungus may develop after a person gets a corneal abrasion by a twig, leaf, branch, or other plant matter?

Type your answer here

---

SUBMIT

29. How long does it take aspergillus to evolve if it has been acquired by breathing it in?

Type your answer here

---

SUBMIT

30. What drugs can be used to treat patients with the aspergillus fungus?

Type your answer here

SUBMIT

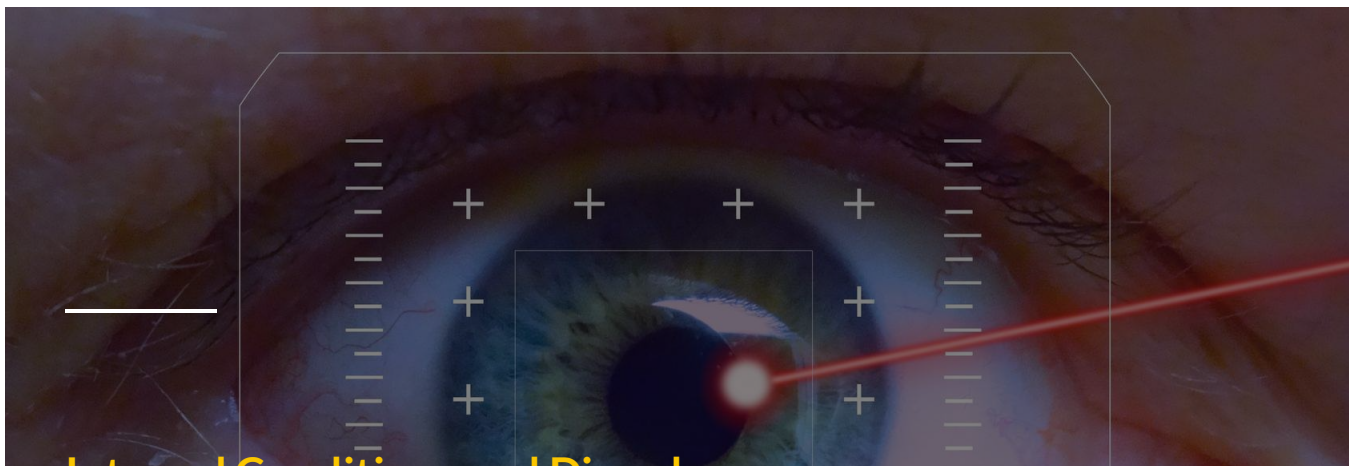
31. What makes candidiasis different from aspergillus?

Type your answer here

SUBMIT




Complete the knowledge check questions before moving forward in the lesson.





## Internal Conditions and Disorders



## Internal Conditions and Disorders

“I have this problem. Whenever I go outside, I get this sharp pain in my left eye. I thought it would go away, but it hasn’t. What do I do?” Have you ever gotten a call like this? What do you tell the person calling? What do you think is wrong? It sounds like an iritis, but you obviously need more information, and this is going to require you to ask some specific questions. You can’t ask the right questions if you know nothing about the various ocular disorders possible and the signs and symptoms of each. This section will assist in broadening your knowledge about some of the more common internal conditions that may very well come through your clinic.

Some of the information presented in this lesson may sound familiar, but much will be new. As you go through this section, ask your doctor or supervisor for clarification when needed. Most doctors really like to help their technicians with this kind of information because the more you know, the better you can assist them and the patients. You are truly an important piece in the ophthalmic team. Your doctor and patients are counting on you.

### Inflammatory Conditions and Disorders

Inflammation is defined as the protective response that begins when a foreign substance invades body tissues. The foreign substances can be many different things. Examples of foreign substances in body tissues follow:

- Fungi in the body (histoplasmosis)
- Viruses in the body (HSV and HZV)
- Injuries to the eye (any type of trauma)
- Parasites (toxoplasmosis and acanthamoeba)
- Systemic diseases (rheumatoid arthritis and ankylosing spondylitis)

As you can see, any number of things can create the environment in which an inflammatory response can develop.

## Uveitis

Uveitis is a general term referring to inflammation of the uveal tract. It can be divided into anterior uveitis (iritis/iridocyclitis), intermediate uveitis (pars planitis), and posterior or panuveitis (chorioretinitis). Uveitis can be caused by a blunt or chemical trauma to the eye, and various systemic disorders (toxoplasmosis, HSV, sarcoidosis, AIDS, ankylosing spondylitis, etc.); however, most of the time (80 percent), it happens spontaneously, generally without a known root cause.

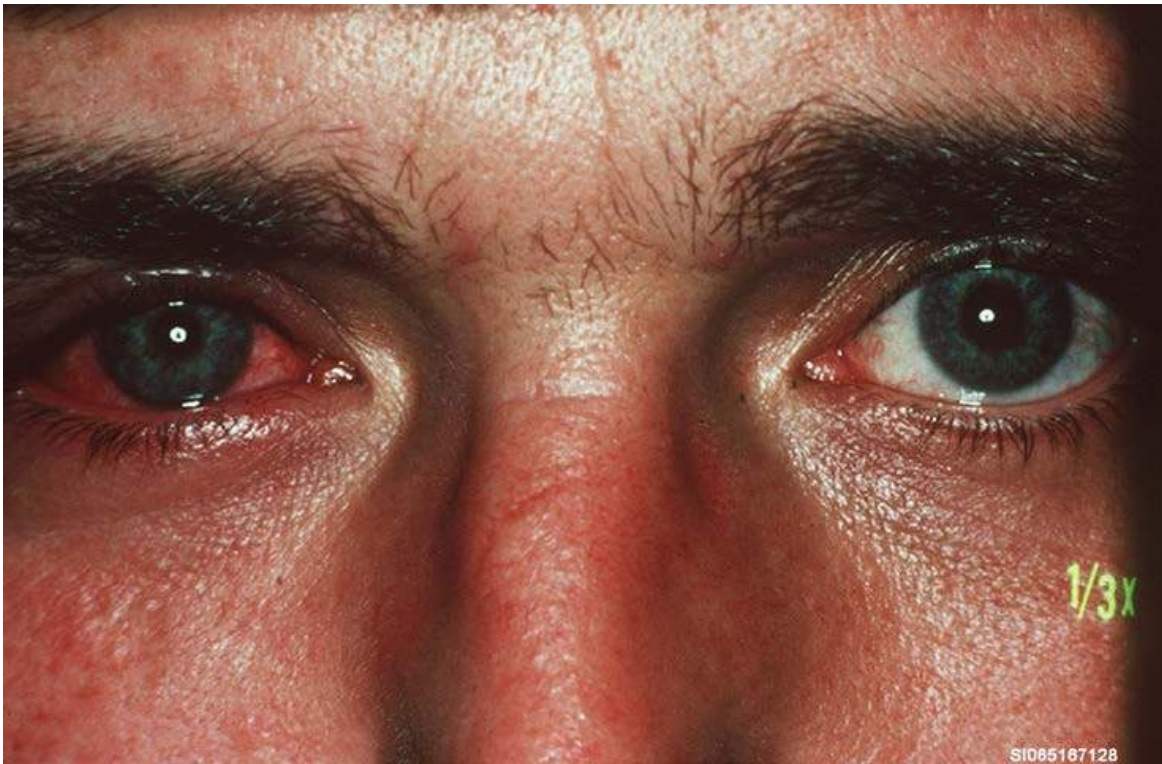IRITIS/IRIDOCYCLITIS (ANTERIO...	PARS PLANITIS (INTERMEDIATE U...	CHORIORETINITIS (POSTERIOR UV...
-------------------------------------	-------------------------------------	-------------------------------------

Iritis and iridocyclitis are considered an anterior uveitis, and they make up about 75 percent of all uveitis patients seen. Specifically, iritis is an inflamed iris, and iridocyclitis is an inflammation of the iris and ciliary body. If a person reports with an anterior uveitis and there is no history of trauma, a full laboratory workup is needed to rule out systemic disease.

The pain involved with iritis or iridocyclitis is a deep achy pain, as opposed to a FB external type of pain. Some classic signs and symptoms of an iritis/iridocyclitis are photophobia (light sensitivity), tearing, blurred vision, constricted or irregular pupil, and red eye with the injection (engorgement of the blood vessels) of the episclera most pronounced near the limbus (fig. 2-21).

A danger with anterior uveitis is a condition called synechia, which is when an inflamed iris comes in contact and adheres to the crystalline lens or cornea. If this occurs, an acute glaucoma attack is very likely.

Treatment consists of cycloplegia (dilation with paralysis of the ciliary body) to relieve ciliary spasm, and topical steroids to reduce inflammation. Duration of an acute anterior uveitis is usually fewer than six weeks, with a noted improvement generally within in a few days.



**IRITIS/IRIDOCYCLITIS  
(ANTERIO...**

**PARS PLANITIS (INTERMEDIATE  
U...**

**CHORIORETINITIS (POSTERIOR  
UV...**

This form of uveitis accounts for about eight percent of all uveitis cases seen. Remember, the pars plana is the posterior portion of the ciliary body; so, a pars planitis is an inflammation in this area. The inflammation leads to coalescence of debris in the lower part of the vitreous, giving the appearance of a snow bank or snowballs overlying the pars plana.

Symptoms can be blurred vision or floaters without pain or photophobia. Pars planitis can be minor, causing no symptoms, and then resolving spontaneously. Or, it can be quite serious; causing macular edema and significant decreases in vision. Treatment of the more serious cases involves a periocular injection of steroid next to the inflamed pars plana area.

**IRITIS/IRIDOCYCLITIS  
(ANTERIO...**

**PARS PLANITIS (INTERMEDIATE  
U...**

**CHORIORETINITIS (POSTERIOR  
UV...**

Posterior uveitis accounts for about 17 percent of uveitis cases. One of the more common types of inflammation involved with posterior uveitis is chorioretinitis (inflammation of the choroid and retina). Because of the close physical relationship of the choroid and retina, both structures are often involved in the inflammatory process.

Chorioretinitis often presents with little or no pain. Symptoms of chorioretinitis can include blurry vision, but usually not much else. This is not a great clue because many things can cause decreased visual acuity (VA). Since the inflammation is posterior, there usually is no redness or photophobia unless the posterior uveitis is accompanied by an anterior uveitis.

There may be several signs of chorioretinitis, but not anything visible without an ophthalmoscope, as most signs of chorioretinitis are in the vitreous and retina. The signs vary depending on the cause of the inflammation, but usually include changes to the retinal pigment epithelial layer and some white blood cells visible in the vitreous.

A systemic disease usually causes chorioretinitis, so treatment of the underlying disease is important if the posterior uveitis is to be resolved. A laboratory workup can help in determining the systemic cause. The use of steroids to reduce inflammation is helpful in trying to minimize the damage to the retina and choroid until the underlying systemic problem is resolved. The most common causes of posterior uveitis in the United States are Bechcet's disease, toxoplasmosis, and Vogt-Koyanagi-Harada disease.

## Optic Neuritis

Optic neuritis is a general term referring to inflammation of the optic nerve head. It can produce vision loss so severe that the patient has light perception only. Loss of vision is a key symptom of optic neuritis.

Anytime the optic nerve head becomes inflamed, it affects the patient's vision because all visual information passes through the nerve head.

Optic neuritis can be broken down into two categories that are more specific—papillitis and retrobulbar neuritis. Papillitis is a localized swelling at the nerve head and easily seen through ophthalmoscopy. Retrobulbar neuritis is an optic neuritis occurring behind the optic disk. Since the location is behind the disk; early optic nerve changes are not visible with the ophthalmoscope.

Most cases of optic neuritis are single events without complications. A common cause of optic neuritis is multiple sclerosis—a demyelinating disease. Myelin is a sheath surrounding the axons of nerves helping increase light message transmission.

Other causes of optic neuritis are infections of the meninges (membranes covering the brain and spinal cord), orbital tissues, and paranasal sinuses. Young women (mean age of 31) are more likely to get optic neuritis than men, and it's more likely to show up in only one eye (unilaterally). Bilateral occurrence in adults is rare, running around 23 percent. Conversely, children who get optic neuritis are more likely to have it bilaterally.

Specific signs and symptoms are unilateral vision loss (variable), pain with eye movement, central scotoma (blind spot), color vision defects, and pupillary defects. Pupillary testing usually reveals an afferent pupillary defect (APD), also called a positive Marcus Gunn (MG).

There is no proven treatment for optic neuritis; however, monitor optic neuritis closely for the following two reasons:

- To ensure it is optic neuritis and not a more chronic, systemic neurological problem or tumor.
- To ensure the neuritis is clearing up properly. Generally, dramatic improvement in vision occurs within two to six weeks.

If no resolution has occurred after approximately eight months, a neurologist should treat the patient. Most cases of optic neuritis begin to show some visual improvement within a month, and roughly 50 percent of patients recover normal VA within seven months. The longest documented case of vision recovery after an optic neuritis is two years; so even if a patient has not recovered VA entirely by the seventh month, there is still hope.

Recurrent cases of optic neuritis usually indicate the need for a full medical and neurological evaluation to rule out multiple sclerosis, which shows up in about 50 percent of adult patients after their first episode of optic neuritis.



## Systemic Medical Conditions With Ocular Disorders

A complication of internal disorders is that treatment can be more difficult. The problem areas are not easily accessible, and therefore, medication cannot be administered directly to the problem. Additionally, surgical intervention becomes much more difficult and risky when the globe of the eye must be penetrated to fix an internal ocular condition.

The retina of the eye is very dependent on the blood flow it receives. Anything interrupting this blood flow has the capability of creating significant retinal health problems for your patients. The systemic problems of diabetes and HTN are two diseases severely impairing the visual system by hindering the blood flow to the retina.

This lesson just skims the surface of the more common internal ocular conditions and disorders that are possible. There are literally thousands more, but many are variations or subcategories of problems discussed here. Learning about these conditions and disorders gives you an opportunity to understand what causes certain disorders, and how to treat them. Knowledge is power, and the more power you have when it comes to eye problems, the more valuable you become.

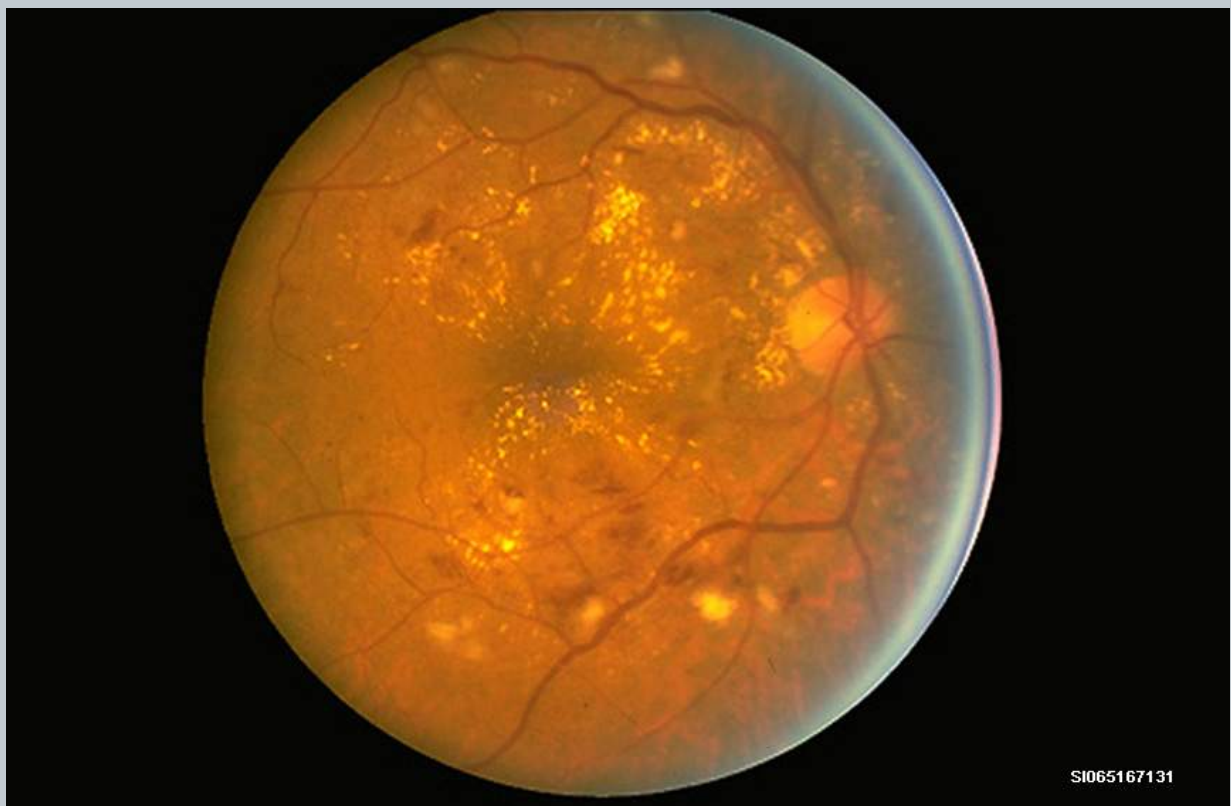

Figure 2–22. Diabetic retinopathy.



# Diabetic Retinopathy

Diabetic retinopathy (DR) is considered the leading cause of blindness in Western society. A chronic, elevated blood sugar level in diabetic patients is a key factor in the development of DR, supported by the fact that diabetics with well-controlled glucose levels have a lower incidence of DR. DR is broken into three distinct stages depending on the degree of severity (fig. 2-22).

Three Stages of Diabetic Retinopathy	
Stage	Description
1. Background DR	This is the earliest stage of DR. It's marked by microaneurysms (bulges in a blood vessel caused by weakening of the blood vessel walls), dot and blot hemorrhages, loss of capillary function, and lipid exudates (leakage from the vessels). If there is no significant edema (swelling) or identifiable leakage of blood (as shown by fluorescein angiography), and the patient's vision is not hindered, regular 6–12 month follow-ups with photo-documentation is appropriate treatment.
2. Proliferative DR	This is a significant stage because of the continued arterial and capillary weakening, which leads to increased lack of oxygen (hypoxia) for the retina. Due to its appearance, a common name for nerve layer infarcts is "cotton wool spots."  If visual field (VF) testing reveals field abnormalities, treatment should be started. Fluorescein angiography (FA) is an invaluable tool in determining abnormalities of the microvascular system caused by diabetic retinopathy. Use FA results as a guide during laser treatment.

Fig. 2-22. Three Stages of Diabetic Retinopathy

Three Stages of Diabetic Retinopathy	
Stage	Description
	Currently, treatment consists of pan retinal photocoagulation (PRP) in which laser spots are "shot gunned" onto the peripheral retina using an Argon laser. This essentially kills significant portions of the peripheral retina, reducing the retinal demand for oxygen. This spares the central vision area of the retina and allows the retinal vasculature to concentrate its oxygen flow to the central retina, which is now the only living remaining part of the retina.
3. Proliferative DR	This is a full-blown retinal disease. Like many organisms in the body, the retina responds to ischemia (deficiency of blood) in only one of two ways—it dies or finds a way to get more oxygen. Initially, the body fights hypoxia by developing new microvessels in the retina and dilating existing veins. As nifty as this may sound, the new microvessels tend to be poor duplications of the real thing and continue to develop microaneurysms leaking into the eye. The dilation of existing veins leads to substandard veins and the death of nerve fibers (infarction) in the retina.  As active neo-vascularization (new blood vessel growth) is taking place, these new, fragile vessels are breaking and bleeding into the retina and vitreous fluid. Additionally, growth of fibrous tissue also creates traction on the retina and can result in retinal detachments. At this point, it's imperative PRP be done to prevent severe vision loss or blindness.

Fig. 2-22. Three Stages of Diabetic Retinopathy

# Hypertensive Retinopathy

Uncontrolled HTN can also create significant problems for the vascular structures of the retina. HTN causes some of the same retinal problems found in DR.

In the eye, arteries cross over the top of the veins. If the arteries are under a great deal of pressure, they can press on a vein, and block it off. This leads to a branch retinal vein occlusion (BRVO), corresponding hemorrhage, and loss of vision in the area from which the vein was draining blood.

In addition to exudates in the macular area, cotton wool spots may exist. Normally, these findings are associated with patients having uncontrolled HTN. The appropriate treatment for this type of retinopathy is treating the underlying disease (high blood pressure, arteriosclerosis, etc.). Successful treatment of HTN generally leads to fewer problems and prevention of further retinal changes.

## **Conditions and Disorders Causing Sudden Vision Loss or Vision Degradation**

Vision impairment is always a serious problem. Several conditions can cause a sudden loss of vision, but there are only a few that cause vision degradation. The rate at which and how the vision was lost can be important clues to the exact problem. Some of the more common causes of sudden visual loss are central retinal artery occlusion (CRAO), central retinal vein occlusion (CRVO), and retinal detachment.



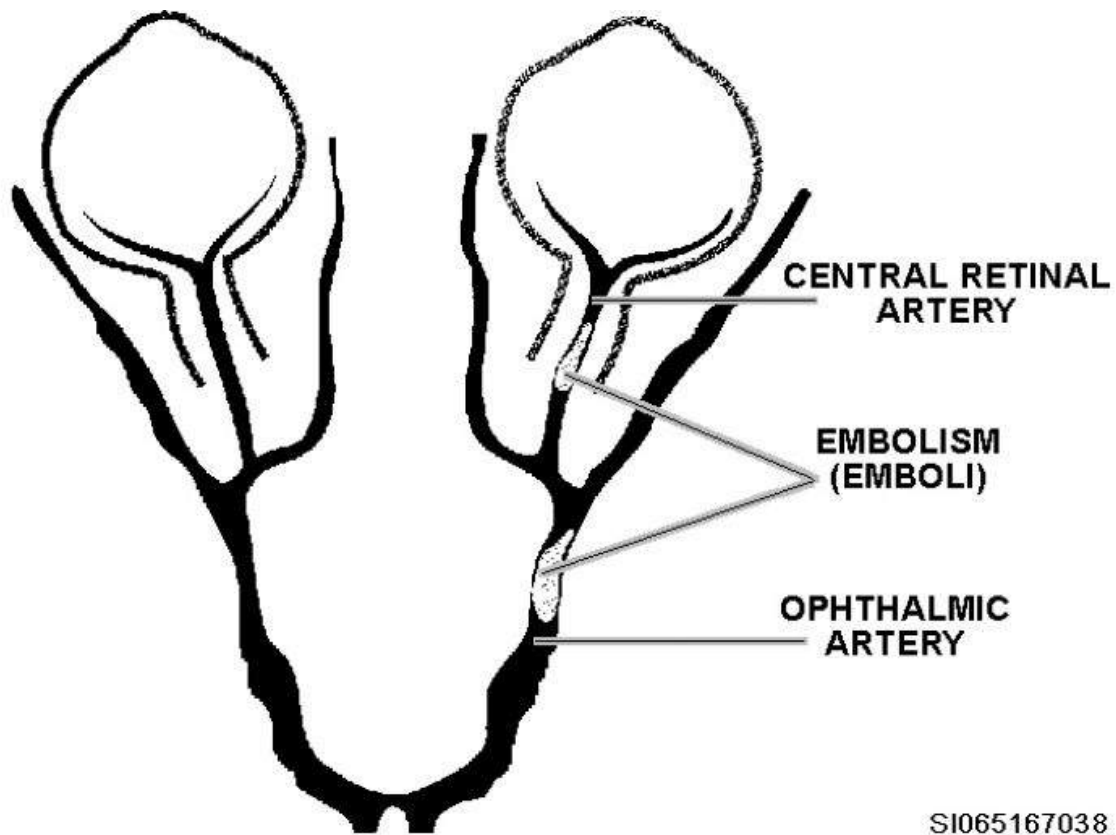


Figure 2-23. Diagram of central retinal artery occlusion.

## Central Retinal Artery Occlusion (CRAO)

A CRAO is just what it sounds like—a blockage of the central retinal artery (CRA) (fig. 2-23). A blockage results in an ocular catastrophe as this artery is the major supplier of fresh oxygen to the eye.

Arteries come from the heart and lungs, and bring oxygenated blood to the eye. If the main artery for the retina is blocked, the retina essentially suffocates from lack of oxygen and dies. This causes a rapid (within minutes), profound, and painless loss of vision.

The cause of CRAO is an embolus (blockage) of the CRA (fig. 2-24). The CRA is a branch of the ophthalmic artery before it branches off to supply the superior and inferior retinas with oxygen. If an embolus occurs before the branching of the artery, there is a total loss of vision.

Obviously, this is very serious, as permanent vision loss is almost certain. The best hope initially is to move the embolus out of the CRA and get it down one of the arterial branches. There can still be a loss of VF, but

not as severe as the total blindness occurring if the embolus remains in the CRA.

If a person calls with this complaint (total vision loss in one eye), one thing the person can try immediately is to bend over and get the blood to rush to the head. The hope is the increased blood pressure forces the embolus farther along into a branch of the CRA, allowing blood to get to at least some parts of the retina, thus minimizing the degree of visual loss.

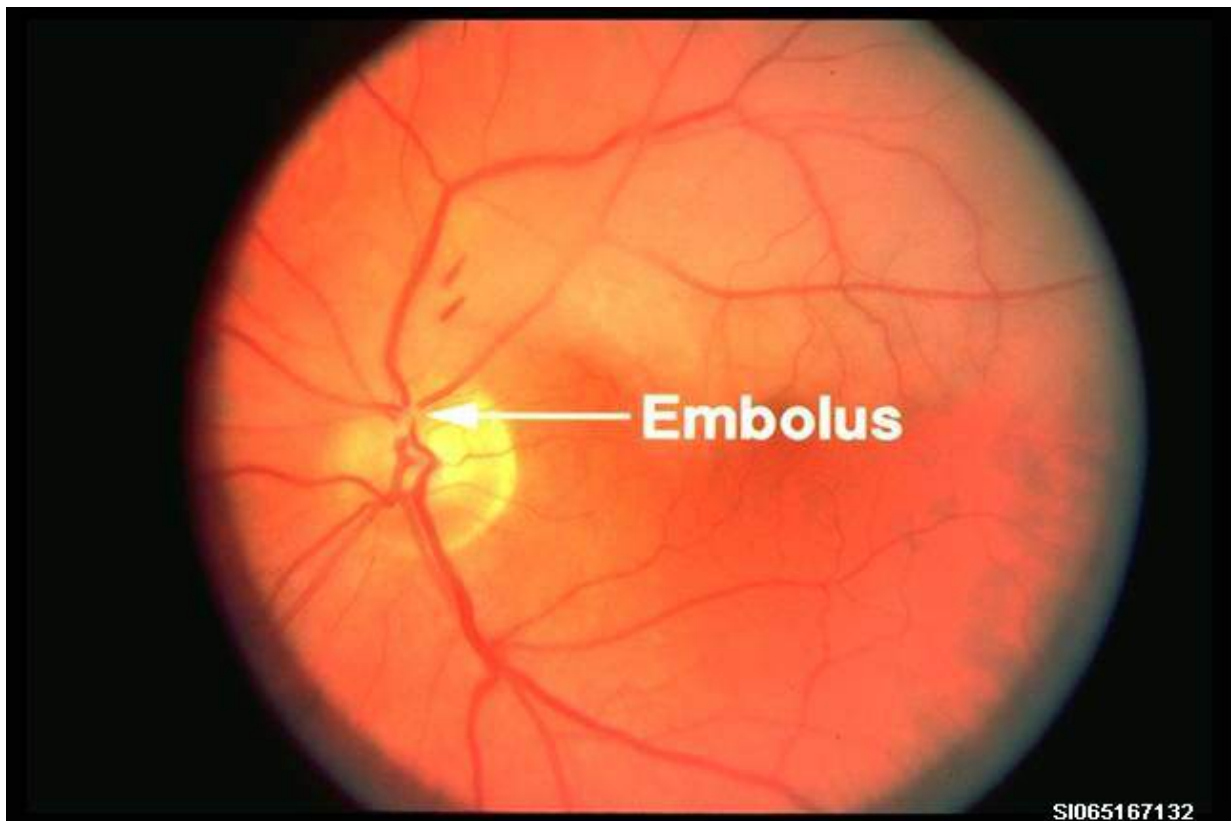


Figure 2–24. Embolism causing central retinal artery occlusion.

Another thing the patient can try is to begin breathing into a paper sack, like someone who is hyperventilating. This causes a person to breathe in more carbon dioxide, known as a vaso-dilator, which increases the size of the arteries. If you can get the CRA to dilate some, you can again hope the embolus moves out of the CRA and down one of the branches where its consequences are less disastrous.

A CRAO is a major problem with a poor prognosis. Some findings on retinal examination include opaque inner retinal layers, a cherry red macular spot (for about two weeks, and then it disappears), and markedly thin arteries because no blood is flowing through them.

When an embolus blocks one of the arterial branches, it's known as a branch retinal artery occlusion (BRAO). As tragic as the situation is, at least some vision may be saved. If the embolus occurs after the branching of the CRA, the visual loss may be in the form of a hemianopsia (one-half blind eye), quadrantanopsia (one-fourth blind eye), or a small isolated field defect, depending on the location of the blockage. In any case, the problem is serious and requires immediate attention.

## Central Retinal Vein Occlusion (CRVO)

A CRVO (fig. 2-25) is similar to an artery occlusion with a few exceptions. Veins are the vessels carrying blood back to the heart and lungs. They also drain blood from a structure.

If veins are blocked, fresh blood cannot pass through. If an area doesn't adequately drain, it will begin to suffocate from the lack of fresh blood flow. This is the reason the onset of visual loss is slower in a CRVO as compared to a CRAO. Total vision loss can occur over a period of 20 minutes to a few hours. If it's truly the central retinal vein (CRV) affected, the amount of VF loss is total. If the blockage occurs in a branch of the CRV, it's called a BRVO and only the area the branch of vein drains blood from is affected.

In CRV occlusions, vision sometimes comes back over the period of a few months. The extent of vision loss depends on the location of the thrombus (clot) (e.g., CRV or a branch vein). BRVOs are common in hypertensive patients. People with high blood pressure have arteries under a lot of pressure. These hardened arteries cross over veins that are not under much pressure, and the arteries can pinch off the vein they cross if the HTN gets bad enough. Usually, a doctor can detect the early signs through a simple dilated exam.

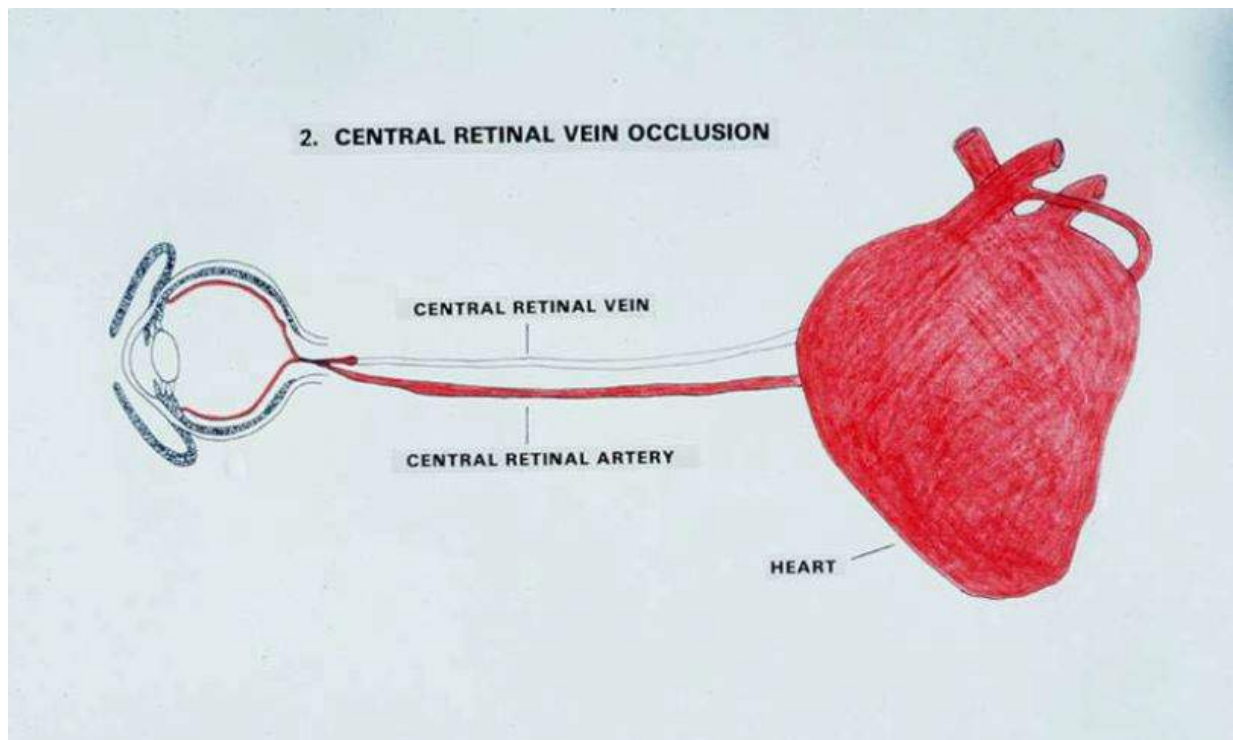


Figure 2-25. Diagram of central retinal vein occlusion.

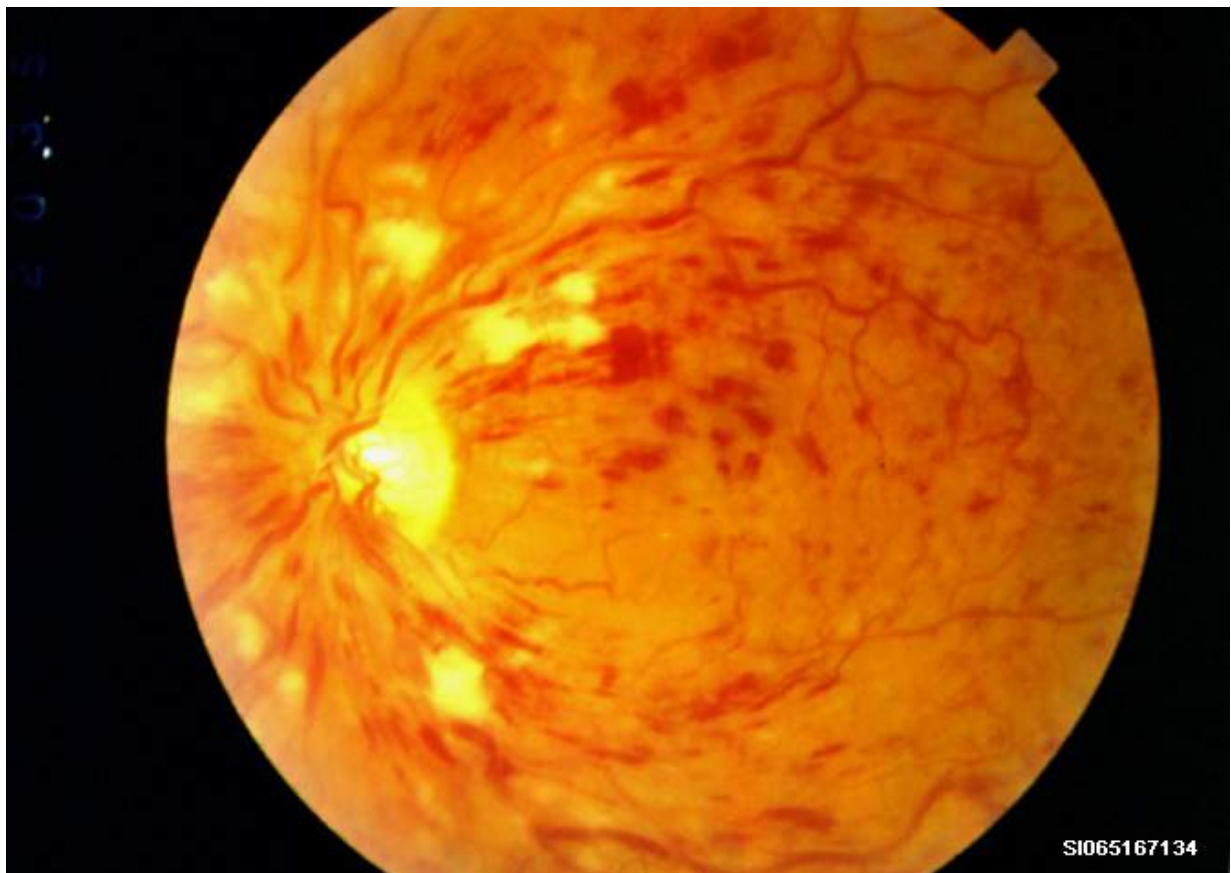


Figure 2–26. Picture of central retinal vein occlusion.

---

The doctor may see an artery appearing to be denting in a vein. Eye doctors term this as nicking, and usually refer the patients to their primary care manager (PCM) for treatment of the high blood pressure. Vision loss can be prevented if a patient with high blood pressure is identified and treated prior to an ocular artery fully closing off one of the veins.

If a CRVO does occur (fig. 2–26), some findings expected during a retinal exam include dilated and engorged veins (they are full and can't drain), intraretinal and nerve fiber layer hemorrhages, swollen optic disc margins, and retinal thickening.

## **Retinal Detachment (Nonmacular)**

Retinal detachments (fig. 2–27) usually begin with a retinal tear or hole. At some point, enough force is generated (by minor trauma, eye movement, etc.) to allow vitreous fluid to work its way through the tear and under the retina. As the detachment continues, more fluid flows in and the detachment worsens.

Some initial symptoms the patient may notice are flashes of light and an increase in the number of floaters in the affected eye. If the patient ignores those signs and the detachment progresses, the next noticeable occurrence is a loss of VF, usually the inferior field of view (as the superior retina is the most likely to detach due to gravity). The patient also may complain of seeing “curtains closing across their vision,” “the room going dark,” and other similar complaints.



Figure 2-27. Retinal detachment.

---



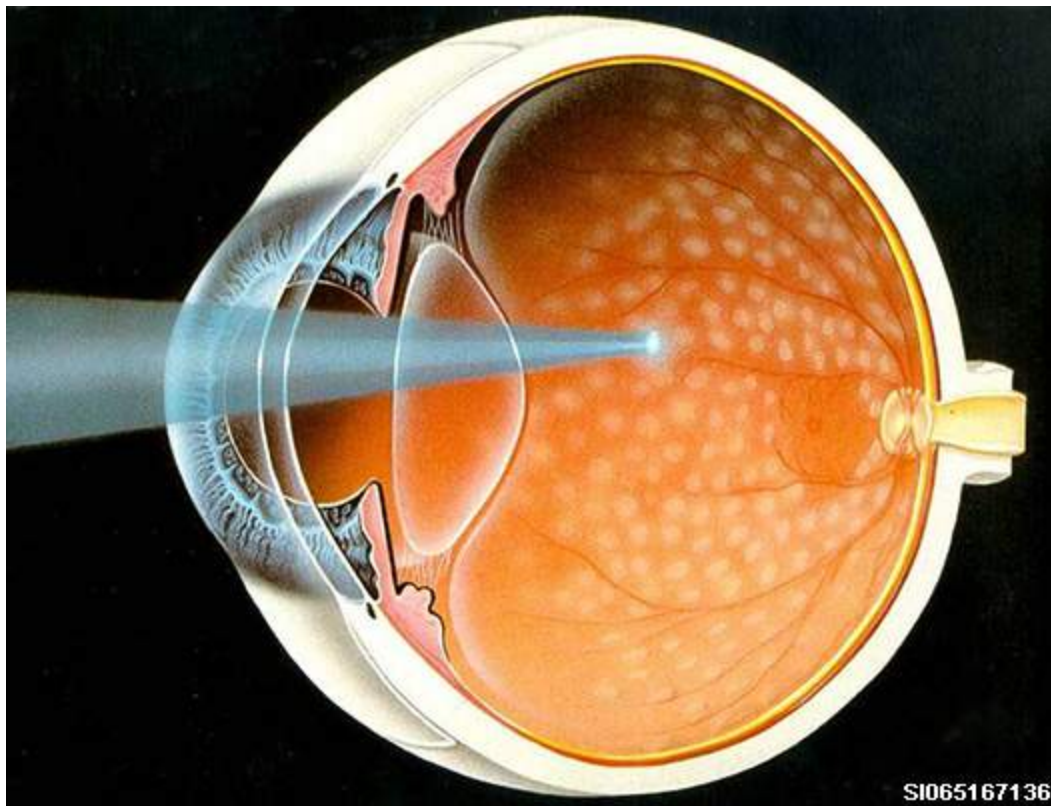


Figure 2-28. Retinal detachment repair via laser.

## Retinal Detachment (Nonmacular)

If the detachment progresses to the macula, central vision may be lost forever. Usually, retinal holes and tears are treated with an yttrium-aluminum-garnet (YAG) laser to tack down the retina (fig. 2- 28), or cryoprobe (freezing) surgery to freeze and scar the retina back into place.

Prior to performing cryo-treatment on a completely detached retina, the fluid behind the retina must be drained. Sometimes a scleral buckle is wrapped around the outside of the eye to squeeze it in to meet the retina. The goal is for the retina to reattach itself once it's back in contact with the choroid. If caught early and repair is initiated quickly, the prognosis for a retinal detachment is good.

## Vitreous Degeneration

Vitreous is the fluid occupying the rear two-thirds of the eye. Because light passes through this clear medium on the way to the retina, any change in the vitreous has the potential to affect vision. Two of the most common vitreous changes you may hear about from patients are floaters and flashes of light.

## Vitreous Floaters

Vitreous floaters are small opacities in the vitreous. Patients often describe them as being “little black spots,” “strings,” or “hairs” floating in front of their eyes. These vitreous anomalies are generally a function of aging or degeneration, and are not pathological in nature. Some floaters are remnants of the hyaloid artery present in the vitreous during our development in mom’s womb, or they can be from flecks of pigment that somehow got in the vitreous.

There is no treatment for floaters. People just need to learn to live with them. A sudden increase in the number of floaters may indicate a retinal tear or detachment. The extra floaters the person sees is pigment from the retinal pigment epithelial layer getting into the vitreous and requires immediate attention.

Patients’ symptoms range from mild (e.g., a flicker of light) to more noticeable (e.g., lightning streaks or flashes of light). Usually the patient states the flashes of light are coming from the periphery of their vision. These flashes of light are mostly caused by a buildup of debris in the vitreous fluid, which puts pressure on areas of the retina.

## Posterior Vitreous Detachment (PVD)

A posterior vitreous detachment (PVD) in itself is fairly harmless, but it could cause a retinal hole or tear as a buildup of debris in the vitreous causes it to pull away from the retina. This, in turn, could progress to a retinal detachment. A patient with a PVD needs to be examined periodically to ensure a hole or tear isn’t developing.

Brief a patient with a PVD to come in immediately if he or she notices a sudden increase in floaters, a veil-like obstruction in their vision, or a significant change in the amount or degree of flashing light. Take these symptoms seriously, for they could indicate a retinal hole, tear, or detachment.

Since the severity of the problem cannot be determined without an internal exam, the patient needs to see the doctor as quickly as possible. If an eye doctor is not readily available, get the patient to a family practice provider or to the emergency room (ER) where they can be referred to a local eye doctor if needed. This applies to any ocular emergency.

## Vitreous Hemorrhage



Hemorrhaging in the vitreous can lead to a sudden, painless loss of vision as blood filling the vitreous prevents light from reaching the retina. It can be caused by trauma or can happen with breakage of blood vessels in the retina caused by disease, like a CRVO, branch occlusion, and HTN.

Careful evaluation is required to determine the cause of bleeding and treatment of the problem. This is not easy, as the blood in the vitreous obscures vision for the doctor, as well as the patient, making diagnosis and treatment difficult. When the cause of the bleeding is stopped, the body will usually reabsorb the blood in the vitreous fluid over time.

## **Asteroid Hyalosis**

This is a condition in which tiny, opaque, calcium deposits are suspended in the vitreous fluid. Asteroid hyalosis is primarily a unilateral disorder typically occurring in patients over 60 and occurs in men twice as often as women. Usually asymptomatic, asteroid hyalosis can mildly affect VA in severe cases. Complaints of floaters are rare.

This anomaly is not dangerous to the patient, but provides an interesting experience for the examiner. Often, a doctor will ask you to take a picture to document the asteroid hyalosis, and it will be an interesting photo opportunity. It's interesting to look at it through a fundus camera, as it appears to be a bunch of little asteroids suspended in space.

## **Other Internal Conditions and Disorders**

Early detection and treatment can prevent a lot of blindness and vision impairment. There are surgeries, such as cataract removal, that can restore vision and are actually quite cost effective. The key to slowing down or stopping vision loss, for diseases such as glaucoma, is early detection and treat.

However, to slow down or stop vision loss, you must be aware of the signs and symptoms of these ocular conditions. The next lesson expounds on these and a few other internal ocular conditions that are important for you to know to better assist your patients.

## **Cataracts**

Cataracts are opacities or cloudiness of the crystalline lens. The opacity is generally caused by protein clumping and fibers swelling within the lens. This metabolic imbalance can be induced by eye disease, age, or trauma (mechanical or toxic), and can produce many different structures and progression rates. These

opacities are usually grouped into three categories: age-related, congenital, or acquired (trauma or disease).

Regardless of what caused the opacities in the lens, a cataract prevents the retina from getting a clear image of the world (fig. 2-29). An ophthalmologist removes a cataract when it impairs vision to the point where it prohibits normal day-to-day activities.



Blur

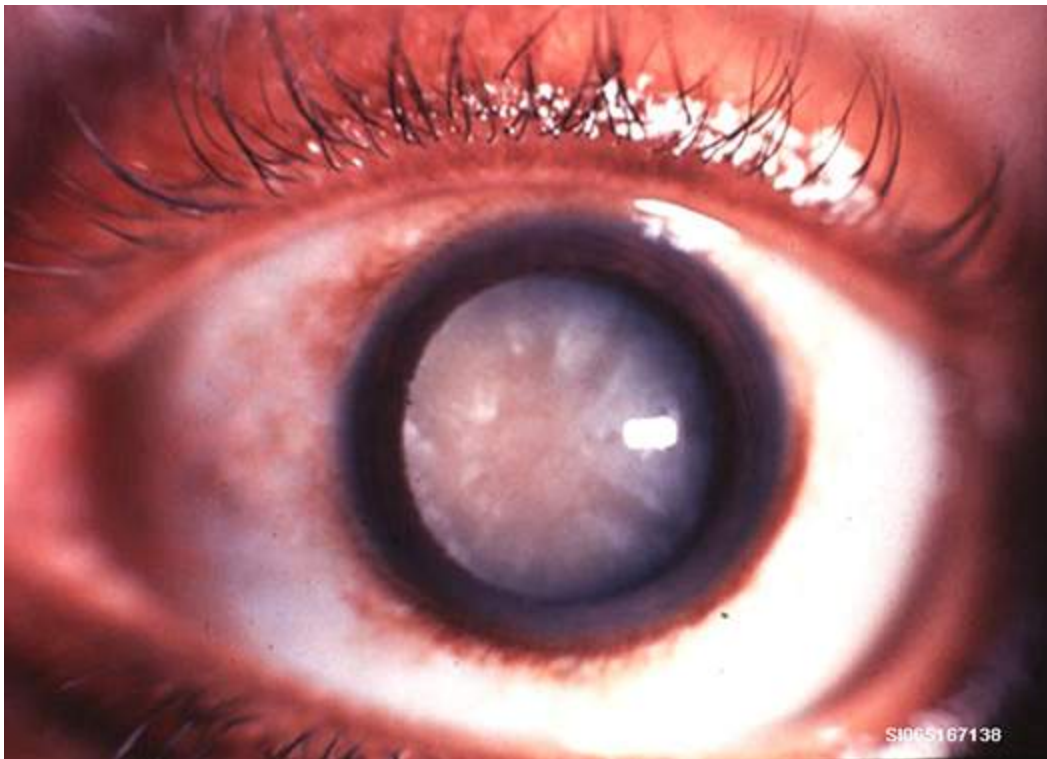

Glare



Distortion

S1005167137



S1005167138

Figure. 2-30. Mature cataract.

## Age-Related

This is by far the most common type of cataract. Based on statistics, if you live long enough, you'll develop cataracts. Research has shown about 10 percent of the American population under the age of 65 has

cataracts. Between the ages of 65 and 74, the percentage rises to 50. People over the age of 75 have an occurrence rate of about 70 percent. If you could find enough 100-year-old people to study, you would probably find an even higher percentage. Figure 2-30 shows what a mature cataract looks like.

There has been some evidence to indicate higher rates of cataract development in areas with long daily exposure to UV light (sunlight). Most of the cataracts you'll see in the clinic are age-related. They are usually called nuclear sclerotic cataracts, and are characterized by some faint whitish-gray clouding of the lens and an increased density at the center of the lens, causing it to thicken in the middle slightly. This gives the lens more power, focusing light sooner; thereby causing a myopic shift in vision.

A later-stage nuclear sclerotic cataract is sometimes referred to as being brunescent, meaning the lens is becoming slightly brown in appearance.

Posterior subcapsular (PSC) cataracts are a clouding on the rear surface of the crystalline lens. This is another type of senile cataract, but can also occur at any age after a chronic intraocular inflammation or prolonged steroid use. This type of cataract has the most profound effect on vision. Small changes in the size of the PSC cataract cause significant decreases in vision.

Cortical (spoke) cataracts occur when there are opacities in the lens forming a radial pattern following swelling and fragmentation of lens fibers. These cloudy segments form like the spokes in a wagon wheel.

Lamellar cataracts are formed by concentric thin layers (lamellae) of opacities surrounded by zones of a clear lens. Vision may still be good until the cataract matures more.

## **Congenital**

Like other congenital problems, congenital cataracts are formed during embryonic development in the mother's womb and are present at birth. This type of cataract may form in the periphery of the lens and not have a significant effect on vision. When the cataract is minor and doesn't create vision problems, regular follow-ups to check for progression is the appropriate course of action.

Unfortunately, some congenital cataracts involve the central portion of the lens and are dense enough to block vision. They require immediate surgical removal (usually within the first two months of life). If the cataract is not removed, amblyopia sets in because the retina and brain are deprived of visual stimulus.

The critical period for the development of sight is between birth and age 2. If a congenital cataract affecting vision remains during this critical period, the chances of the patient developing normal vision is very slim. Even with eventually removing the cataract, normal vision may not occur.

## Acquired


The most significant cause of cataracts outside of age and congenital causes is trauma. The most common cause of a traumatic cataract is a FB penetrating and actually impacting the lens, or causing blunt trauma to the eye without penetration. When a FB penetrates the lens, aqueous and vitreous fluid can enter the lens capsule. The lens fibers absorb the fluids, causing the fibers to swell and cloud the lens due to metabolic imbalances.

Blunt trauma sends a shock wave through the ocular structures and can trigger the beginning of a cataract in the lens. The cataract is developed from a swelling of lens fibers due to the shock wave in the eye. The swollen fibers cause clumping of the protein in the lens, making it cloudy. Even after enough healing time has passed since the traumatic event, the cloudiness does not go away. Once it's there, it's there.

Electrical shock or radiant energy (UV and infrared) overexposures are other traumas that can cause development of a cataract. Eye disease, systemic disease (i.e., diabetes), and some pharmaceutical products (e.g., steroids) can contribute to early cataract formation.

## Cataract Treatment

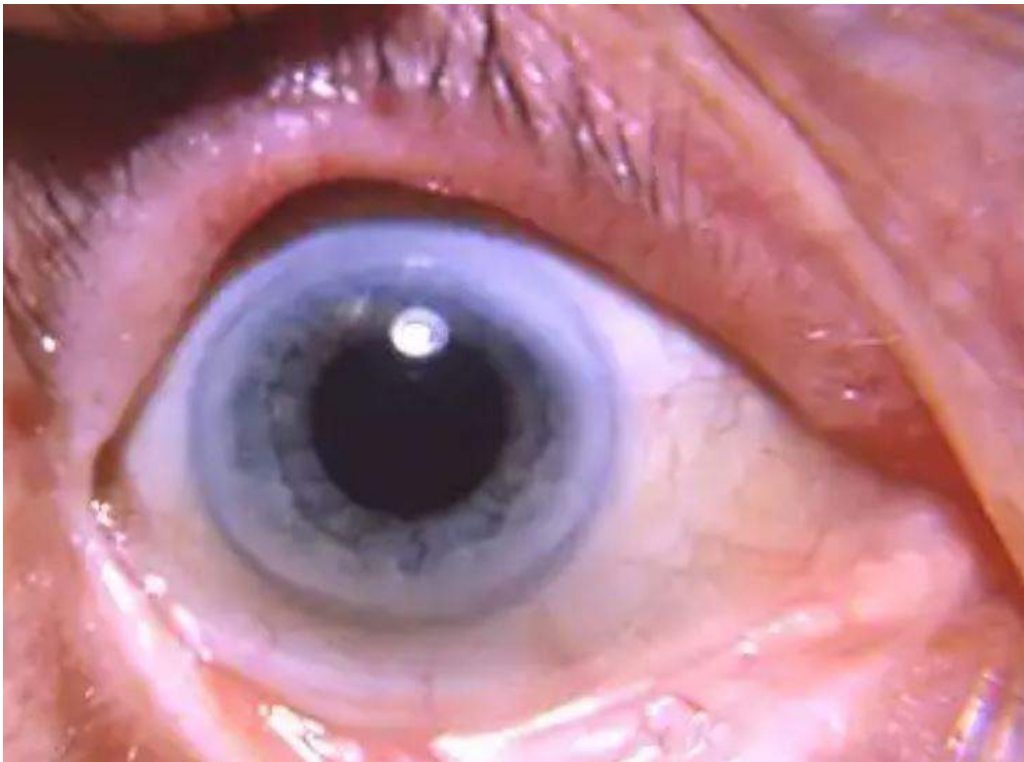
Cataract treatment is only considered when decreased vision creates a functional problem and warrants surgical removal; however, if the cataract is congenital, treatment is considered with almost any vision loss. Cataracts can be extracted in one of three ways--intracapsular, extracapsular, or phacoemulsification.



## Intracapsular

Intracapsular extraction surgery involves the removal of the entire lens as a whole. This means the capsule, cortex, and nucleus all come out. During surgery, a cryoprobe freezes the lens and then extracts it through an incision large enough for the entire lens to pass in one piece. Since it requires a large incision, you won't see this technique used much these days, as less traumatic procedures are available.

Since the entire lens is removed, the eye loses approximately +16.00D of power and must have the power replaced for the patient to see clearly again. An intraocular lens (IOL) can be inserted to replace the lost power. Since the capsule is also removed in an intracapsular extraction, the IOL must be placed in the anterior chamber of the eye between the cornea and the iris. This is not the preferred location due to the increased probability of iritis, but the only other options are CLs or thick spectacles.



## Extracapsular

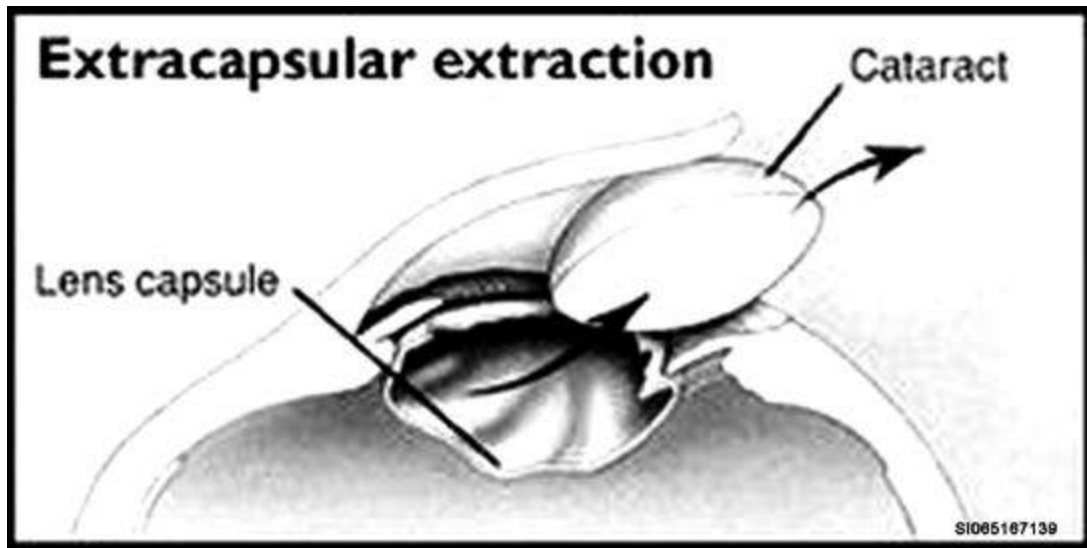
During an extracapsular extraction surgery, a round cookie-cutter-shaped hole is made in the front of the capsule. The cortex and nucleus are then forced out through the hole and removed (fig. 2-31).

The residue left behind is aspirated (sucked out), and the empty capsule is left intact. The capsule is still suspended in the eye by the Zonules of Zinn and acts as a compartment to hold an IOL. This type of IOL is



called a posterior chamber IOL because it's placed behind the iris and in the "bag" or capsule. This is the ideal scenario, as the IOL is placed in the exact location as the natural lens.

The IOL looks like an RGP CL, but with springy extensions attached to the edge called haptics. These haptics press against the inside diameter of the capsule and keep the IOL centered in the eye along the visual axis. When placed inside the capsule, there are fewer complications.



## Phacoemulsification

Phacoemulsification surgery is quite similar to extracapsular extraction surgery. A hole is cut in the front of the capsule, but instead of forcing out the cortex and nucleus as a whole, they are pulverized by ultrasound waves, and then aspirated or sucked out (fig. 2-32). This is less traumatic on the eye and allows a smaller incision to be made to remove the contents of the crystalline lens. As before, a posterior chamber IOL is inserted into the capsule to replace the lens.

To insert an IOL without having a large initial incision, many doctors use a lens inserter that folds the IOL like a taco (fig. 2-33). Once inserted into the capsule, the IOL automatically unfolds inside the "bag."

Since a folded IOL can pass through a much smaller incision, wound closure can be done without stitches, or at most, one stitch. This method of insertion helps the eye heal faster and reduces surgically induced astigmatism caused by sutures. Additionally, there is minimal trauma caused by phacoemulsification. Phacoemulsification is the preferred method of cataract extraction. It reduces the possibility of inflammation and infection, and the patient has a more comfortable experience during and after the surgery. Additionally, the patient's VA corrects in half the time of previous methods.

Cataract extraction and posterior chamber IOL insertion have become extremely quick and relatively easy procedures to perform. The patient usually leaves the hospital the same day of the surgery. When the natural crystalline lens of the eye is still present, a person is phakic (with lens). After removing the crystalline

lens and no IOL is placed in the eye, the person is aphakic (without lens). If the crystalline lens is removed and an IOL is inserted, the person is termed pseudophakic (false lens). You may hear these terms or see them in a medical record. It's valuable to know their meaning, as it tells you something about the person's ocular condition. While we're on the subject of IOLs, let's cover a note of caution--a person with an anterior chamber IOL should not be dilated by a technician without the explicit approval of a doctor.

Because there's a chance of complications, the doctor determines if it's safe to dilate a patient with an anterior IOL. You can easily tell if a patient has an anterior chamber IOL with a simple penlight. Shine the light in the person's eye. If you see a shimmering reflection just behind the cornea, you know the person has an anterior chamber IOL. You can actually see the lens.

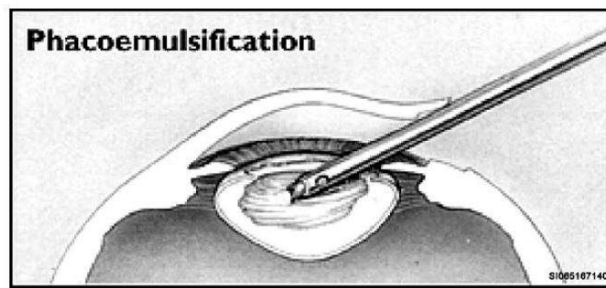


Figure 2-32. Phacoemulsification.

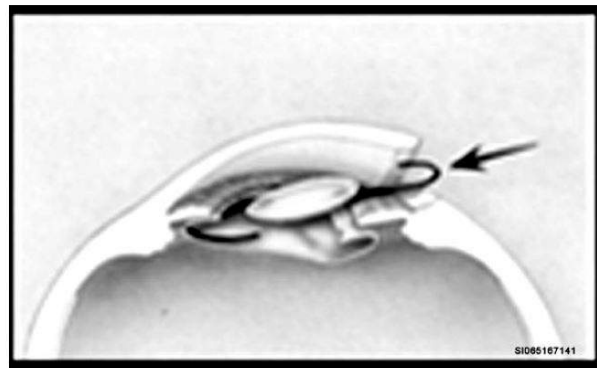


Figure 2-33. IOL implant.



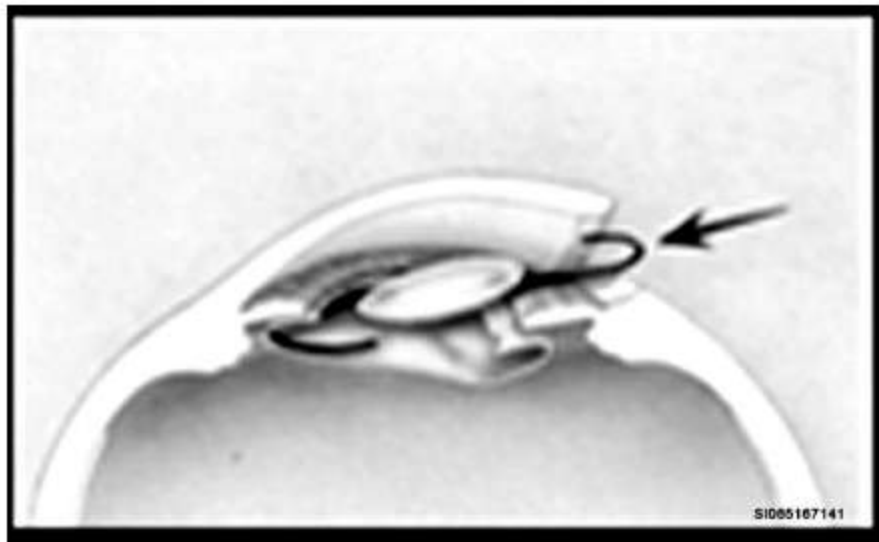


Figure 2-33. IOL implant.

## **Glaucoma**

Now it's time to look at glaucoma. It's estimated over two million people suffer from glaucoma in North America alone. More than half do not realize they have a problem, and as they age, the chances of complications rise.

Characteristics of glaucoma include elevated IOP, optic disk cupping, and VF loss. There are four general categories of glaucoma:

- Angle closure glaucoma (chronic angle closure and acute angle closure glaucoma)
- Open angle glaucoma
- Congenital glaucoma
- Secondary glaucoma

We also need to look at ocular HTN and ocular hypotension as they relate to glaucoma.

## **Angle-Closure Glaucoma**

This condition is marked with a rise in IOP caused by a mechanical blockage of the angle at the root of the iris. Vision is lost rapidly, the patient complains of excruciating pain, and the eye becomes extremely red.

Glaucoma takes on many forms, but angle-closure glaucoma is the most destructive and potentially harmful. Angle-closure glaucoma, also called acute angle closure or closed angle glaucoma, constitutes approximately 30 percent of all glaucoma cases. Patients with this disorder have essentially normal eyes, except for a shallow anterior chamber and a narrow entrance into the angle. The space between the iris and the cornea is narrower in these patients. The space where the aqueous humor must squeeze through to get to the canal of Schlemm to drain from the eye is smaller than usual. If the space (chamber angle) closes off, the aqueous cannot drain from the eye (fig. 2-34), causing an increase in the patient's IOP.

Since the ciliary process doesn't know there is a problem with the outflow, it continues to produce aqueous. The pressure in the eye rises since the outflow of aqueous is less than the production.

Dilation of the pupil causes the iris to fold like an accordion-type door, making it thicker as the iris tissue bunches up toward the base of the iris. This action can block the angle entirely, causing angle-closure glaucoma to occur. Some patient's eyes don't need to be completely dilated to block the angle; it's actually more prevalent in the mid-dilated position. This is the primary reason why you should always check the anterior chamber angles before dilating any patient.

Women tend to be more susceptible to angle-closure glaucoma than men are. Because of their anatomy, hyperopes are more likely than myopes to have narrow angles. People 40 and older are at a slightly greater risk than younger people are, as the crystalline lens swells with age, pushing the iris forward slightly and narrowing the angle more. Based on these facts, an older hyperopic female is the greatest risk category. Furthermore, if her mother or father also experienced this form of glaucoma, she is really in trouble, as there does seem to be a genetic predisposition.

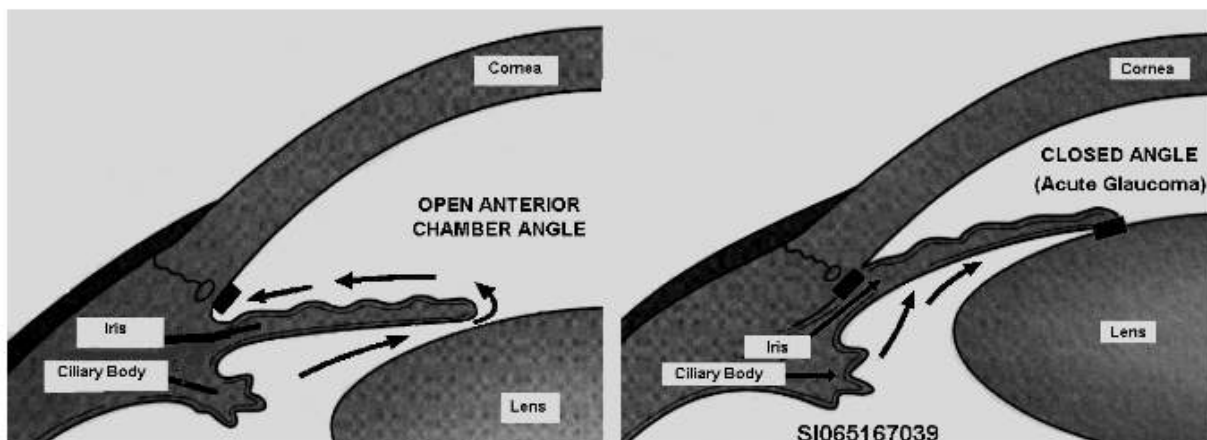


Figure 2-34. View of an open and closed anterior chamber angle.

---

Angle-closure glaucoma can fully develop within 30–60 minutes of the angle closing off and is an ocular emergency. Commonly, the attack begins under conditions leading to pupillary dilation (e.g., fear, emotional arousal, and darkness, which are factors causing the pupil to dilate).

Angle-closure glaucoma can occur with or without pupillary blockage. With pupillary blockage, the iris falls back toward the crystalline lens, and the pupil makes contact with the lens, blocking off drainage through the pupil. Pressure builds behind the iris in the posterior chamber and pushes the iris forward, blocking off the angle between the cornea and the iris in the anterior chamber. This bowing forward of the iris is called iris bombe. Even if the pupil is pushed away from the crystalline lens, it's too late, as the anterior chamber angle is now blocked off. IOP continues to build to incredibly harmful levels.

Angle closure without pupillary block happens when the aqueous flows from the posterior chamber to the anterior chamber through the pupil as usual. Problems arise when the iris is too far forward or it's folded up at its base (due to dilation). With the angle closed off, the fluid can't pass through and drain out of the canal of Schlemm, causing the IOP to build to extremely high levels.

The patient experiences pain as the pressure increases. Symptoms vary from a feeling of discomfort and fullness around the eye or eyes, to a severe, disabling pain radiating to the back of the head or down toward the teeth. With severe pain, the patient can become nauseated and may even vomit.

Usually, vision is reduced to a mere perception of light. The patient may see halos or rainbows around lights caused by the edema (swelling) of the cornea as it fills with fluid due to the excess pressure in the eye. The swollen cornea clouds slightly and begins to diffract the light entering the eye, thereby reducing vision. The pupil may be stuck at a mid-dilated point due to the iris adhering to the lens. More than likely, the patient also experiences photophobia.

So if an older, hyperopic female calls your clinic and states she sees halos around lights, her eye hurts and feels full, she is starting to feel nauseous, and bright light makes her feel worse, you can safely assume she is having an acute angle-closure glaucoma attack. Tell her to get a ride to the clinic immediately. Call for an ambulance to pick her up if a ride is not available, as patients in this condition should not drive. Acute angle-

closure glaucoma is sometimes difficult to handle as a technician because seeing a person in so much pain is very heart wrenching.

Patients with angle-closure glaucoma are usually treated with some combination of the following drugs: glycerin, Timoptic, Betoptic, Pilocarpine, Diamox, and Mannitol. Once the pressure has been lowered, many ophthalmologists do a laser iridotomy (fig. 2-35), which is essentially burning a hole in the periphery of the iris with a YAG laser. The iridotomy provides another avenue for the aqueous humor to get from the posterior chamber to the anterior chamber, and reduces the pressure (pushing forward) on the iris by the fluid behind it.

After completing the iridotomy on the affected eye, treatment for the unaffected eye is accomplished. Why do you treat the unaffected eye? Studies have shown that within five to 10 years of the initial attack, there is a 50 – 70 percent chance of the patient having another acute angle-closure attack in the other eye. Treating both eyes helps prevent this situation.

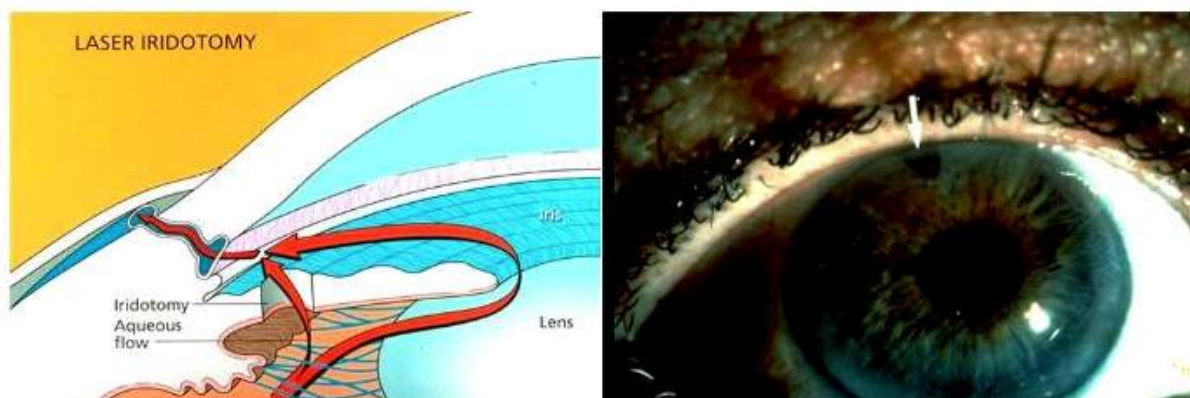


Figure 2-35. Iridotomy.

## Open-Angle Glaucoma

This type of glaucoma is not as easy to detect or diagnose, but it's visually threatening over time and is the most common type of glaucoma. Sometimes, you'll see it referred to as primary open-angle glaucoma (POAG) or chronic open-angle glaucoma (COAG). For the rest of this lesson, we will refer to it as COAG.

Approximately 0.5–2 percent of the population in the United States over the age of 40 have this progressive disease. As a competent technician, you should understand COAG, because you'll see many more patients with this type of glaucoma than the acute variety. Additionally, patients ask a lot of questions about it, and you need to be knowledgeable enough to answer their questions.

Unlike angle-closure glaucoma, in COAG, the angle between the iris and cornea is open; therefore, the increased IOP is not caused by a complete blockage of the angle, but rather by an obstruction of aqueous outflow through the trabecular meshwork. Reduced outflow, not overproduction of aqueous, is the main cause of COAG. This in turn, elevates the IOP in the eye, causing damage to the optic nerve as illustrated by the example of using water flow and a balloon in figure 2–36.

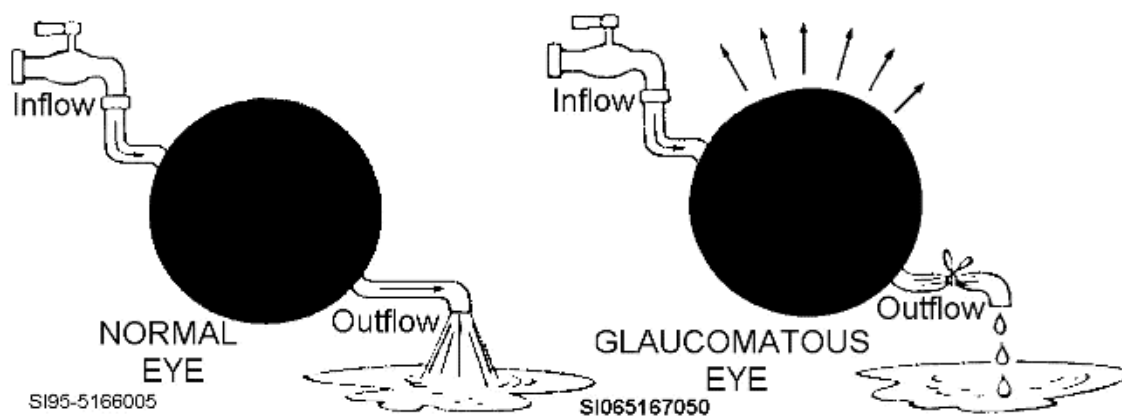


Figure 2–36. Decreased aqueous outflow causing glaucoma.

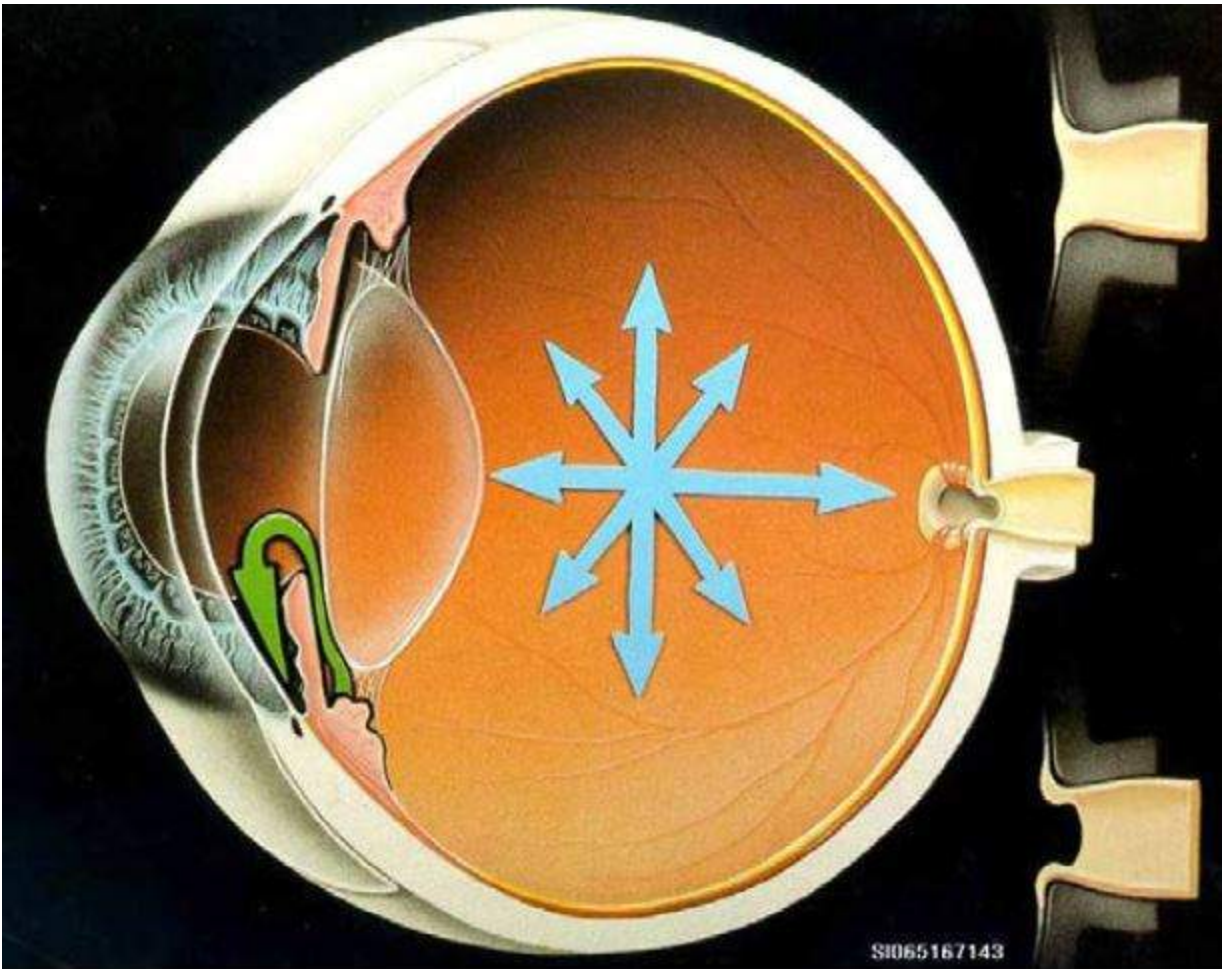


Figure 2-37. Increased IOP.

## Open-Angle Glaucoma

Increased IOP causes an enlargement and cupping in the optic disc at the back of the eye (fig. 2-37, lower right insert). The pressure in the eye damages the retina's nerve fiber layer, reducing its ability to carry a visual signal from the eye toward the brain.

This interference causes VF loss and is the characteristic, diagnostic trait of COAG. The VF loss most of the time begins in the periphery, with the central vision as the last to go. This means a patient, if left untreated, could see 20/20, but have virtually no remaining peripheral vision toward the end of the disease process.

Because it's a disease without pain, no loss of VA (until the very end), or other noticeable signs or symptoms, it's difficult to detect. A common initial symptom of COAG is a patient complaining of night

blindness. Remember, COAG robs people of peripheral vision first, and this is where the majority of rods are located. Retinitis pigmentosa (RP) could also cause night blindness and should be investigated regardless. (RP will be explained later.)

One of the primary methods used to screen for COAG is measuring the IOP, but this is only one factor considered before making a diagnosis. Patients with relatively low IOP (21 mm mercury [Hg] or lower) can still have the disease; it's referred to as low tension glaucoma. Patients with relatively high pressures (22 mm Hg or higher) can be free of the disease. They are referred to as ocular hypertensive. The differentiating factor is VF loss. If a person has signs of glaucoma and has a VF loss not due to retinal damage, visual pathway damage, tumors, and so forth, glaucoma can be diagnosed as the cause.

Traditionally, a patient with a relatively high IOP is screened for other indicators of COAG (e.g., an enlarged optic disc, asymmetric disc cupping, and cupping of the optic disc). If there is an abnormal looking disc or cup-to-disc (c/d) ratio, the doctor will order a VF test to check if the patient has any VF loss. If the optic nerve head and c/d ratio looks normal (say 30 percent or 0.3 c/d or less) and the VF is normal, then glaucoma is ruled out. If the optic disc is enlarged and the c/d ratio is higher than normal (say 40 percent or 0.4 c/d or more) and the VF is still clean, glaucoma is still ruled out.

Do you see a pattern here? There can be all sorts of signs indicating glaucoma is present; however, if the VF results continue to come out normal, glaucoma should not be diagnosed. The VF loss is the telltale sign. Without it, a diagnosis of glaucoma truly can't be made.

The drugs used to treat glaucoma pull the trabecular meshwork into a different position (Pilocarpine) or block some aqueous production (Timoptic, Betoptic, Betagan). Either way, the goal is to reduce the IOP, and to stop or at least slow down the VF loss. To monitor the progression of a patient's COAG, the doctor usually orders a yearly VF test. The doctor will also sometimes order the VF more frequently (i.e., after the patient starts or changes glaucoma medications).

## **Congenital Glaucoma**

Congenital, or infantile, glaucoma is often referred to as buphthalmos, since the infantile eyeball distends because of the elevated IOP. Fortunately, this is a rare disease. A practitioner may not see more than one case in five years of practice.

Infantile glaucoma is different from COAG because it usually has an onset in the first year of life and one-fourth of the cases are present at birth. Often, the parents notice the baby has an eye problem. Very few are diagnosed after the second year of life.

The child may be extremely sensitive to light, causing him or her to keep the eyelids tightly shut through the day. The eyes may tear profusely. Most noticeably, the corneal hazing makes most parents suspect something is wrong.

Unlike open-angle glaucoma where the best treatment is often non-surgical, congenital glaucoma must be treated surgically to obtain lasting results. The sooner the treatment, the better the prognosis; therefore, the next time a parent calls in stating their child's eyes are extremely watery; don't assume it's just a blocked puncta. Be aware there is a small possibility of congenital glaucoma.

## Secondary Glaucoma

Both open-angle and angle-closure glaucoma can be primary or secondary conditions. They're called primary when the cause of the condition is unknown. They're called secondary when the condition can be traced to a known cause (e.g., an injury or eye disease). Secondary glaucoma may be caused by a variety of medical conditions, medications, physical injuries, and eye abnormalities or deformities. Infrequently, undergoing eye surgery can also cause secondary glaucoma.

## Ocular Hypertension

At one time, individuals over 40 years of age with eye pressures greater than 21 mm Hg were considered to have glaucoma, whether they showed a VF loss or not. They were treated with the assumption that because of their higher pressures, VF loss would inevitably follow. The problem was these individuals with high IOPs may never have lost any VF if just left alone.

What do you call a patient showing signs of glaucoma (i.e., higher than normal IOP and changes to the optic disc), but no VF loss? They are called ocular hypertensive, meaning they are monitored, but not put on glaucoma medication unless they begin to lose VF, or have loss of or damage to nerve fiber layer. This makes sense. Don't treat what hasn't occurred and may not occur. Additionally, avoiding the term "glaucoma suspect" is good for the patient's mental health. Most people hear glaucoma and tend to freak, so ocular hypertensive is a safer, better term to use.

## Ocular Hypotension



Having high IOP is usually a bad thing. So the lower the pressure, the better right? However, how low is too low? Ninety five percent of your patients will be in the normal range for eye pressure (6–21 mm Hg). When IOP is below 6 mm Hg, it's usually referred to as hypotony, and can be traced to a chronic intraocular inflammation (uveitis), wound leaks after an eye surgery, or the presence of a retinal detachment.

If the IOP remains low, it can lead to irregular choroidal and retinal pigment epithelium (RPE) folding, engorged retinal vessels, and swollen optic disc. It's obvious a balance of reasonable eye pressure is ideal.

A final thought about glaucoma and eye pressure: high IOP is a relative thing, meaning you may perform non-contact tonometry (NCT) on a patient and the IOP may be 16 mm Hg, which is perfectly normal. Now consider; what if the IOP has always been 8 mm Hg the patient's whole life? Now 16 mm Hg doesn't look so good. It represents a doubling of the IOP in the eye and may really be an indicator of potential glaucoma. Keep this in mind before you "puff" someone, and then decide to proclaim the person as "fine" or "no glaucoma." Leave diagnoses to the doctor. There are many more factors to glaucoma than just IOP.

Remember, the best management is early detection. In the case of glaucoma, once vision is lost, it can never be regained. Chronic glaucoma is not curable at this time; however, its progression can be slowed with the right treatment.

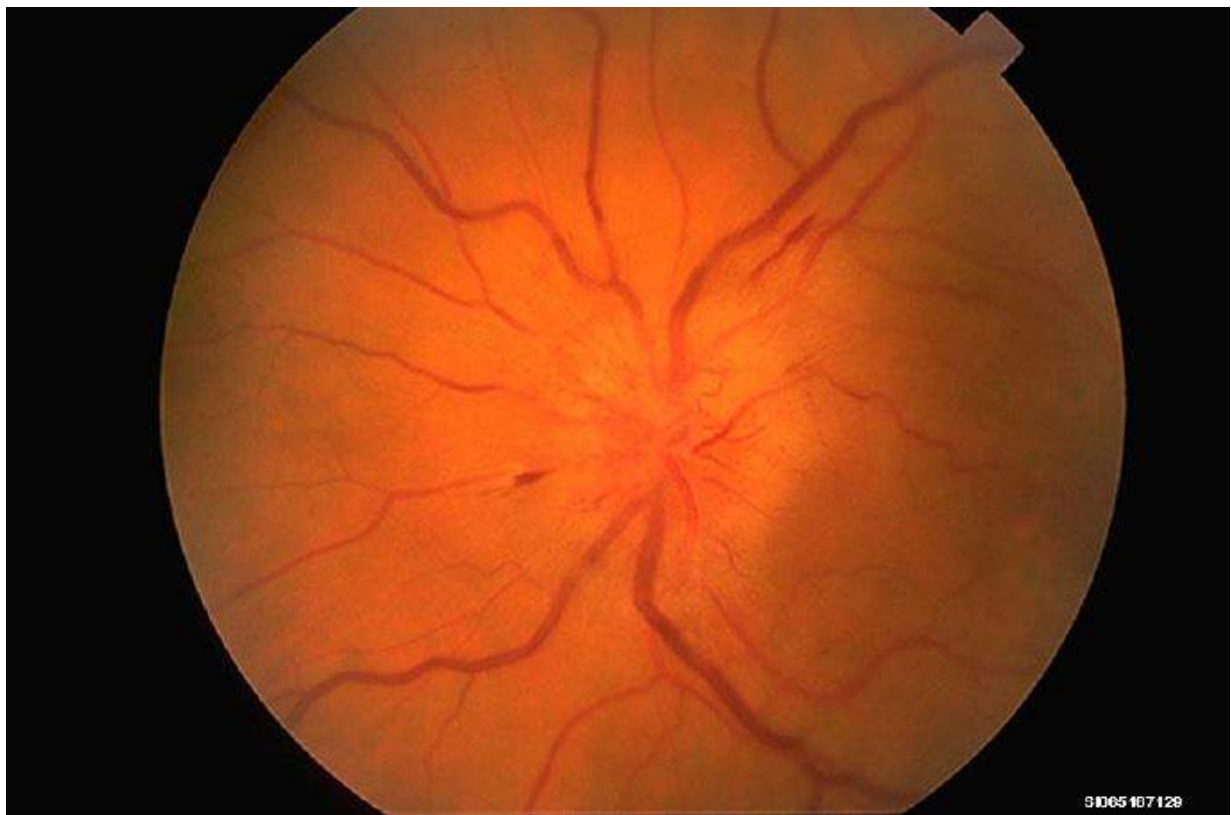


Figure 2–38. Papilledema.

---

## Papilledema

Papilledema is a non-inflammatory congestion of the optic disc and usually appears bilaterally (in both eyes). The optic disc congestion (fig. 2–38) is caused by elevated pressure within the skull. Papilledema occurs whenever there is an increase in intracranial pressure. The most common causes are tumors, abscesses, hematomas, and malignant HTN.

In papilledema, the blood vessels in the eyes may appear engorged. Additional symptoms may include flame-shaped hemorrhages next to the disc, and an enlarged blind spot shown with VF testing. There may be a decrease in color vision, and the patient's complaint is most likely a headache that is worse in the morning. VA may be normal, although a major symptom of papilledema is transient vision loss, from 10–30 seconds.

Papilledema takes one to five days to appear after the intracranial pressure has risen, unless the pressure increase is from an acute intracranial hemorrhage, in which case the optic disc may show swelling as quickly

as two to eight hours after the bleeding began. Sometimes the high intracranial pressure is the result of a brain tumor, requiring removal of the tumor.

Obviously, papilledema is a medical emergency. The patient must be admitted to the hospital and the intracranial pressure lowered. After the pressure in the skull reduces to normal levels, recovery takes six to eight weeks.

## Retinitis Pigmentosa

RP was introduced earlier during the discussion of glaucoma. It's a hereditary, progressive retinal degeneration in both eyes. The evidence of the disease is first found in the second decade of life, although the disease may develop in the forties and fifties. The first sign a patient may notice is loss of vision at night, as RP is a disease of the rods.

The primary diagnostic sign, visible through ophthalmoscopy, consists of pigmentation clumps (bony spicules) forming on the retina (fig. 2-39).

Night blindness (nyctalopia) develops, followed by a loss in the peripheral VFs, initially showing up as a ring-shaped defect at approximately 50 degrees (°). This VF loss progresses over many years to tunnel vision, and finally, blindness. The disease is difficult to deal with because, currently, there is no viable treatment for RP; however, there are some experimental implant and genetic treatments showing promise.

Additionally, experiments done with patients taking high doses of Vitamin A, lutein, and oily fish high in omega-3 fatty acids have shown a slight slowdown in the progression of the disease, but nothing medically significant. Because of the genetic nature of RP, genetic counseling (whether or not to have children) may be warranted. Additionally, the patient should be advised of the probable need for low-vision aids in the later stages of the disease. At this time, prognosis for RP is extremely poor.

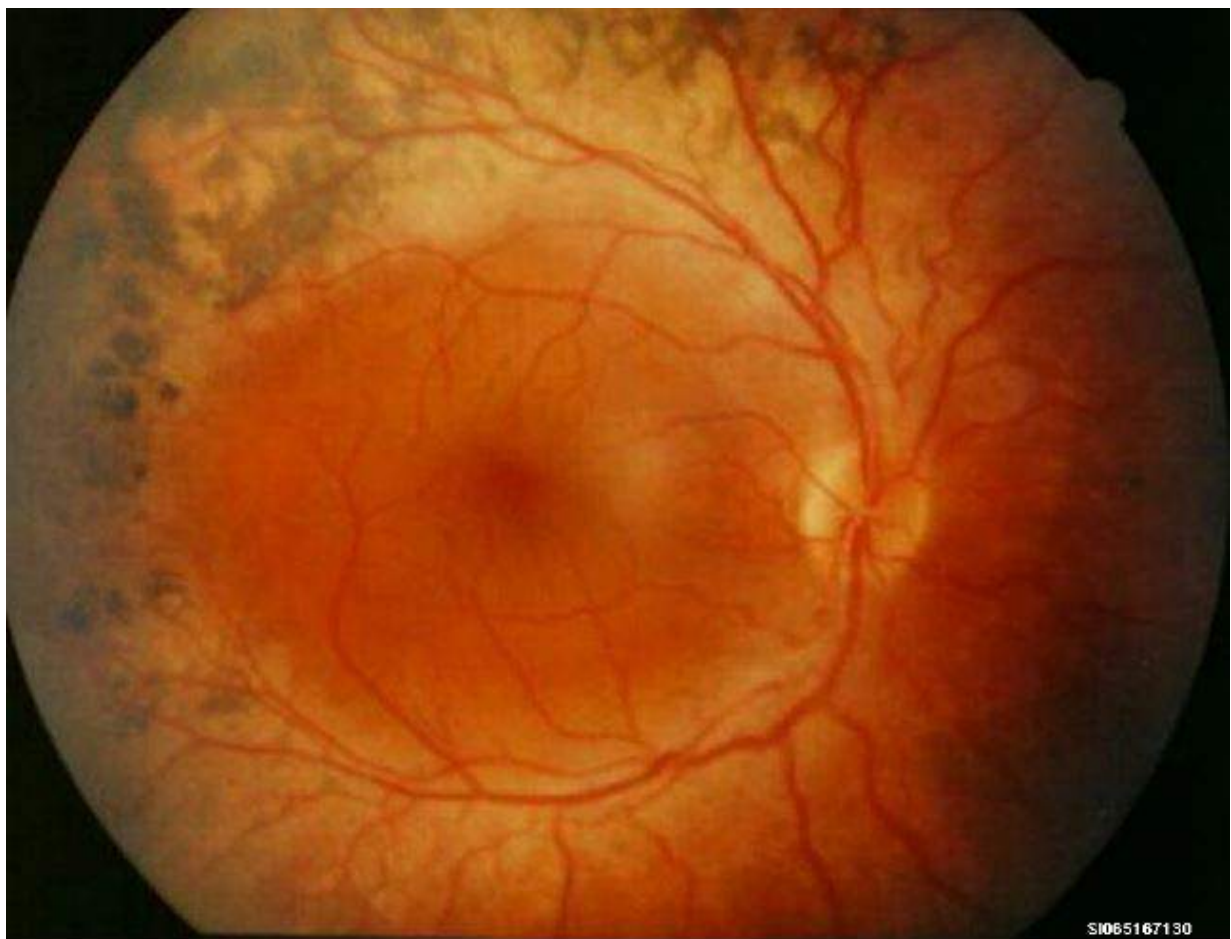


Figure 2-39. Retinitis pigmentosa.

## Tumors (Internal)

Internal tumors occur within the globe—obviously not a convenient location for removal. As with external tumors, an internal growth is categorized as malignant or benign, and the characteristics of both are the same.

## Choroidal Nevus

A benign choroidal nevus (freckle of the choroid) can look much like an early-stage malignant melanoma of the choroid. Because of this similar appearance, documentation (photographs) is important, as simple nevi can remain the same size, whereas a malignant melanoma of the choroid grows. By taking a photo of the suspect nevi and the patient making regular follow-ups (first one at three months, and then at six-month intervals thereafter), any growth can be detected before it progresses too far.

Usually, nevi are flat (a tumor is elevated), but this can't always be seen in early stages. Even though it's rare, occasionally nevi may undergo a malignant change, so monitoring for growth or shape change is an important part of the examination.

## **Malignant Melanoma**

This is the most frequently occurring intraocular tumor in adults. Fortunately, the incident rate is still very small, showing up in only about 0.04 percent of the population. Location, interestingly enough, is seen only in the uveal tract.

Malignant melanomas metastasize, so it's of great importance to find and treat them when present. Generally, the melanoma is found during routine ophthalmoscopy. Photo documentation and ultrasonography is required to track changes.

Melanomas frequently show up in people 50 years of age or older and are usually unilateral. This melanoma usually causes a retinal detachment as it grows. Treatment may be photocoagulation using a laser, radio-wave therapy, or, as a last resort, surgical excision.

## **Retinoblastoma**

Retinoblastoma is the most frequent intraocular tumor of childhood. It's present at birth in 0.00005 percent of children (or 1 in 20,000). It has one of the highest cure rates of any malignant tumor, but is fatal if left untreated.

The root cause of retinoblastoma is genetic defects. These defects can be related to an inherited problem or isolated genetic mutation. When retinoblastoma is inherited, it's usually bilateral. When it's related to a genetic mutation, it's usually unilateral.

The retinoblastoma tumor is normally discovered between the 15th and 30th month of life by a routine well-baby check or the parents noticing a white pupillary reflex. The tumor reflects the light back rather than a normal retinal reflex. The second most common indicator of a tumor is strabismus.

If the eye has a localized tumor and still has functional vision, treatment generally consists of radiation therapy. In eyes no longer visually functioning or having an extremely large tumor, enucleation (removal of the eye) is the treatment of choice.

# Ocular Migraines

Ocular migraines are not classified as an ocular disorder; however, the effect migraines have on your patients definitely warrants discussion, since the associated complaints often mimic other disorders such as iritis, retinal detachments, COAG, and CRAO.

An estimated 25 million Americans suffer from migraines, the most common neurological disorder. Of those sufferers, about 15 percent experience a stage called an aura. Researchers believe an aura is caused by a wave of electrical activity spreading across the visual cortex, causing visual hallucinations, which last 20 – 40 minutes.

These auras come in many forms, with the most common including flashes of light, “heat waves” seen in both eyes, and temporary blind spots. Auras usually precede the onset of the physical manifestations associated with migraines, which include intense pain behind or around one or both eyes, nausea, vomiting, photophobia, and sensitivity to sound.

## Types of migraines

Migraines can be divided into four main groups:

### Types of Migraines —

Migraines can be divided into four main groups:

- Common migraines, also known as migraines without aura, comprise about 80 percent of migraines. It's best described as the typical “sick headache.” Patients generally report mood changes, unilateral or bilateral pain, photophobia, and sound sensitivity. Common migraines can last for a few hours to days.
- Classical migraines are migraines with aura and comprise about 10 percent of migraines experienced by patients. With classical migraines, patients generally report auras followed by headache, feeling “out of sorts,” and may complain of nausea and vomiting.

The aura usually starts near fixation, radiates out to the periphery, and then disappears to be followed by the headache.

## Complicated —

Complicated migraines are very complex. Although rarer than common or classical migraines, complicated migraines represent the more severe visual complaints seen by optometrists and ophthalmologists.

Complicated migraines are broken down into the following subgroups:

- **Cerebral migraines** may be severe, and many of the associated symptoms last longer than the headache. One of the telltale signs of a cerebral headache is the incidence of permanent neurological deficits. Of special note to ophthalmic technicians is the possibility of permanent VF defects.
- **Ophthalmoplegic migraines** usually occur in younger patients (i.e., patients less than 30 years of age). When they occur, the headache is severe and unilateral. Once the headache subsides, one or more of the ocular muscles on the side of the headache is left paralyzed, and may take days or even weeks to recover their full function.
- **Retinal (or ocular) migraines** usually occur in patients under 40 years of age, and can be the scariest of all in relation to the visual disturbance experienced. The patient experiences a partial (retinal) or complete (ocular) loss of the VF in one eye. The retinal migraine usually gives no warning (no preceding aura) and is rarely, if ever, followed by a headache. Fortunately, the VF deficit is seldom permanent and the patient recovers full vision in 20–45 minutes; however, in rare instances, the ocular migraine can bring about retinal hemorrhages, vitreous hemorrhages, macular edema, and ischemic swelling of the optic nerve, which could lead to permanent damage.
- **Basilar migraines** are associated with brain stem dysfunction. Patients' complaints range from bilateral blurred vision to vertigo, ataxia (an inability to coordinate muscular movements that are symptomatic of some nervous disorders), nausea, lack of coordination, loss of balance, and speech difficulties.
- **Migraine equivalent** is a catchall phrase used for a host of symptoms fitting the criteria for migraine, but do not qualify for a specific type. Patients sometimes experience chest pains, vomiting, neurological symptoms, and the typical visual disturbance beginning near fixation and expanding to the periphery. With migraine equivalent migraines, there is no onset of headache. This often causes confusion on the part of the patient since migraines are usually associated with severe headaches.

## Cluster —

Cluster headaches may not warrant classification as migraines, depending on which headache criteria you use; however, given the ophthalmic presentations inherent with cluster headaches, we consider them as part of the migraine continuum. A cluster headache is a severe unilateral orbital, supraorbital, or temporal pain lasting from 15 minutes to three hours.

They are called cluster headaches because the patient experiences closely spaced attacks at the rate of two to eight per day. These cluster periods can last between two weeks and three months. After the cluster period is over, the patient may experience a pain-free period lasting 14 days or more. During an attack, patients also present at least one of the following signs on the same side as the attack:

- Ptosis
- Miosis
- Lacrimation
- Eyelid edema
- Nasal congestion
- Conjunctival injection
- Rinorrhea (runny nose)
- Forehead and facial sweating

Given the relation to ophthalmic conditions and the severity of the presentation, providers must differentiate cluster headaches from acute glaucoma, iritis, and hemorrhagic phenomena.

## Migraine Triggers

As anyone who suffers from migraines can tell you, there are certain things you can and cannot do if you wish to minimize the occurrence of attacks. Some of the more readily identifiable “trigger factors” follow:

- Trauma
- Loud noises
- Bright lights
- Refractive error
- Fatigue or stress (This can be physical (e.g., too hot or too cold) or emotional in nature)
- Hormonal changes associated with puberty, pregnancy, menopause, and even “the pill.”



- Certain foods such as caffeine (coffee, colas, chocolate, etc.), citrus fruits, alcohol (especially red wine), monosodium glutamate (MSG), nitrates and nitrites, aged cheese, nuts, yeast, corn, cane sugar, dairy products, and wheat. In short, just about anything.

## Migraine Diagnosis

To establish a diagnosis of migraines, a good case history is essential. This includes the number of headaches and frequency, medication used for headaches (if any), circumstances and age at time of onset (recent occurrence or lifelong problem), family history, characteristics of the pain, presence of an aura, any current situation that might be causing the attacks (e.g., disease, stress, change in medication, change in diet, etc.), trauma, surgery, or allergies.

Your doctor may ask you to perform certain tests, such as an Amsler grid or automated VF. As with any screening, you also want to check the patient's VAs and IOPs. Once the doctor has examined the patient to ensure the migraines are not due to an ocular problem, the patient may then be referred to neurology or internal medicine for a complete workup. The neurologist or internal medicine doctor may order an electroencephalogram (EEG), lumbar puncture, CT scan, MRI, or magnetic resonance angiography (MRA) to evaluate other possible contributing factors (e.g., arterial-venous structure abnormalities in the brain); however, the case history (which started with you) is the most important step in establishing a diagnosis.

**Self-Test Questions. After you complete these questions pertaining to inflammatory conditions and disorders, you may check your answers at the end of this module.**

1. Define inflammation.

Type your answer here

SUBMIT

2. What is uveitis?

Type your answer here

---

SUBMIT

3. What are the three divisions of uveitis?

Type your answer here

---

SUBMIT

4. What is the difference between iritis and iridocyclitis?

Type your answer here

---

SUBMIT

5. List four signs and symptoms of iritis/iridocyclitis.

Type your answer here

SUBMIT

6. Why is anterior uveitis dangerous?

Type your answer here

SUBMIT

7. What are the symptoms of pars planitis?

Type your answer here

---

SUBMIT

8. In cases of chorioretinitis, why does an inflammation of the choroid often involve the retina?

Type your answer here

---

SUBMIT

9. To ensure the posterior uveitis is resolved, what needs to be done in the treatment of chlorioretinitis, other than using steroids to reduce inflammation and minimize damage?

Type your answer here

---

SUBMIT

10. What is optic neuritis?

Type your answer here

---

SUBMIT

11. As related to optic neuritis, describe papillitis and retrobulbar neuritis.

Type your answer here

---

SUBMIT

12. What is a common cause of optic neuritis?

Type your answer here

---

SUBMIT

13. What are the specific signs of optic neuritis?

Type your answer here

SUBMIT

14. Why should optic neuritis be monitored closely?

Type your answer here

SUBMIT



Complete the content above before moving on to the questions in the next section.

**Self-Test Questions. After you complete these questions pertaining to systemic medical conditions with ocular disorders, you may check your answers at the end of this module.**

1. How do diabetes and HTN severely impair the visual system?

Type your answer here

---

SUBMIT

2. What is the leading cause of blindness in Western society today?

Type your answer here

---

SUBMIT

3. What is a key in the development in DR? What supports this claim?

Type your answer here

---

SUBMIT

4. What are the three stages of DR from the least to the most severe?

Type your answer here

---

SUBMIT

5. What are the earliest stages of DR marked by?

Type your answer here

---

SUBMIT



6. Fluorescein angiography is an invaluable tool in DR for determining what?

Type your answer here

---

SUBMIT

7. Why use an argon laser to kill portions of the peripheral retina?

Type your answer here

---

SUBMIT

8. How does the retina respond to ischemia?

Type your answer here

---

SUBMIT

9. How can DR cause a retinal detachment?

Type your answer here

---

SUBMIT

10. How can hypertensive retinopathy cause a BRVO?

Type your answer here

---

SUBMIT



Complete the content above before moving on to the questions in the next section.

**Self-Test Questions. After you complete these questions pertaining to conditions and disorders causing sudden vision**

loss or vision degradation, you may check your answers at the end of this module.

1. Which causes a more rapid loss of vision--a CRAO or a CRVO?

---

☐

CRAO

☐

CRVO

SUBMIT

2. In the case of an embolus in a CRAO, what is the best hope in initial treatment?

Type your answer here

---

SUBMIT

3. What does the term “nicking” mean when referring to CRVO?

Type your answer here

---

SUBMIT

4. What are some retinal signs that a CRVO has occurred?

Type your answer here

---

SUBMIT

5. Why does a retinal hole or tear allow a retinal detachment to occur?

Type your answer here

---

SUBMIT

6. What are the initial retinal detachment symptoms a patient notices?

Type your answer here

---

SUBMIT

7. How are retinal holes and tears usually treated?

Type your answer here

---

SUBMIT

8. What can cause the appearance of floaters?

Type your answer here

---

SUBMIT

9. What does PVD stand for?

Type your answer here

---

SUBMIT

10. Vitreous hemorrhaging can lead to what complications?

Type your answer here

---

SUBMIT

11. Although asteroid hyalosis looks like little asteroids suspended in the vitreous, what are you actually seeing suspended in the vitreous?

Type your answer here

SUBMIT



Complete the content above before moving on to the questions in the next section.

**Self-Test Questions. After you complete these questions pertaining to other internal conditions and disorders, you may check your answers at the end of this module.**

1. What are cataracts? What generally causes them?

Type your answer here

SUBMIT

2. What are the three general categories of cataracts?

Type your answer here

---

SUBMIT

3. How are nuclear sclerotic cataracts characterized?

Type your answer here

---

SUBMIT

4. Why might a cataract cause a myopic shift?

Type your answer here

---

SUBMIT



5. What type of cataract has the most profound effect on vision?

Type your answer here

---

SUBMIT

6. When are congenital cataracts formed? When are they present?

Type your answer here

---

SUBMIT

7. What could happen if a congenital cataract is not removed before the age of two?

Type your answer here

---

SUBMIT

8. What happens when the crystalline lens is penetrated?

Type your answer here

---

SUBMIT

9. What are the various methods of cataract removal?

Type your answer here

---

SUBMIT

10. Which cataract removal technique is least traumatic and allows for a small incision to remove the lens?

Type your answer here

---

SUBMIT

11. What is the term for a patient with a natural crystalline lens? With no lens? An artificial lens?

Type your answer here

---

SUBMIT

12. How can you tell if a patient has an anterior chamber lens?

Type your answer here

---

SUBMIT

13. What are the characteristics of glaucoma?

Type your answer here

---

SUBMIT

14. Angle-closure glaucoma is marked with a rise in IOP caused by what?

Type your answer here

---

SUBMIT

15. Which form of glaucoma is the most destructive?

Type your answer here

---

SUBMIT

16. What is the difference between a normal eye and one afflicted with angle-closure glaucoma?

Type your answer here

---

SUBMIT

17. Identify the signs and symptoms of angle-closure glaucoma.

Type your answer here

---

SUBMIT

18. Angle-closure glaucoma patients are usually treated with which medications?

Type your answer here

---

SUBMIT

19. What is a laser iridotomy? What is its purpose?

Type your answer here

---

SUBMIT

20. Why is a laser iridotomy done in the affected and non-affected eyes in cases of angle-closure glaucoma?

Type your answer here

---

SUBMIT

21. Where does the problem exist with aqueous outflow in COAG?

Type your answer here

---

SUBMIT

22. Increased IOP interferes with the retina's nerve fiber layer to do what?

Type your answer here

---

SUBMIT

23. Why is screening for COAG using IOP an inexact science?

Type your answer here

---

SUBMIT

24. What is the defining factor in a diagnosis of COAG?

Type your answer here

---

SUBMIT

25. What is another term for congenital or infantile glaucoma?

Type your answer here

---

SUBMIT

26. What symptoms might a child with congenital glaucoma present?

Type your answer here

---



SUBMIT

27. What is the best treatment for lasting results in congenital glaucoma?

Type your answer here

---

SUBMIT

28. What is an ocular hypertensive?

Type your answer here

---

SUBMIT

29. Ocular hypotension is also known as what?

Type your answer here

---

SUBMIT

30. What conditions could lead to ocular hypotension?

Type your answer here

---

SUBMIT

31. What causes the optic disc congestion in papilledema?

Type your answer here

---

SUBMIT

32. What are the symptoms of papilledema?

Type your answer here

---

SUBMIT

33. What is RP?

Type your answer here

---

SUBMIT

34. Why is loss of night vision a first sign of RP?

Type your answer here

---

SUBMIT

35. What is the primary diagnostic sign of RP?

Type your answer here

---

SUBMIT

36. Name the four internal eye tumors.

Type your answer here

---

SUBMIT

37. What is an indication that an iris nevus is no longer benign?

Type your answer here

---

SUBMIT

38. What is the most frequently occurring intraocular tumor in adults? In children?

Type your answer here

---

SUBMIT

39. Where are malignant melanomas found in relation to the eye?

Type your answer here

---

SUBMIT

40. What tumor has a root cause of genetic defects or genetic mutations?

Type your answer here

---

SUBMIT

41. What characteristic of retinoblastoma is usually noticed by parents between the 15th and 30th month of life?

Type your answer here

---

SUBMIT

42. Describe the general treatment of a retinoblastoma.

Type your answer here

---

SUBMIT

43. Of the total of migraine sufferers, what percentage experience a stage called an aura?

Type your answer here

---

SUBMIT

44. What is an aura? What do researchers believe cause them?

Type your answer here

---

SUBMIT

45. What are the four main groups of migraines?

Type your answer here

---

SUBMIT

46. Eighty percent of patients suffer from which type of migraine?

Type your answer here

---

SUBMIT

47. During a classic migraine, in what part of the VF does the visual aura begin?

Where does it end?

Type your answer here

---

SUBMIT



48. Which type of migraine represents the more severe visual complaints seen by optometrists and ophthalmologists?

Type your answer here

---

SUBMIT

49. What is one of the telltale signs of a cerebral migraine?

Type your answer here

---

SUBMIT

50. Which type of complicated migraine is known for causing temporary paralysis of one or more of the ocular muscles?

Type your answer here

---

SUBMIT

51. Which type of complicated migraine is associated with brain stem dysfunction?

Type your answer here

---

SUBMIT

52. List the seven migraine “trigger factors.”

Type your answer here

---

SUBMIT

53. List two tests which your doctor may ask you to administer when a diagnosis of migraines is suspected.

Type your answer here

---

SUBMIT



Congratulations! You have completed Module 2, Lesson 2. You can find the answer key for the self-test questions at the end of the module.

# Lesson 3 : Ocular Injuries, Treatment, and Triage of Ocular Conditions

---

## Main Points

### 1. Ocular Injuries

- a. War related ocular injuries
- b. Non-war related ocular injuries
- c. Purpose of eye irrigation
- d. Eye patching

### 2. Triage of Ocular Conditions

- a. Ocular emergencies
- b. Emergency ocular conditions
- c. Urgent ocular conditions
- d. Priority ocular conditions

---

The ophthalmic technician should have substantial knowledge in regards to prevention of eye accidents. You should have sufficient knowledge not only to deal with eye accidents as scheduled patients come through your clinic, but off duty as well. Accidents happen 24 hours a day in many different locations.

Many people participate in activities (e.g., sports and hobbies) that pose great risk to the eye. The National Society for the Prevention of Blindness reports ocular injuries are responsible for five percent of all blindness in children. Helping to prevent eye injuries before they happen and assisting in the treatment when they occur, are all part of the ophthalmic technician's world.

[Click here to begin Module 2, Lesson 3.](#)

## Ocular Injuries

An accurate eye injury diagnosis is achieved by a careful case history. Ask the patient what type of injury they have, when it occurred, and what their current pain level is. The amount of visual loss is an important clue to determine the extent of damage and lead the provider to the proper diagnosis. Any time there is an injury involving hammering, grinding, or similar actions, think about the possibility of a foreign body (FB) related injury.

Physical examination of the patient starts with measurement and proper documentation of the best VA. If the eyelids need to be separated to view the globe or check VAs, do not press against the globe. Make sure you press the upper lid up against the frontal bone. Until proven otherwise, treat all injuries as if the globe is ruptured.

## War Related Ocular Injuries

The management of battlefield eye injuries encompasses all levels of health care within the military health system. Proper care for mechanical, chemical, nuclear, and laser eye injuries begins at the front lines with well-trained first aid or buddy care. The next step could be eye care, ranging from general medicine and optometry up to ophthalmology located in the rear support area of a theater of operations. Read these next lessons carefully, as chances of seeing one or more of these injuries in the clinic is increasing with today's high operations tempo.




Figure 3–1. Battlefield environment.

---

## Battlefield Eye Injuries

The causes of battlefield eye injuries (fig. 3–1) include mechanical, chemical, nuclear, laser, and non- battle related injuries.

## Battlefield Eye Injuries

Battlefield eye injuries as a percentage of total war injuries was on the rise until recently. In 19th century warfare, less than one percent of all battlefield casualties suffered eye injuries. After WWI and WWII, the percentage of battlefield eye injuries as a percentage of total war injuries rose with each successive war, as shown in the following table:

The following four factors contributed to the increased percentage of battlefield eye injuries.

- Increased efficiency of modern munitions with fragmentation capability.
- Battle tactics (static defensive battlefronts account for increased battlefield eye injuries).
- Environment (in the Middle East, many eye injury complaints are related to desert conditions).
- Tank warfare (tank crews’ upper body, face, and eyes have increased exposure to injury. Sun, wind and dust goggles are frequently worn on the helmet, not over the eyes).

Ocular Injuries as a Percentage of Total War Injuries	
War	Percentage of All Injuries
WW I	2
WWII	3
Korea	8
Vietnam	9
Gulf War	13
Operation Iraqi Freedom/Operation Enduring Freedom	10

Chart: Ocular Injuries as a Percentage of Total War Injuries

Two Types Of Threats To The Eye	
Threat Type	Description
Ballistic	Mortars, rocket propelled grenades, and improvised explosives create fragmented ballistic objects (e.g., shrapnel, dirt, and small particulate matter). These objects pose great threat to extremities (e.g., head, neck, and limbs).
Environmental	Blowing sand, dirt, and other environmental objects cause injuries to the eyes, resulting in potentially sight threatening injuries such as intraocular penetration and corneal damage. These types of injuries accounted for 63 percent of all injuries in the area of operations (AOR).

## Battlefield Eye Injuries

As improvised explosive devices became the enemy’s weapon of choice, eye injuries soared. Ocular trauma is the fourth most common injury sustained in military combat today. During Operation Iraqi Freedom, the most common eye injury was trauma caused by improvised explosive devices. Unfortunately, the majority of blast-related ocular injuries occur in members also suffering from other life-threatening injuries that require immediate attention.

Protocol requires the surgical stabilization of any life-threatening injuries before eye evaluation and repair. Because of this, emergency ophthalmic procedures are often hours after injury, further reducing a successful outcome. 14 percent of globe injuries sustained during Operation Iraqi Freedom have required enucleation. Polycarbonate ballistic eyewear could have prevented many, though not all, of the ocular injuries reported. While not completely eliminating eye injuries, eyewear greatly reduce their occurrence, particularly against blast fragments.

In addition to ordering protective eyewear and caring for injured individuals, your job is to educate members on the threats to their eyes, and ensure they all know the importance of eye safety and protection. Your preventive care can help minimize the chances of an eye injury.

### Mechanical

US military ophthalmologists base the following categories of mechanical eye injuries on Ocular and Ocular Adnexal Injuries Treated during Operations Desert Shield and Desert Storm, a study written by T. H. Mader, et al. According to this study, battlefield mechanical injuries are categorized by the source of injury.



Munition and non-munition sources cause battlefield mechanical eye injuries. Sources of munitions include blasts (surrounding debris scattered secondary to explosion), mines, cluster bomblets, anti-tank missiles, grenades, bombs, booby-traps, bullets, and other related mechanisms. Non-munition sources include, but are not limited to, motor vehicle accidents, blunt traumas, falls, helicopter crashes, metal on metal, and other various means.

## Chemical

The German army first introduced chemical agents to modern warfare in WW I when, on 22 Apr 1915, the German army released 150 tons of chlorine gas upon two French divisions, killing 800 troops. Chlorine gas was the first chemical agent used successfully in a chemical attack and the verbal alert “gas” became the universal warning signal for a chemical attack.

Classifications of chemical agents are based on their mechanism of action with the body. Chemical agents can be delivered by missile, artillery, mortar, or aerial bomb. The following table describes chemical agents causing ocular injuries or side effects:

Chemical Agents That Cause Ocular Injuries	
Agent	Description
Mustard gas	<p>Is classified as a blistering agent. Our eyes are the most sensitive organs to mustard vapor injury. It has been noted the conjunctiva has reacted to concentrations as low as one part per 10,000,000. The majority (75 percent) of cases in WWI showed only a mild conjunctivitis that resolved within a few weeks (fig. 3–2).</p> <p>As the dose of the mustard gas increases, the severity of eye damage increases. Severe eye injury is secondary to liquid mustard from airborne droplets or self-contamination. Severe mustard eye injuries include severe conjunctivitis, photophobia, blepharospasm, pain, and corneal damage.</p>

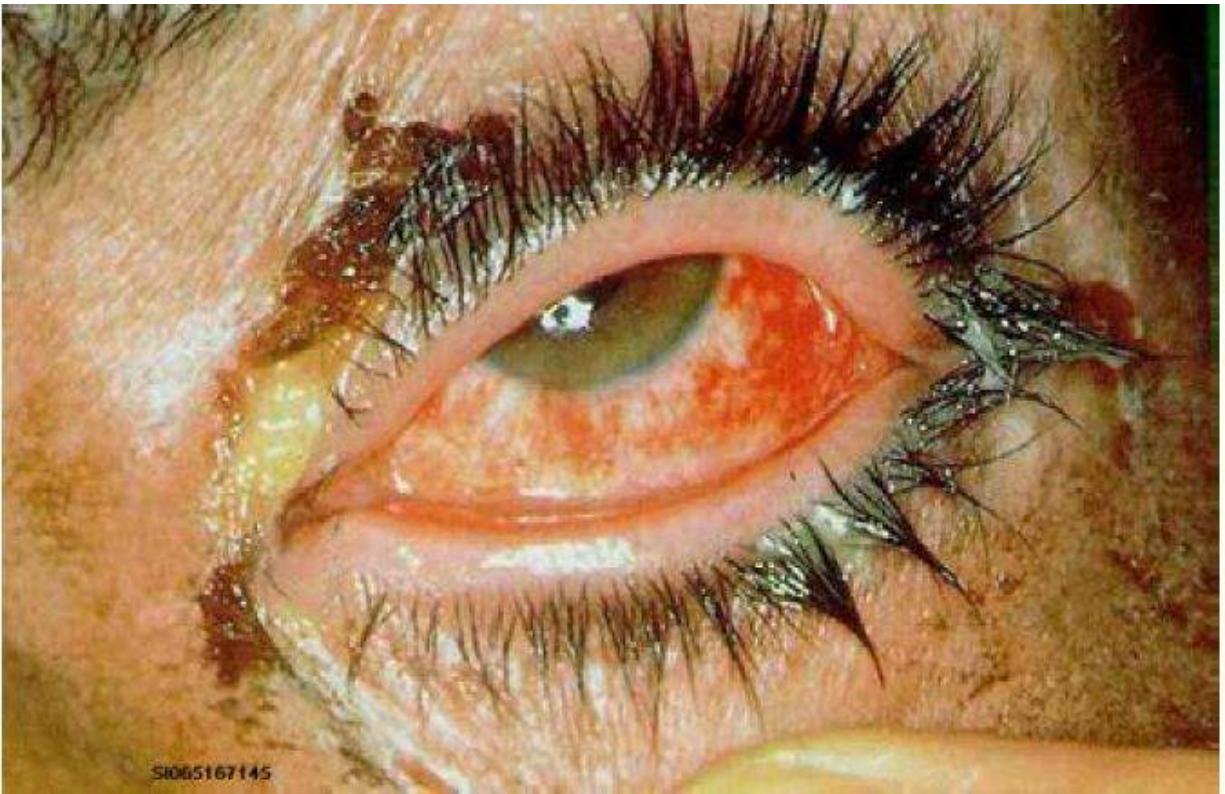
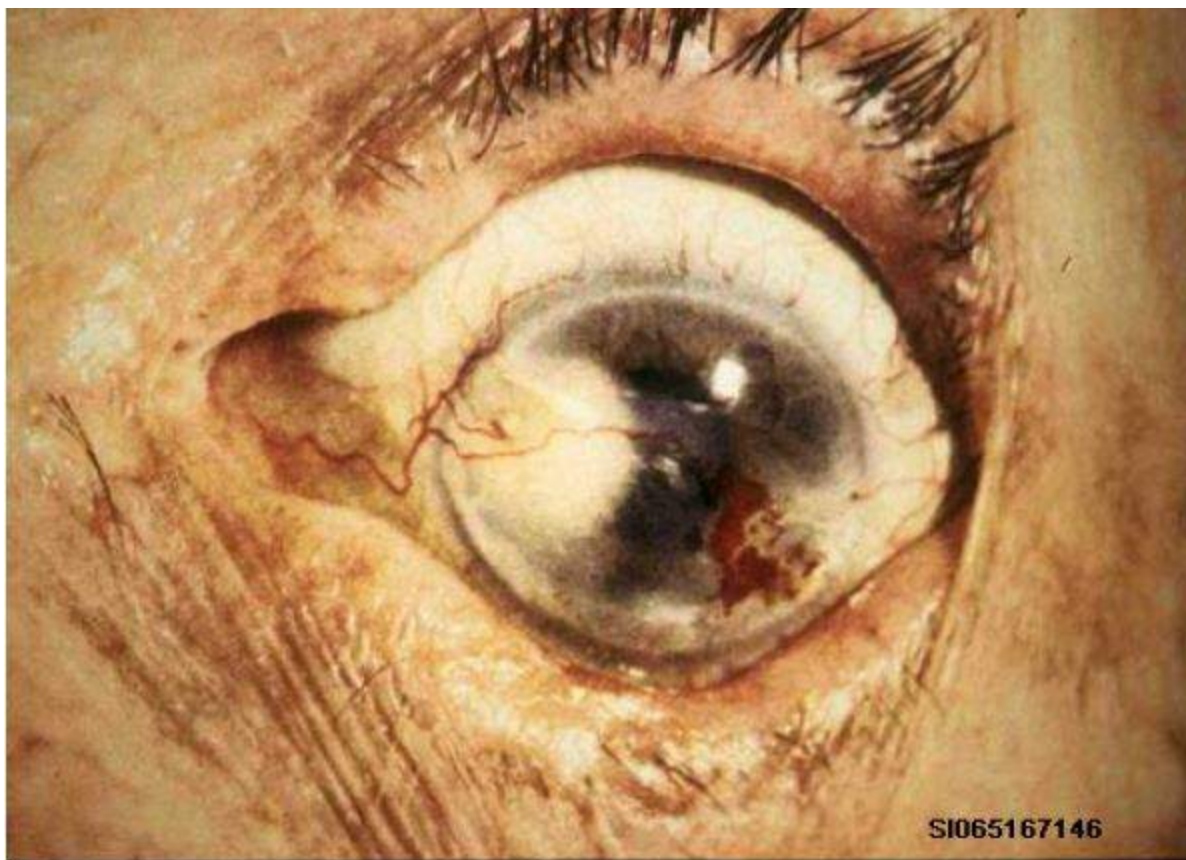
Figure 3-2. Conjunctiva post-mustard gas exposure.

---



Chemical Agents That Cause Ocular Injuries	
Agent	Description
	Corneal lesions (fig. 3-3), similar to alkali burns, are seen in less than 10 percent of mustard cases. Among these, less than 10 percent can have long-term corneal problems that include progressive vascularization, and persistent or recurrent ulceration.
Tear gas	<p>Is a lacrimation agent, also known as a riot control agent. These agents can come in the form of solids with low vapor pressures, and are dispersed as fine particles or in solution. The US military uses ortho-chlorobenzylidene-malononitrile, an agent called CS (named after the scientists Ben Carson and Roger Staughton who discovered it). Chloroacetophenone, known as CN (Mace®), is a commercially made form available for self-protection devices. Like mustard gas, the eye is very sensitive to riot control agents. Contact with the agent produces conjunctival and corneal burning, tearing, blepharospasm, and conjunctival redness.</p> <p>The active agent in the riot control agent is a solid, which makes it possible for particles to become embedded in the cornea and conjunctiva. Although unlikely and yet to be reported as a complication, this can cause tissue damage. Individuals seeking medical care for eye pain following exposure should undergo a thorough eye examination. Ocular symptoms following exposure begin in seconds to minutes. Duration of symptoms can last 15-30 minutes.</p>
Lewisite	Is a blistering agent. It's absorbed quickly and easily into the circulation system (causing hemolysis of red blood cells). It exceeds mustard gas in onset of action, pain, and speed of tissue destruction.
Phosgene	Is a choking agent causing a mild irritation of the eyes and usually clears with symptomatic treatment. Retinal hemorrhages have been reported secondary to hypoxemia (caused by pulmonary edema).
Nerve agents	Are organophosphorous cholinesterase inhibitors. Lethal doses cause excessive stimulation of end organs (increased salivation, increased secretions in the airway glands, increased urination, increased defecation, etc.); difficulty in breathing or cessation of breathing; and generalized muscular twitching, weakness, or paralysis. Low concentrations cause long-lasting miosis and ciliary spasms, causing myopia and decreased vision.



## Nuclear

The US in WWII first introduced nuclear weapons. In 1945, US bombers dropped a uranium bomb on the city of Hiroshima and a plutonium bomb on the city of Nagasaki. Missiles, aerial bombs, or artillery can be used to deliver nuclear weapons. Injuries associated with the eyes are secondary to nuclear explosions and are categorized by direct blast injuries, secondary lesions from radiation illness, and long-term effects are secondary to ionizing radiation.

Direct blast injuries produce mechanical injuries, which can be the same as those caused by the explosion of conventional weapons. Thermal burns occur to the external eyeball and adnexa. Flash burns are internal lesions (retinal lesions) and occur as a result of the intense flash associated with the exploded bomb.

## Lasers

Since the late 1970s, lasers have reportedly been utilized on the battlefield. Laser weapons were employed during the Gulf War and have been adapted for use on the battlefield for the following types of operations:

- **Anti-personnel** – Anti-personnel weapons are also known as “dazzle weapons” because they produce temporary or permanent blindness depending on their intensity. Typically, “dazzle weapons” are not effective in daylight unless they are intense enough to cause permanent ocular damage.
- **Anti-equipment** – Anti-equipment lasers are designed to damage the electro-optical sensors and electronic equipment critical to the operation of many modern weapon systems.
- **Range finding and target designating operations** – Lasers are also used to assist in target designation and range finding.

Cases of retinal burns among users of laser devices are primarily due to disregard for safety precautions and improper laser usage. Potential ocular injuries attributed to laser exposure include temporary blindness, intraocular hemorrhages, burns to the eyelid skin and cornea, and retinal and subretinal burns. Temporary blindness or flash blindness results from exposure to bright flash of light. Intraocular hemorrhages result from lasers of visible and near infrared wavelengths.

Short intense pulses of far-infrared lasers are responsible for external ocular injuries (burns of the eyelid and cornea). Retinal and subretinal burns are secondary to laser light of visible and near-infrared

wavelengths. The degree of permanent vision impairment is dependent upon the proximity of the retinal lesion to the fovea.

## Non-Battle Related Eye Injuries

Non-battle injuries can include accidental injuries, self-inflicted injuries, and malingering. The non- battle injuries refer to those injuries occurring on the battlefield when units are not directly engaged in combat. The following table describes some non-battle injuries:

Non-Battle Injuries	
Injury	Description
Accidental	Increased mechanization and motorization (i.e., helicopters, tanks, armored personnel carriers, etc.) has resulted in an overall increase in accidental non-battle injuries.
Self-inflicted	Can occur in war. In WWII, some personnel placed organic and inorganic matter and chemicals in their conjunctival sacs. In these cases, it's sometimes difficult to differentiate genuine injuries from self-mutilation.
Malingering	Can take the form of vision impairment or blindness. Dr. LaGrange in WWI reported a classic case as follows: "The patient remained completely blind for 15 months following an explosion. He only recovered after he was anesthetized and told his optic nerves were reattached with silver wire."

## Non-War Related Ocular Injuries

The structure of your face helps to protect your eyes from injury. Still, injuries will occur. The most common type of injury happens when something irritates the outer surface of your eye. Certain jobs such as industrial jobs or hobbies such as carpentry increase the risk. Eye injuries can range from minor, such as getting soap in the eye, to the catastrophic, resulting in permanent loss of vision or loss of the eye.

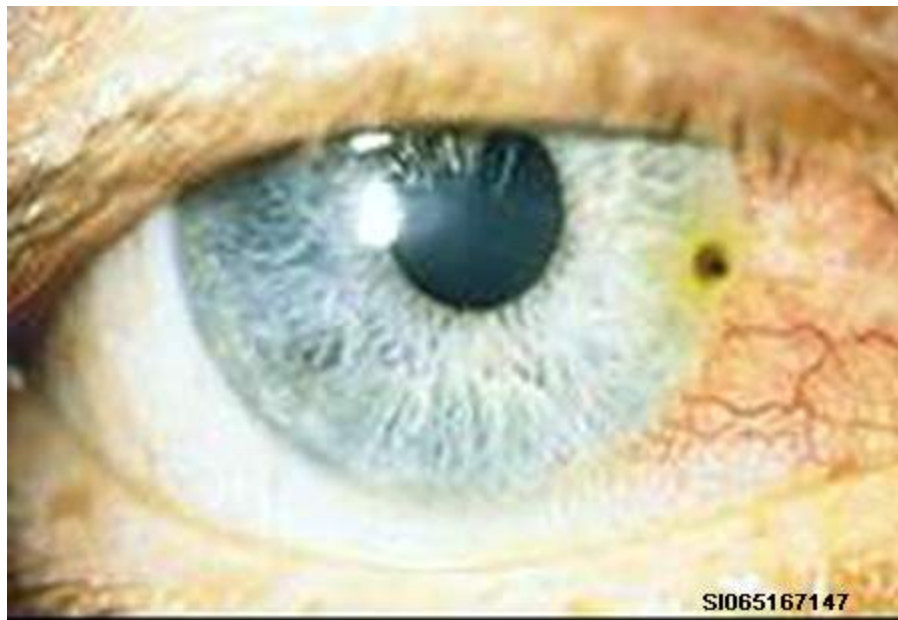


Figure 3–4. Metallic foreign body.

---

## Foreign Bodies (Superficial)

Any object not part of the body is considered an FB. When FBs get into the eye, they can be very irritating and do quite a bit of damage. Common FBs found in the eyes are metal, wood, plastic, hair, glass, dirt, and plant matter. All FBs should be treated as an ocular emergency. Material such as metal or organic matter is especially irritating because the eye does not tolerate these materials well.

Before removing the FB, check the VA of the injured eye. It may seem strange because the patient may be in a lot of pain, but it's important. VA must be assessed immediately following the injury to assess a baseline vision. How else can the doctor know if the treatment is working if he or she doesn't know the patient's vision before starting treatment? This can also help prevent patients blaming their vision loss on you or the doctor.

Treatment begins by getting a case history of the injury. What got into the eye? How? How much? How long ago? Was the patient wearing protective eyewear? This is important to determine as the FB may have penetrated the eye. A piece of metal coming from a grinder has some speed to it and may have penetrated deeper than a piece of dirt just blowing into the eye. Additionally, the material type can be important in determining the extent of possible damage and type of treatment needed.

Steel rusts in the eye (fig. 3–4) and makes healing difficult. Removal of the rust is accomplished using a burr tool, called an alger brush, which looks and sounds like a dentist's drill. Obviously, an anesthetic is used prior

to “grinding” away at the cornea.

## Foreign Bodies (Superficial)

Any medication instilled in the eye to relieve pain and blepharospasm (uncontrolled lid spasms) should be administered only with the instruction of the attending doctor.

The body reacts differently to organic materials like wood, paper, and the garbage that can come off a fingernail versus inert material (e.g., glass or plastic). The type and origin of the FB determines the approach for removal and follow-up treatment.

Removal of superficial FBs should be attempted with irrigation first. Sterile saline is the way to go. The less trauma required to remove a FB, the better. If it doesn’t “wash” out, a moistened Q-tip can be used to gently sweep up the item. This is something best left to your doctor, unless the doctor has trained you to do it.

Sometimes superficial FBs lodge under the eyelids. This is bad news for the patient, as every blink and eye movement causes additional abrasions to the eye. Again, irrigation is always the first step. The next step is the moistened Q-tip. If the object is still there, the doctor may attempt to use other tools to remove it, or in the case of optometrists, they may decide to send the patient to someone with surgical skills. Each case is different.

Once the FB is removed, the patient may still complain of an FB sensation. This complaint is typical if the cornea has been scratched from the trauma. Normally after an FB is removed, the provider instills an ocular antibiotic ointment to prevent infection and help the cornea heal. Depending on the severity of the abrasions, the eye may or may not be patched. The cornea, specifically the epithelium, heals very fast, in most cases within 24 hours. Regardless of whether a patient is patched or not, proper follow-up care is required.

If the eye is not patched, the patient should be seen the following day to ensure the eye is healing properly. If the eye is patched, the patient needs to return within 24 hours, because with the eye patched, you have a perfect growing medium for bacteria--warm, moist, and dark; therefore, a fresh dressing is required every 24 hours. Also, keep in mind, if the patching treatment is more than one day; have the patient see the



doctor every 24 hours, and replace the patch each visit. You may need to modify your work schedule to include weekends and holidays.

## **Foreign Bodies (Penetrating)**

An even more serious type of FB is one that actually penetrates the structure of the eyeball. This type is not always easy to diagnose and a good case history is crucial to indicate it. It's possible for a tiny particle of metal propelled at high-speed to enter the eyeball or orbital structures with no evidence of its existence. A high-speed particle may be hot enough to cauterize the tissue as it penetrates the eye, making external detection nearly impossible. X-rays are always ordered for high-velocity metal FBs to rule out penetrating injuries.

If there is aqueous leaking, how can you tell the difference between the aqueous and normal tearing? Doctors use the Seidel test to evaluate this by using Fluorescein to highlight aqueous leaking from a penetrating wound. Whether leaking or not, these cases are surgical emergencies and are sent to a surgeon for treatment.

A penetrating object is very serious, and the penetration point of the eye may be leaking vitreous or aqueous humor. Retinal detachment may also occur. If the object has hit the crystalline lens, a traumatic cataract may develop. Inner infection of the eye (endophthalmitis) is a possibility, too. Oddly enough, the patient may not feel much pain, and the entrance wound may be small. Since the symptoms are deceiving, refer any patient with a suspected penetrating FB to a surgeon for treatment.

It must be said, do not pressure patch an eye that has a penetrated globe. A pressure patch can force aqueous or vitreous humor out of the eye. Additionally, do not check the intraocular pressure (IOP) when there is a penetrating globe injury as this could also displace intraocular fluids.

If a large wound exists, and the eye is leaking fluid, immediately lay the patient down on his or her back (i.e., face up). Being very gentle, transport the patient to a hospital where surgery can be performed. If an object is protruding from the eye, do not try to remove it, and don't try to immobilize it.

If the object is not sticking out far, you may tape a cup over the eye to keep debris out and patch the other eye to limit eye movement. Remember the eyes are yoked. If one eye moves, the other follows, increasing the chances of further injury. If the FB is hitting the cup as the eye moves around, get rid of the cup. Any



contact the protruding object has with something outside the eye, increases the likelihood of more damage occurring to the structures inside the eye.

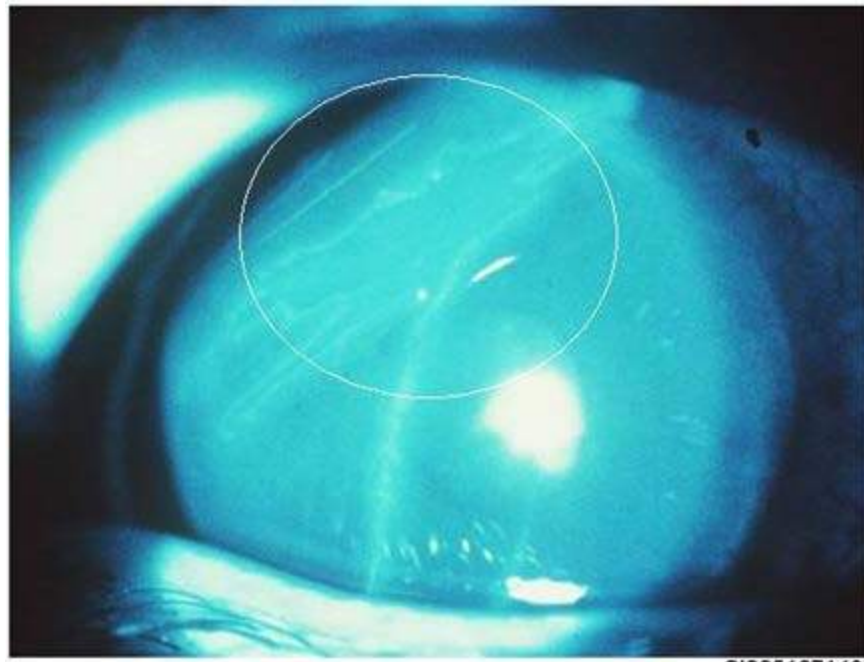


Figure 3-5. Corneal abrasion.

---

## Corneal Abrasions

Corneal abrasions (fig. 3-5) are usually found whenever an FB enters the eye. The eye becomes irritated and watery due to the large number of nerves in the cornea (remember, the 5th CN or trigeminal nerve innervates the cornea).

Abrasions are just superficial scratches that can be detected by instilling fluorescein dye in the eye. The dye fills in the scratches, making them easily visible with a slit lamp. Doctors like to see how deep and long the abrasion is, and how much corneal tissue has been damaged.

If the scratch is deep enough to damage the Bowman's layer, a scar can develop. If the scratch is long or a wide swath of cornea is affected, it takes longer for the tissue to heal. If the scratch is across the visual axis (line of sight), it can have a long-term effect on VA.

Treatment for a corneal abrasion is to make sure there is no FB in the eye, give the patient some antibiotic ointment, bandage CL or pressure patch the eye for 12-24 hours (if needed), and then re-evaluate.

The rate of healing depends on the amount of corneal tissue injured, presence or absence of infection, and type of material that caused the abrasion. An eye scratched with a fingernail, paper, branch, or other organic substances may take longer to heal than an eye scratched with an inert item (e.g., glass or plastic). If a piece of steel scratched the eye, make sure any traces of rust are removed. If rust remains in the eye, the epithelium may heal over it, and then spontaneously slough off again later, or even develop into a corneal ulcer. All foreign matter must be removed for the cornea to heal correctly. As for putting on a pressure patch, you'll most likely do it, not the doctor. The better job you do, the more likely the eye is going to heal quickly.

## **Thermal Burns**

When a person is burned about the face or eyes in a fire or other extreme heat source, the eyelids usually close immediately in an attempt to protect the eyeballs. If the eye is burned, it should be irrigated with a sterile saline solution and seen by an ophthalmologist immediately. If the eyelids are burned, apply a loose, moist dressing and get the person to dermatology for treatment of the burned skin. Burns are never a good thing, as scar tissue can form and healing is slow. Keeping the burned area moist is the best we can do until the patient can get to a doctor.

## **Chemical Burns**

There are many duties in the Air Force requiring individuals to work around chemicals that are potentially hazardous to the eye. Chemical burns from battery acids, cleaning fluids, and jet fuels are common. In general, the immediate treatment for chemical burns is prolonged irrigation (minimum 30 minutes) with sterile saline or plain water if no saline is available.

Chemical injuries are the only time when treatment takes priority over VAs. Irrigation is much more important as the patient may not have any vision left if irrigation is not started and continued until the chemical is removed.

The importance of the word "immediate" must be stressed because it's not uncommon for a report to come to the eye clinic by telephone noting a chemical has splashed into an eye. The person who receives the call must be aware that immediate treatment by the people with the injured worker is absolutely necessary.

Instruct the patient to hold the eyes open under a faucet or put his or her face into a bucket of water, blinking the eyes rapidly. Sometimes the pain may produce blepharospasm, making it difficult for the patient to hold his or her eyelids open during irrigation without some assistance. For irrigation to be effective, the eyelid must be held open. If possible, have the individual continue irrigation enroute to the hospital. Continuous irrigation really increases the patient's odds to recover.

## **Acid Burns**

Acid burns (sulfuric acid, hydrochloric acid, etc.) have a better prognosis than do many other types of chemical burns. Acids tend not to penetrate the eye. They make contact, burn what they touch, but do not continue to penetrate like burns from alkali. The almost instantaneous local tissue destruction at the point of contact provides a barrier slowing or preventing further damage by the acid. Because of this barrier, acids generally do not penetrate the underlying tissue as readily as alkalis do.

Another reason acids do not tend to penetrate into the eye is the tears of the eye have a "potential of hydrogen" (pH) on the alkali side of neutral. This acts to neutralize the acidic pH of the chemical, because alkali (tears) counteracts acid (the chemical having got in the eye).

Irrigation should begin immediately after the injury occurs and continue until an ambulance can pick up the patient. If the patient comes directly to the clinic, the doctor may authorize the instillation of an anesthetic to alleviate the patient's discomfort. Then, irrigation for 30 minutes or more should begin to rinse away the acid and dead tissue, and dilute acid absorbed by the tissue. Irrigating the eye immediately after the acid enters it provides the best chance to save the patient's vision.

## **Alkali Burns**

Unlike acid burns, alkali's have a tendency to produce a sustained reaction (fig. 3-6). Progressive damage to the eye continues until the alkali (sodium, potassium, ammonia, etc.) is flushed and diluted by long term irrigation. Again, immediate irrigation goes far in saving the patient's vision.

If a patient calls with an alkali burn, have him or her begin irrigation and continue until the ambulance arrives. It's far more important to irrigate immediately with available resources, and call an ambulance rather than wasting critical time in the car without irrigation coming to the hospital. Coming to the hospital is important, but not as important as irrigating first. It's best to have the person stay put, and continue irrigation while waiting for the ambulance.

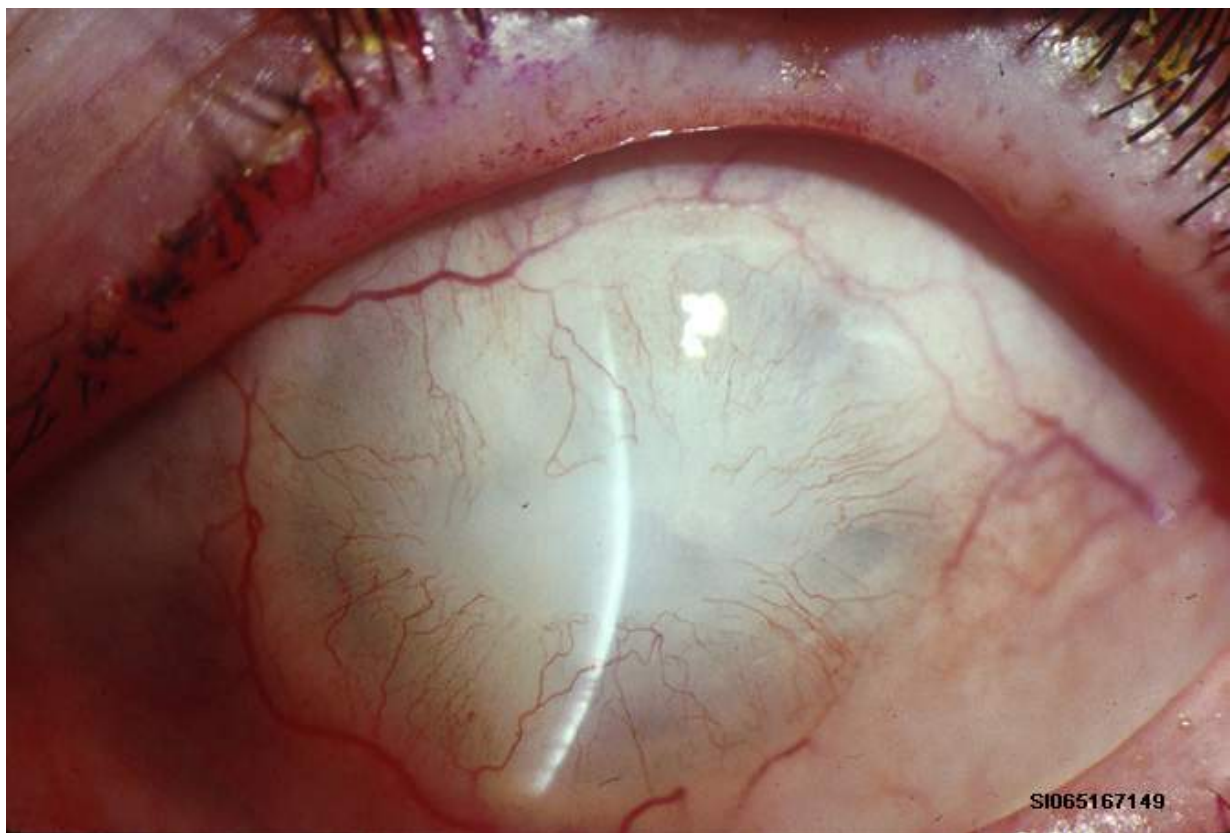


Figure 3-6. Alkali burn with neovascularization.

## Alkali burns

Once the person arrives (if brought to you), continue to irrigate the eye for at least 30 minutes, if not longer. The doctor may approve the use of an anesthetic to ease the patient's discomfort and greatly increase the effectiveness of your irrigation, but check with the doctor. Don't put anything but sterile saline into the eye until the doctor says it's okay.

Irrigation should continue until the eye's pH has returned to normal. The patient's pH can be checked by placing a strip of Litmus paper in the lower conjunctival sac just as you would do when performing the Schirmer Tear Test. The pH should be 7.3–7.7. If the pH is still abnormal, resume irrigation. It may be necessary to continue the irrigation for quite some time. As soon as practical, make sure the patient sees an eye doctor; however, irrigation must not be interrupted until the provider says so. Too much irrigation doesn't hurt anything, but too little may allow permanent eye damage to occur.

Another reason alkalis can be so destructive is our tears are slightly on the alkali side of neutral pH. If an alkali chemical gets in the eye, your eye's natural reaction is to neutralize it, and flush it out with tears.

Unfortunately, your tears are mildly alkali also, so it doesn't neutralize the chemical at all.

## Radiant energy (injury)

As an eye technician, you need to be familiar with common eye injuries caused by radiant energy, which include ultraviolet (UV) radiation, infrared rays, and X-rays.

### UV RADIATION

### INFRARED RAYS

### X-RAYS

This is the most common radiation injury and stems from absorption of UV light rays by the cornea. UV not only causes sunburns to the skin, but degrades the corneal epithelium as well. About two percent of the sun's UV light penetrates through our atmosphere and to the ground, but on exceptionally clear days or at high altitudes, there is a slightly higher exposure rate.

Now consider being out on, or near, the water, bright sand, or snow. These are reflective surfaces. Your eye receives two percent of UV directly from the sun and at least another two percent from the reflective surface, doubling the concentration received. This is a recipe for damage to occur and is commonly known as snow blindness. Other sources of UV radiation are carbon arc lamps used in welding and sunlamps used by indoor tanning worshippers.

The cornea essentially becomes sunburned from the UV radiation, much like your skin; however, the cornea is much more sensitive to UV radiation than our skin. Unfortunately, a sunburn on the cornea degrades the corneal epithelium.

Initially, the person doesn't feel anything, but after a few hours, the eyes feel gritty, much like an FB sensation, and then begin to tear. Later still, a more intense FB sensation can occur, and the pain can be extreme. The patient feels photophobic (light sensitive) and probably feels miserable.

The term "**snow blindness**" comes from UV radiation injury to the eye cornea. The corneal epithelium experiences some pitting and erosion, which is evident with fluorescein staining. Treatment begins by taking the patient's VA. The patient may receive an anesthetic allowing examination of the eye(s) by the doctor.

Generally, patients are prescribed a topical non-steroidal anti-inflammatory drug (NSAID) (e.g., Voltaren and lubricants). Inform the patient not to rub the eyes and rest as much as possible. Vision may be fuzzy for up to a week afterward, and some photophobia may remain. Of course, it's important to advise the patient of the need for protection against UV exposure in the future. In most cases, a pair of sunglasses can prevent excessive UV exposure.

### UV RADIATION

### INFRARED RAYS

### X-RAYS

This is the infamous eclipse burn to the retina of the eye. An eclipse burn usually occurs when someone decides to blow off all the warnings about not looking directly at a solar eclipse. A person looking directly at a total eclipse of the sun experiences an intense concentration of the red spectrum (infrared) to the macula.

During an eclipse, it's dark so the pupils are large. The red light rays entering the eye are concentrated, but for some reason, the red light rays don't trigger the brain to constrict the pupils. This particular quirk is a good thing for military people working at night because the use of red light preserves night vision; however, this is a very bad thing during an eclipse.

The red light rays enter the dilated pupils in large amounts. The concentration level is high enough to burn the retina and damage it permanently. This causes irreversible loss of VA and is quite tragic since it's so avoidable. People who think wearing sunglasses or polarized lenses protect them are wrong, because the hazard from an eclipse is the infrared rays. Sunglasses and Polaroid lenses are designed to defend against UV rays.

Never directly view a solar eclipse without the proper infrared ray eye protection.

If a person has looked directly at an eclipse, the only treatment available is patching. This gives the marginally damaged portions of the retina(s) a slight chance of some recovery. Ultimately though, permanent damage has usually occurred.

### UV RADIATION

### INFRARED RAYS

### X-RAYS

X-rays are short wavelengths of energy beyond the visible, violet end of the electro-magnetic spectrum. The damage inflicted on the eye by exposure to X-rays can be cataracts, necrosis (death) of the skin, loss of lashes, and glaucoma.

This is why great care is taken by radiological specialists to minimize X-ray exposure to the eyes. Thus, very few cases of X-ray induced ocular injuries are found. If X-ray exposure damage is suspected, the patient must be referred to an eye doctor for treatment and documentation of the injury.



Complete the content above before moving on.

## Laceration of Lids (and Globe)

Lacerations of the eyelids (fig. 3-7) may appear to be very serious because of the amount of blood involved, but if the eye is not involved, there is no direct impairment of the patient's vision. This doesn't mean lacerations to the eyelids should be treated as inconsequential, as the damage to muscles opening or closing the lids can have a lasting effect on the eye functionally and cosmetically. This is because scar tissue forms as tissue damage heals. This can then cause entropion and other poor eyelid functioning problems. Additionally, it's usually not cosmetically pleasant to have damage to the tissue around our eyes.

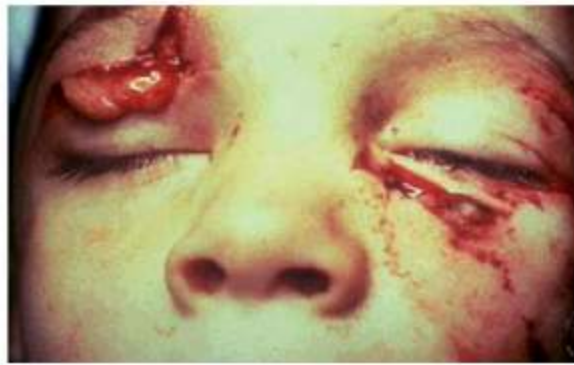

Figure 3-7. Lacerated lid.

Vertical (up and down) lacerations to the eyelids are in the same orientation as the levator palpebrae superioris, a striated muscle primarily responsible for opening the eye, so vertical lacerations tend to have a less damaging long-term effect. A cut going in the same direction as the muscle does not cause as much damage, which minimizes long-term problems.

Lacerations going horizontally (side to side) across the upper lid can be more devastating, as this type of laceration goes across the muscle fibers of the levator palpebrae superioris and can lead to permanent muscle damage leading to ptosis.

Any severing of the eyelid margin (edge close to the eye) is going to cause some residual problems because this is where the orbicularis oculi, a round sphincter muscle primarily responsible for closing the eye, is located.

If the eyelid is damaged, it may prevent the eye from closing completely. When it heals, the scar tissue may also cause the eyelid to have irregular contact with the globe and mess up the blinking action of the eyelids. Disrupting the normal closing of the eyelid can allow the eye to become dry in places, fail to wipe debris off the eye, and lead to more serious visual consequences.

It's important to know, any laceration affecting the lacrimal system also has some long-term consequences as tears are an essential element of good eye health. If the tears can't get to the eye from the lacrimal gland or cannot leave the eye through the punctum and canaliculi, the health of the eye suffers.

## Finding a Way

Epiphora and dacryocystitis are two of the more common results from lacrimal system damage. Tears lubricate, clean, and help fight against infection. They work most effectively at fulfilling these roles when the lacrimal system is unharmed. Tears can get to the eye in the proper quantity and location removing the debris and harmful germs from the eye.

When the eyelids are lacerated and the eyeball is not involved, bleeding may be controlled by a pressure dressing. However, if the eyeball is lacerated (fig. 3– 8), or even suspected of being lacerated, pressure should not be applied to the eye, because aqueous and vitreous liquid can be displaced and irreparable damage done.

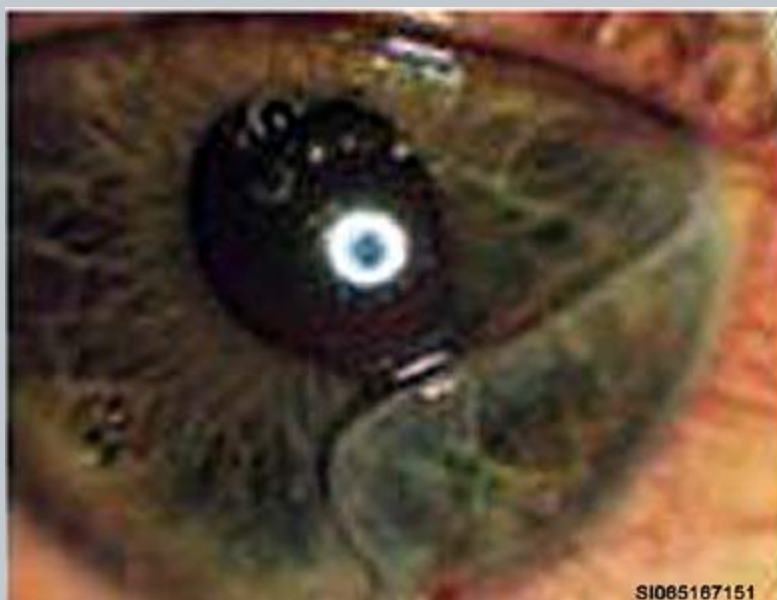

Figure 3–8. Lacerated cornea.



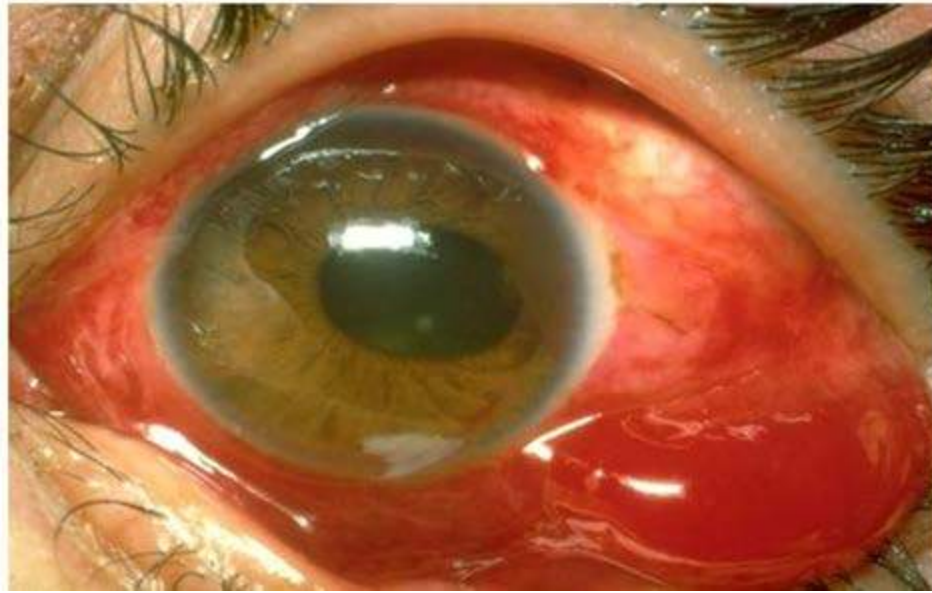


Figure 3-9. Lacerated globe.

---

## Laceration of Lids (and Globe)

Explosions, high-speed metal or wood particles, knives, steering wheels, or dashboards of cars are capable of causing eyelid lacerations. Treat any eyelid laceration as soon as possible. Get these patients to a surgeon quickly. Wounds not closed within six to eight hours are considered contaminated. Worse yet, retraction and swelling develop, making it more difficult to repair the damage. If you are working in an ophthalmology clinic, have the proper supplies and medications available for such a scenario; broad-spectrum antibiotics and tetanus toxoid are just two examples. Ask your doctors what they prefer, have it ready, and know where it is if a patient in need comes to you for help. If the globe of the eye is lacerated (fig. 3-9), the patient should lie down in a face-up position allowing gravity to hold any remaining fluid in the eye and against the retina.

The patient should keep both eyes closed to minimize movement and reduce the chance of airborne debris getting into the injured eye. Gently place the patient on a litter for transport to surgery. A laceration of the eye--the cornea or sclera--is sight threatening and should be seen immediately.

## Blunt Non-Perforating Injuries

A contusion is defined as an injury without a break in the skin (e.g., bruise). The most common external contusion recognized by most people is a "black eye." It's an injury caused to the general area around the eye by a blunt object (e.g., a softball, fist, racquetball, etc.). Treat a black eye symptomatically with cold

compresses to reduce the swelling for the first 48 hours, and then use warm compresses. Because of the nature of this injury, it's important to have the eye examined immediately. The swelling induced in a black eye may prevent comprehensive examination later. Contusion of the eyelid is not normally serious if the globe of the eye is not involved. If there is contusion to the globe, there is an increased chance of internal ocular injury. Any trauma severe enough to "blacken" the adnexa of an eye can potentially cause a variety of eye problems.

A black eye may be associated with a broken nose. The bones between the nose and the orbit are quite thin; if these bones are broken, the patient may be able to blow his or her nose and feel pressure under the eyelids, along with some swelling. This happens because the air from the sinus cavity is now pushed into the orbit. Patients should be instructed not to blow forcefully as doing so may cause any infection in the nose to spread into the orbit and eyelids.

Sometimes a patient may receive a significant blow to the orbital area, causing the orbital bones to fracture. Usually a bone in the floor of the orbit or medial wall may fracture from the impact, even when not directly hit. This is called a blow-out fracture. If the floor of the orbit gives way, the inferior rectus and oblique may become trapped. If muscles become trapped or dislodged, the eye may not move correctly, and the patient may complain of diplopia.

Of course, the adnexa and bony orbit are not the only areas susceptible to contusions from explosions or blows to the orbit, the globe can also be damaged. Contusions to the globe can lead to prolapse of the intraocular tissues, vitreous hemorrhage, retinal detachment, dislocated lens, and various blood vessel ruptures.

If there is enough force, vessels in the iris may hemorrhage. You can see the blood pooling in the anterior chamber as a result. Blood which accumulates in the anterior chamber is called a hyphema and can block the trabecular meshwork. If this happens, the pressure in the eye can elevate, leading to glaucoma.

Many of these non-war related ocular injuries represent immediate concerns with contusions to the globe. But there are also some long-term complications, including glaucoma years after the injury, cataracts, band keratitis, and phthisis (disorganized and shrunken eyeball).

Sympathetic ophthalmia is another very interesting condition. This condition manifests itself in the uninjured eye from a couple of weeks to a year after the initial injury. The good eye seems to sympathize

with the injured eye and may start to present symptoms (e.g., pain, various visual problems, and eventually blindness). Because of this phenomenon, surgeons tend to enucleate the nonfunctioning-injured eye before the uninjured eye starts to show symptoms.

## Hyphema

As mentioned earlier, hyphema is when blood enters the anterior chamber of the eye (fig. 3-10) caused by blunt trauma to the eye.

Sometimes the eye receives a blow that doesn't fracture the bony orbit, but it may have been enough trauma to cause the iris to bleed. Remember the iris is quite vascular (part of the uveal tract), and a strong blow to the eye can traumatize the iris enough to cause blood to leak from it. This bleeding into the anterior chamber can cause a decrease of vision, since the aqueous is clouded by blood.

If blood is visible to the naked eye, you'll see it floating and settling in the anterior chamber. The problem with all the blood cells floating around in the anterior chamber, besides reducing VA, is it may plug up the trabecular meshwork and prevent maximum drainage of the aqueous. This could lead to a rise in IOP, and subsequently, cause glaucoma.

As with any blunt trauma to the eye, iritis is also likely, making the patient photophobic. Another sign of hyphema would be irregular pupil size and shape in the traumatized eye.

Treatment for hyphema consists of a thorough dilated exam to ensure the retina and other internal structures of the eye are not damaged. Then, the patient should be put on homatropine, a cycloplegic agent to keep the eye dilated and the ciliary body paralyzed. This prevents the iris from moving, which is much more comfortable for the patient and helps prevent a synechiae (adhesion) from occurring between the inflamed iris and the crystalline lens or cornea.

Confine the patient to bed rest for about five days depending on the severity of the problem, and ensure the patient is seen each day after the trauma to check IOP, and monitor the clearing of the anterior chamber. Hyphema is vision threatening and should be treated as a serious problem.

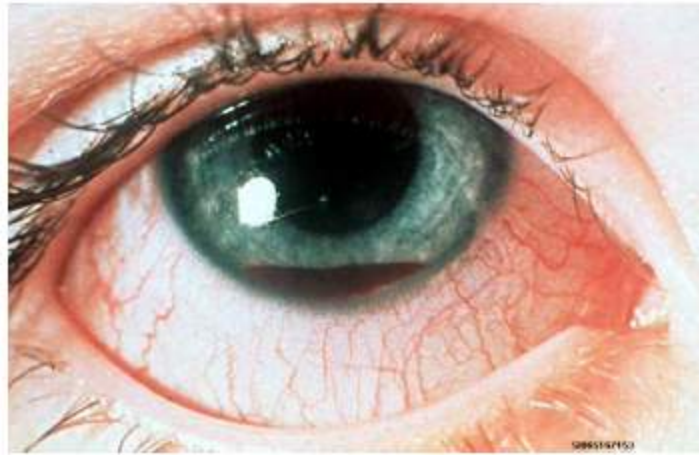

Figure 3-10. Hyphema.

---

## Proptosis

What can cause the eye to protrude from its socket? Anything taking up space in the orbit of the eye such as inflammation of the eye, inflammation of the cells surrounding the orbit (orbital cellulitis), a tumor behind the eye, optic nerve inflammation, a hyperthyroid condition, or bleeding and swelling behind the eye due to trauma. Any of these conditions push the eye forward; this protrusion of the eye is called proptosis (fig. 3-11).

In cases where only one eye is affected, an obvious indication is the eyelids of the affected eye look as if they are open wider than the other eye's lids. What causes this appearance? The more "open" eye is protruding outward from the socket due to any of the aforementioned conditions. A device called an exophthalmometer can measure the amount of protrusion.

If an eye is proptotic due to trauma, do not try to "push" the eye back in the socket. Just loosely cover the eye with a moist dressing to keep the ocular tissues from drying out, and get the person to a doctor immediately.

A hazard of a proptotic eye is the cornea drying out (desiccation). This is because the eyelids may not be able to completely cover the eye since the eye is protruding out of the socket.

Proptosis is a serious condition because it indicates a serious problem is occurring in or around the eye. Any number of things could be wrong and in need of care (e.g., a tumor needs excision, the thyroid needs treatment, an infection needs attention, etc.). A patient with a proptotic eye should have their pupils, vision, extraocular motility, and color vision checked. Then send the patient to an ophthalmologist or optometrist for further diagnosis and treatment.

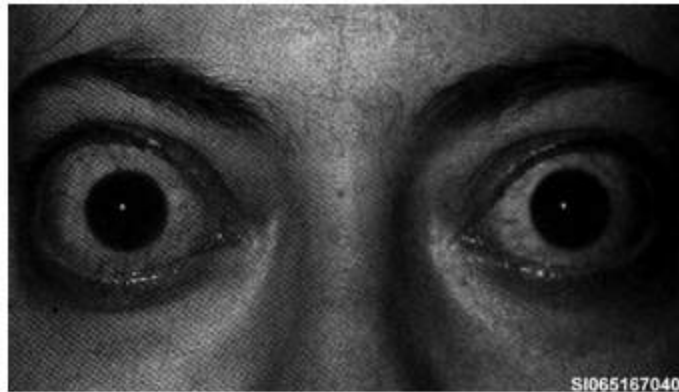

Figure 3–11. Bilateral proptosis (exophthalmos).

## Fractures of the Bony Orbit (“Blowout Fracture”)

Blowout fractures can occur after a blunt injury to an eye. The eye is so compressed in the socket at the time of the blunt trauma that something must give. The weaker bones are so stressed they literally “blowout” or fracture. The most likely section of bone to give is the thin portion of the maxilla covering the infraorbital groove. The inferior oblique or inferior rectus muscle may become incarcerated at the fracture site. The other likely site for a blowout fracture is the ethmoid, which is the weakest bone in the orbit. If the ethmoid blows out, the medial rectus is usually affected.

Signs and symptoms of a blowout fracture are pain, diplopia (double vision), and nausea. Movement of the eye can be limited if extraocular muscles are trapped in the blown-out bone. Most people think this type of injury is an emergency, but depending on the severity, there is little danger in waiting 7–10 days to evaluate whether surgery is needed. Often, a trapped muscle can free itself, and the body heals the fractured area with time.

It doesn't take much to figure out that a patient with a black eye, pain with eye movement, nausea, and complaining of diplopia probably has a blowout fracture. Realistically, most cases have much subtler signs and symptoms. This is another example when a good case history is crucial.

In addition to the case history, check the patient's vision and extraocular motility. Pain during eye movement and restrictions in various positions of gaze provide additional indicators there is trapped muscle in a broken bone of the orbit. If this is the case, the patient needs to see the eye doctor for further testing and evaluation. Hopefully, the trapped muscle frees itself, and the problem is resolved without surgical intervention. If not, the only alternative is surgery to free the muscle. A blowout fracture is a serious ocular problem and needs to be seen quickly.

## Perforating Injuries

Anytime the eye is perforated, you have an ocular emergency. A perforating injury can involve something as big as a screwdriver to something as small as a sliver of glass making a very small hole. Obviously, the extent of damage varies greatly. Either way, the opportunities for infection of the inner eye, loss of aqueous or vitreous humor, and damage to internal ocular structures are multiplied several times when the eye is actually perforated.

If an object is protruding from the eye (fig. 3-12), do not attempt to remove it or anchor it in place.

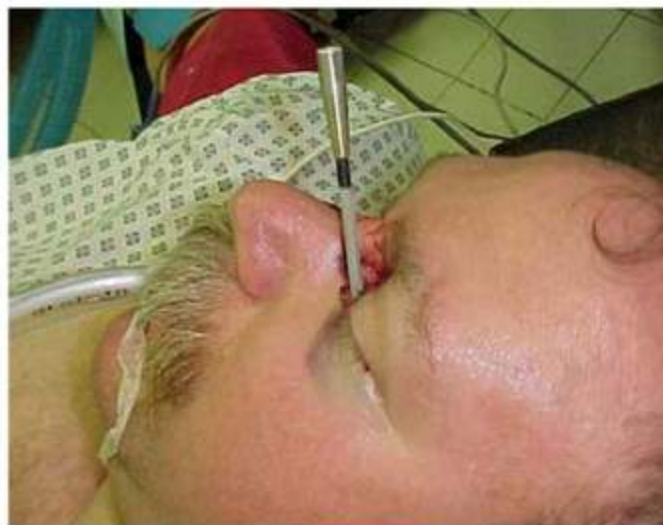

Figure 3-12. Penetrating injury.

---

If the object is not too large, try to cover the eye to protect it from further damage, but if the object hits the protective covering, remove it before more damage occurs. It's useful to patch the uninjured eye to prevent it from looking around. This minimizes the movement of both eyes.

Obviously, a penetrating injury caused by a large item requires the immediate attention of an eye surgeon. Lay the patient on his or her back to retain the ocular fluid, and then transport the patient immediately, but gently, to surgery.

A minor perforating injury caused by a small piece of metal or glass entering the eye at high speed can hide some serious dangers. A small hole in the globe of the eye can quite easily go undetected. The most important thing you can do is get a thorough case history of the injury. What was the person doing at the time of the injury? What material was present? What did the person feel happen? Where does the eye hurt? Are there any other symptoms (e.g., photophobia, decreased vision in the injured eye, or excessive tearing)? It's critical you be thorough. You may find the clues leading the doctor to search for and find the perforating injury.

A rushed job during the case history may cause telltale clues to be overlooked. The consequences can result in a possible misdiagnosis of a condition requiring a pressure patch. As you can imagine, this can have devastating consequences. The pressure patch can force fluid out, which causes the IOP to drop, the retina becomes extremely susceptible to detachment, and the iris can become inflamed and adhere to the crystalline lens or cornea, causing an angle closure.

How do you know if the eye is penetrated? The eye may be more watery than expected from a simple corneal abrasion, potentially from intraocular fluid leaking out. Not an easy sign to quantify, but it's something to keep in mind. What about bleeding? If a highly vascularized structure is hit, like the iris, there may be some bleeding in the anterior chamber of the eye. This is always a serious sign of trouble. But if nothing vascular was hit by the penetrating object, there may be little to no bleeding of the eye. Again, not the ideal clue, but it may help.

So how can you and your doctor determine if a small FB has penetrated the eye? If the eye is leaking intraocular fluid, the area of the penetration has the intraocular fluid leaking from it. If fluorescein is put in the eye and is pushed away from an area of the eye, you have what is called a "positive Seidel," a sign that fluid is leaking out of the eye. The fluorescein being pushed away from the perforation helps you find its location.

Perforating injuries can also induce a traumatic cataract. If an object, large or small, hits the crystalline lens, it can cause it to cloud. A large object penetrating the eye often damages the iris, inhibiting its ability to do its job correctly due to the damage. A foreign object anywhere in the eye induces an inflammatory response as the body tries to “kill” the invading object. Iritis, keratitis, posterior uveitis, vitreitis, and more can result. If the perforating object were dirty, infection is a major concern and healing is inhibited. A penetration of the globe requires immediate attention. If the possibility of a penetrating injury exists, get the person in and seen by a doctor. Again, a good case history helps in determining if you should be looking for a perforating injury or not.

Take all possible injuries serious and make your case history thorough. If there is any question about what to do with a patient, always refer to the doctor or another primary care manager (PCM) if a doctor is not available.



### **Purpose of Eye Irrigation**

The reason for eye irrigation is to remove foreign objects or substances from the eye.

Normally, the eye is irrigated after an acid, alkali, or other chemical is splashed into it. Chemicals splashed into the eyes require immediate irrigation.

### **Performing Eye Irrigation**

Irrigation can be performed at a sink (fig. 3-13), shower, water hose, water fountain, or anywhere water is available.



Chemicals, if allowed to remain in the eye, cause serious damage to the cornea, conjunctiva, and ocular adnexa. When irrigating, it's extremely important the eyes be kept open.

Patients who have had a chemical splashed in their eyes go into a blepharospasm (inability to open the eyelids due to a muscle spasm of the orbicularis oculi). The use of a topical ophthalmic anesthetic relieves the pain and lid spasm. Always check with the doctor first before putting any medication in a patient's eye.

The simplest method of irrigation in the clinic is to use the Morgan Lens. This is like a CL with an irrigation tube attached. After the eye is anesthetized, insert the Morgan Lens, hook the tubing into an elevated bag of sterile saline, and let gravity and the lens do their job. This system provides a steady irrigation and is easiest on you and the patient.

If you do not have a Morgan Lens, you must irrigate by squirting Dacriose or saline across the eye, going from the nasal side toward the temporal side. This flushes the harsh chemicals away from the lacrimal drainage system, minimizing damage to it. It also minimizes the amount of chemical being washed across the face. The technician must hold the eyelids open to perform irrigation.

The best method to hold the eyelids open is to use a cotton or paper towel, and firmly press the eyelids against the bony orbit. Continue irrigation until the doctor instructs you to stop. You may go through several bottles of fluid, but don't worry about it. You can order more saline. Your patient's vision depends on the effectiveness of your irrigation.

Any technician receiving a phone call where a patient has spilled a chemical in the eye must tell the person to start irrigating the eye immediately and to continue irrigation for a minimum of 30 minutes. When they seek treatment, instruct the person to bring the chemical container with them so it can be analyzed. Remember, chemicals splashed in the eyes are a true emergency and must be treated as such because they can cause blindness.

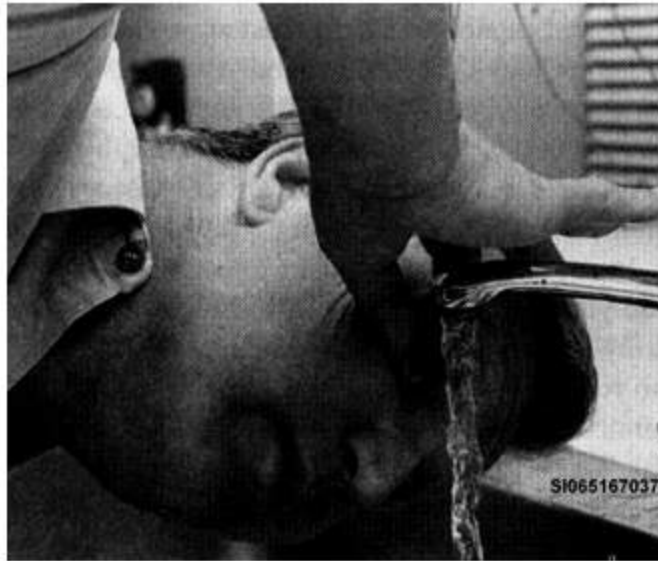


Figure 3-13. Emergency eye irrigation by the patient.

---

---

**Below is the procedural steps for how to irrigate the eye. Click on the blue "start" button to learn the steps.**

---

## Introduction



How to irrigate

## Step 1

### Step 1

Lay the patient back on an exam bed or in the exam chair.

## Step 2

## Step 2

Instill two to three drops of anesthetic in the appropriate eye (with doctor approval only).

### Step 3

## Step 3

Have the patient fixate on a target on the ceiling.

## Step 4

### Step 4

Insert the Morgan Lens<sup>®</sup>, hook up saline, and begin the flow of irrigation. If the Morgan Lens<sup>®</sup> isn't available, squirt sterile saline across the eye going from the nasal to the temporal side, ensuring the cornea, bulbar conjunctiva, and palpebral conjunctiva are saturated. Irrigate for a minimum of 30 minutes.

## Step 5

### Step 5

Use an emesis basin, waste basket, or towels to catch the solution draining from the eye.



## Step 6

### Step 6

The doctor uses litmus (pH) paper to determine whether the eye has been irrigated enough.

Litmus (pH) paper indicates if the eye still has any acid or alkali still present. Irrigation continues until the litmus (pH) paper indicates the eye is at neutrality (pH 7.3–7.7 is normal for the eye).

## Step 7

### Step 7

Re-test with the litmus (pH) paper 5–10 minutes later. When the pH is neutral (clear), instill an antibiotic and patch the eye per the doctor's instructions.

## Summary

### REMEMBER:

Any technician receiving a phone call where a patient has spilled a chemical in the eye must tell the person to start irrigating the eye immediately and to continue irrigation for a minimum of 30 minutes.

When they seek treatment, instruct the person to bring the chemical container with them so it can be analyzed. Remember, chemicals splashed in the eyes are a true emergency and must be treated as such because they can cause blindness.



Complete the content above before moving on.

## Eye Patching

The idea behind a pressure patch is to keep the eyelids of the injured eye closed and help with pain control. A good patch is the sign of a good technician. Take your time and do the job correctly.

---

**Below is the procedural steps for how to pressure patch the eye. Click on the blue "start" button to learn the steps.**

---

# **Introduction**

## **Pressure patching**

Below are the steps to applying a good pressure patch, once an antibiotic ointment has been instilled in the eye. Again, only administer medication upon the approval of a provider.

## Step 1

### Step 1

Get two eye pads, some  $\frac{1}{2}$ "-wide fabric or plastic surgical tape, and a few alcohol pads. Always wash your hands after getting the material and before touching the patient's eye.

## Step 2

### Step 2

If possible, have the patient lie down on a minor surgery bed or recline the patient in an ophthalmic chair.

### Step 3

## Step 3

Once the patient is in a comfortable position, have the patient close both eyes. This helps to keep the eyes relaxed while applying the patch to the injured eye.

## Step 4

### Step 4

With an alcohol pad, wipe the forehead and cheek off. This removes the make-up and facial oils that prevent your tape from sticking to the patient. Remember, this patch must stay on for 12–24 hours. Before throwing the alcohol pad away, wipe off the edge of the table or armrest where you want to place your pre-torn tape strips.



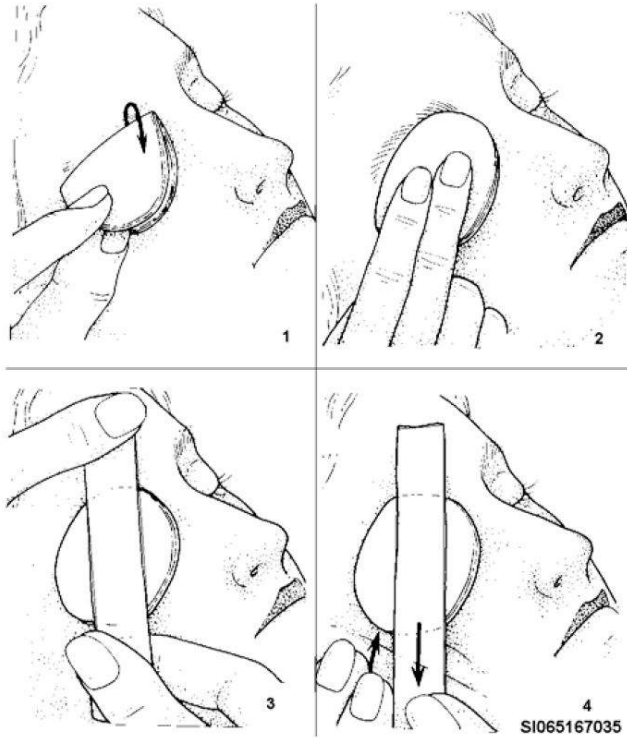
## Step 5

### Step 5

Using the ½"-wide fabric or surgical tape, tear off six, 8" long pieces. The tape must be long enough to go from forehead to cheek and have good surface contact with the skin. Place the strips of tape on the edge of a table or the armrest of the ophthalmic chair that you wiped with the alcohol pad, so they are easily accessible for you to reach.

## Step 6

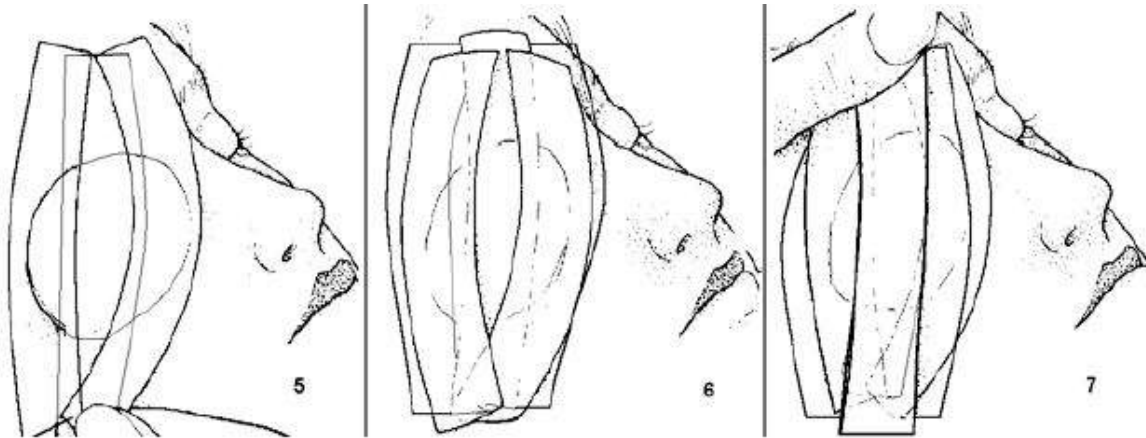
### Step 6



Place an eye pad, folded in half, over the eye to be patched, and then apply a second pad (not folded) over the folded pad (fig. 3-14). If the patient has deep sockets, you may need to use an additional pad to ensure enough pressure is applied to the closed eyelid to keep it closed.

## Step 7

### Step 7



Have the patient hold the pads in place with his or her finger. Grab a strip of tape and put it over the center of the eye pad. Angle your tape to go from the center of the patient's forehead to the temporal side of the mouth. Ensure the tape is away from the margin of the mouth, so it doesn't hinder the patient when he or she eats.

Continue to apply the strips, starting at the center of the forehead and angling the tape to enclose both sides of the eye patch, and then finishing at the same point on the cheek (fig. 3-15). Save your last strip of tape for the middle of the patch again. Apply all the strips snugly, but be careful to only apply pressure on the bones (forehead and cheek) and not on the eye itself.

## Step 8

### Step 8

Have the patient open his or her eyes. Ask whether the patched eyelid remained closed. If the patient answers “Yes,” things are looking good! If the answer is “No,” or if the patient can feel the eyelid move, try again. Everything must be perfect before the patient leaves. If you can’t get the patch to hold the eyelid closed, get some assistance to see what you are doing wrong.

## Summary

### Additional patient instruction

Before the patient leaves, advise him or her of the following:

Minimize talking because it loosens the patch.

No heavy exertion because it leads to sweating, which causes the patch to loosen and fall off.

No driving, if at all possible, because stereopsis (fine-tuned depth perception) is lost, as is a substantial portion of the VF on the patched side.

If the patch comes off or becomes loose, the patient should return to the clinic to have a new one applied. If it's after duty hours, the patient should just leave the patch off, and keep the eye closed as much as possible. If the patient tries to reapply the patch, it may do more harm than good.

Advise the patient it's best to just leave it alone.

Here are some final thoughts on patching. A patient with a patched eye must be seen within 24 hours. If the patient is patched on Friday, someone competent needs to see him or her again on Saturday. Also, never patch an eye with an infection because warm, dark, moist places are terrific for growing germs.



Complete the content above before starting the self-test questions.

**Self-Test Questions.** After you complete these questions pertaining to war related ocular injuries, you may check your answers at the end of this module.

1. Battlefield mechanical injuries are categorized by what?

Type your answer here

---

SUBMIT

2. Sources of munitions include what?

Type your answer here

---

SUBMIT

3. Name sources that can be included in non-munitions.

Type your answer here

---

SUBMIT



Complete the content above before moving on to the questions in the next section.

**Self-Test Questions. After you complete these questions pertaining to non-war related ocular injuries, you may check your answers at the end of this module.**

1. What is an FB?

Type your answer here

---

SUBMIT

2. What happens when a steel FB gets in the eye?

Type your answer here

---

SUBMIT

---

3. What should be tried first when attempting to remove a superficial FB?

Type your answer here

---

SUBMIT

4. Why might a patient complain of an FB sensation even after it's removed?

Type your answer here

---

SUBMIT

5. What should be done with a patient who has an eye penetration by a FB?

Type your answer here

---

SUBMIT



6. What is wrong with pressure patching an eye that has been penetrated by an FB?

Type your answer here

SUBMIT

7. What should you do with a patient whose eye has a large wound and is leaking aqueous or vitreous humor?

Type your answer here

SUBMIT

8. When can a corneal abrasion or scratch have a long-term effect on VA?

Type your answer here

---

SUBMIT

9. How is a corneal abrasion usually treated?

Type your answer here

---

SUBMIT

10. Name two FBs that are inert materials.

Type your answer here

---

SUBMIT

11. If a person gets a thermal burn in the eyes, what can you do for the person until the doctor becomes available to treat the injury?

Type your answer here

---

SUBMIT

12. What is the immediate treatment for a chemical burn?

Type your answer here

---

SUBMIT

13. Why are acid burns usually less destructive than alkali burns?

Type your answer here

---

SUBMIT

14. What are some examples of alkaline (Alkali) agents?

Type your answer here

---

SUBMIT

15. What type of paper is used to test the amount of acid or alkali present in an eye?

Type your answer here

---

SUBMIT

16. What eye pH reading is considered "neutral?"

Type your answer here

---

SUBMIT

17. What does UV radiation do to the cornea?

Type your answer here

---

SUBMIT

18. An “eclipse burn” to the retina is caused by which type of light ray?

Type your answer here

---

SUBMIT

19. What type of damage can occur due to X-ray exposure?

Type your answer here

---

SUBMIT

20. Which type of upper eyelid laceration is more damaging: horizontal or vertical?  
Why?

Type your answer here

---

SUBMIT

21. Contusions to the globe can lead to what conditions?

Type your answer here

---

SUBMIT

22. Blood in the anterior chamber of the eye caused by blunt trauma to the eye is known as what?

Type your answer here

---

SUBMIT

23. What are some problems with blood cells floating around in the anterior chamber?

Type your answer here

---

SUBMIT

24. What action should you take if an eye is proptotic due to trauma? What should you not do?

Type your answer here

---

SUBMIT

25. What is a hazard associated with a proptotic eye?

Type your answer here

---

SUBMIT

26. When is a 'blowout' fracture likely to occur?

Type your answer here

---

SUBMIT



27. What is a 'blowout' fracture?

Type your answer here

---

SUBMIT

28. What is a positive Seidel a sign of?

Type your answer here

---

SUBMIT



Complete the content above before moving on to the questions in the next section.

**Self-Test Questions.** After you complete these questions pertaining to the purpose of eye irrigation, you may check your answers at the end of this module.

1. What is the purpose of eye irrigation?

Type your answer here

---

SUBMIT

2. If a chemical is splashed into the eyes, where can a patient irrigate his or her eyes?

Type your answer here

---

SUBMIT

3. What is blepharospasm?

Type your answer here

---

SUBMIT

4. What relieves the pain and lid spasms for patients who get a chemical burn to their eyes and experience blepharospasm?

Type your answer here

SUBMIT

5. When irrigating without a Morgan Lens, from which direction do you squirt the sterile saline? Why?

Type your answer here

SUBMIT



Complete the content above before moving on to the questions in the next section.

**Self-Test Questions. After you complete these questions pertaining to eye patching, you may check your answers at the end of this module.**

1. What is the purpose of a pressure patch?

Type your answer here

---

SUBMIT

2. What is the purpose of using an alcohol pad when putting on a pressure patch?

Type your answer here

---

SUBMIT

3. Where does the last strip of tape go when applying a pressure patch?

Type your answer here

SUBMIT

4. What advice do you give a patient who has just had a patch placed over one eye?

Type your answer here

SUBMIT

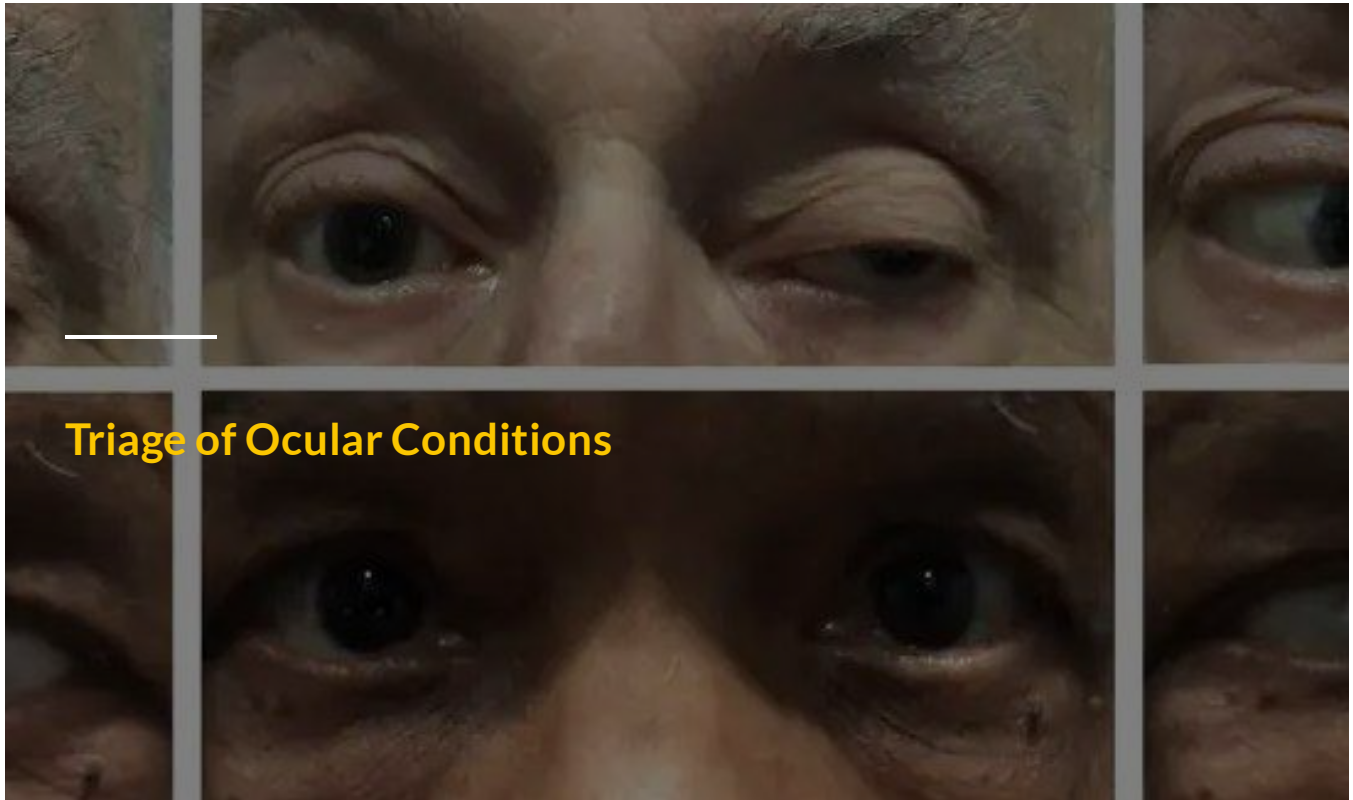
5. What should a patient with a pressure patch do if the patch falls off or comes loose before the follow-up appointment?

Type your answer here

SUBMIT



Complete the content above before moving on to the rest of the lesson.



## Triage of Ocular Conditions

Running a clinic can be hectic. Scheduling patients, answering phones, and keeping staff assigned to the proper duties can keep you on your toes. In addition to the day-to-day activities, you must be able to handle emergency situations. You need to triage which patients need to see the doctor immediately, the same day, or who can wait a few days.


Screen patients, using a priority system to implement a rapid and efficient process. This section covers signs and symptoms, and places them into a meaningful classification. This provides you with an orderly way to think about a disorder, disease, or condition. Not all scenarios can be covered, but the information should give you a good starting point.

## Ocular Emergencies

Triaging patients over the phone is a huge responsibility and a challenging task. It's nearly impossible to screen a large number of patients adequately in just a matter of minutes. If you're to err in your triage, errors of inclusion instead of exclusion are preferred. Turning away a patient with a serious eye condition is

unacceptable. If there is even the slightest possibility the patient has a serious eye condition, have them come in for an evaluation.

TRUE EMERGENCIES	URGENT SITUATIONS	SEMIURGENT SITUATIONS
<p>True emergencies must be seen within minutes. The following are some examples of true emergencies:</p> <ul style="list-style-type: none"><li>• CRAO</li><li>• Chemical burns</li><li>• Sudden loss of vision</li><li>• Penetrating injuries to the globe</li></ul>		
TRUE EMERGENCIES	URGENT SITUATIONS	SEMIURGENT SITUATIONS
<p>Urgent cases, such as the following, should be seen the same day:</p> <ul style="list-style-type: none"><li>• FB</li><li>• Hyphema</li><li>• Acute iritis</li><li>• Corneal ulcer</li><li>• Lid laceration</li><li>• Corneal abrasion</li><li>• Retinal detachment</li><li>• Blowout fracture of the orbit</li><li>• Acute angle-closure glaucoma</li></ul>		

TRUE EMERGENCIES	URGENT SITUATIONS	SEMIURGENT SITUATIONS
<p>The following cases should be seen within days and may vary depending on the patient's symptoms:</p> <ul style="list-style-type: none"><li>• Optic neuritis</li><li>• Ocular tumors</li><li>• Protrusion of an eye</li><li>• Old retinal detachment</li><li>• Previously undiagnosed glaucoma</li></ul>		
<div> Complete the content above before moving on.</div>		

## Emergency Ocular Conditions

Ocular emergencies can cause permanent vision loss if they are not recognized and treated promptly. Delaying treatment for any reason can have devastating effects to a patient's sight. For this reason, patients complaining of any of the symptoms below should be seen within the hour.

### Sudden Loss of Vision in One Eye Without Pain

In adults, sudden loss of vision in one eye without pain can be a symptom of a CRAO, CRVO, vitreous hemorrhage, or retinal detachment.

CRAO requires the most urgent care, since blindness will occur if the artery is occluded for an hour or longer. In reality, no more than 15 minutes should pass between the initial event and treatment; however, there have been incidents of some vision being restored if treatment is rendered within 90 minutes.

Because the symptoms for CRAO are similar to other conditions, any patient who complains of sudden vision loss in one eye must be treated as an emergency case which requires appropriate immediate



prioritization.

## Vein Occlusion

Not as potentially devastating as a CRAO, a CRVO, or BRVO, but can still result in a significant loss of vision. In CRVO, the blockage produces hemorrhages located primarily at the posterior pole but can be seen throughout the fundus. In BRVO, the occlusion causes hemorrhages located throughout the blocked vein.

## Urgent Ocular Conditions

As stated earlier, urgent situations should be seen the same day. The symptoms listed below need to be triaged and evaluated during a same day appointment.

### Painful Red Eye

A painful red eye can usually be attributed to four possible conditions:

- acute glaucoma
- acute conjunctivitis
- acute iritis
- acute keratitis

Though less common, but of grave concern, herpes simplex keratitis also includes a painful red eye as one of its symptoms. With herpes simplex keratitis, the pain actually decreases over time as the illness worsens. If the eye is left untreated, the cornea may eventually scar. In some cases, the scarring may be severe enough to warrant a corneal transplant. Because of this, you must keep this disorder in mind when triaging patients who describe to you what sounds like a simple case of conjunctivitis.

### Swollen Eyelid

An infection of the sweat and oil glands of the eyelid is the most common cause of acute eyelid swelling. An infection of the sweat gland or styte, and an infection of the oil gland or hordeolum is usually associated with eyelid swelling.

Another cause of eyelid swelling is from an insect bite. Often the swelling is so severe that the eyelid can't be opened. Finally, an allergic reaction can also lead to acute eyelid swelling. The reaction could be attributed to a number of causes, but the swelling will usually be bilateral and is often accompanied by itchiness.

## Flashes of Light

Flashes of light can be a symptom of a retinal detachment and should be seen promptly. Although important to be seen, time is not as critical as some other conditions, as days or weeks can pass between diagnosis and treatment. Other conditions with flashes of light as symptom include migraines and vitreous detachments.

## Double Vision or Eyelid Droop

Double vision is a possible sign that an extraocular muscle has become weak or paralyzed. It can also be a sign of disease of the brain itself, the nerves running from the brain to the extraocular muscles, or the extraocular muscles themselves.

Double vision is also associated with brain tumors, aneurysms, myasthenia gravis, and strokes. An eyelid droop can be a result of an issue with the same nerve as the one that innervates many of the extraocular muscles.

---

## Priority Ocular Conditions

Priority conditions are those that don't warrant an ophthalmic emergency, but do call for a slightly elevated cause for concern. Symptoms may lead to an acute emergency, and therefore, these conditions should be seen within the next few days.

---

### Halos around Lights —

The most common cause of seeing halos around lights is from the formation of mucous deposits on the surface of the conjunctiva. This can be associated with chronic conjunctivitis, allergies, and other ocular irritations. Early cataracts can also cause this symptom.

Seeing colored halos around lights can be a sign of an impending case of acute angle-closure glaucoma. Halos are a result of edema fluid forming in the stroma of the cornea. Elevations of ocular pressure can cause episodes of seeing colored rings around lights. These instances are so mild though, that patients may not see them as a concern.

## Headaches —

Patients are commonly referred for an eye examination because they are suffering from headaches. Of all the causes of headaches, rarely is it attributed to an ocular dysfunction. Ocular headaches are typically a result of prolonged near work or after accomplishing a task that requires a good amount of concentration, such as driving or watching TV or movies.

The site of the headache can vary but is most often in or behind the eyes, around the eyes, or in the temples. A patient complaining of headaches should be evaluated since headaches may be a symptom of a serious neurologic or systemic disorder. Many brain tumors are first noticed in ocular assessments.

## Lost or Broken Glasses —

For patients with high prescriptions, a pair of lost or broken glasses can be debilitating. A high myope can't drive a car, a high presbyope can't read, and someone with a high astigmatism would suffer all around. Though this is an opportunity to remind your patients of the importance of maintaining a back-up pair of glasses, for some patients lost or broken glasses can leave them completely incapacitated, and this is your opportunity to improve their vision.

## Gradual Loss of Sight in Quiet Eyes —

The gradual loss of sight in quiet eyes is a deterioration of sight without any obvious external signs of ocular disease. In children, this is usually from uncorrected refractive error, which is often corrected with glasses. As adults, around the age of 40, many start to struggle with difficulties focusing up close and require correction for presbyopia. Besides these typical vision losses associated with refractive error, the next common cause of gradual vision loss is from cataracts.

Macular disease can also bring about vision loss in a slow, gradual process, though it may also strike acutely. With macular disease, central vision is lost (cannot see straight ahead), but peripheral vision is maintained.

Patience and understanding is extremely important when triaging patients. Not all calls to the office are emergencies or urgent. But remember, the patient feels his or her problem is serious and of great importance. Do not treat a patient's complaint as trivial and dismiss him or her.

Discrete questioning techniques, and a solid history allows you to differentiate between urgent and non-urgent. If there is any question as to what you should do with a symptomatic patient, ask an optometrist, ophthalmologist, or any medical provider. Prior to leaving the medical facility, ensure each patient is evaluated and released by a licensed medical professional. Sending a patient home is a type of decision you cannot make on your own!



Complete the content above before moving on to the self test questions.

**Self-Test Questions. After you complete these questions pertaining to ocular emergencies, you may check your answers at the end of this module**

1. List four true ocular emergencies that need to be seen within minutes.

Type your answer here

SUBMIT

2. What classification of cases should be seen the same day?

Type your answer here

---

SUBMIT



Complete the content above before moving on to the self test questions.

**Self-Test Questions. After you complete these questions pertaining to emergent ocular conditions, you may check your answers at the end of this module**

1. What condition, that has sudden loss of vision in one eye without pain as a symptom, requires the most urgent care?

Type your answer here

---

SUBMIT

2. You receive a phone call from a patient complaining of sudden vision loss in one eye. The patient has no other symptoms, so you're unsure what might be the cause. How should you treat this case?

Type your answer here

SUBMIT



Complete the content above before moving on to the self test questions.

**Self-Test Questions. After you complete these questions pertaining to urgent ocular conditions, you may check your answers at the end of this module**

1. Although the pain from herpes simplex keratitis may decrease over time, why does the condition still need to be seen the same day?

Type your answer here

SUBMIT

2. What condition, that has flashes of light as a symptom, warrants the patient to be seen promptly?

Type your answer here

SUBMIT



Complete the content above before moving on to the self test questions.

**Self-Test Questions. After you complete these questions pertaining to priority ocular conditions, you may check your answers at the end of this module**

1. Priority ocular conditions need to be seen within what timeframe?

Type your answer here

SUBMIT

2. Although headaches are rarely attributed to an ocular dysfunction, why should a patient complaining of headaches still have an ocular assessment?

Type your answer here

SUBMIT

3. In children, what usually causes the gradual loss of sight in quiet eyes?

Type your answer here

SUBMIT



Congratulations! You have completed Module 2, Lesson



## Lesson 4: Ophthalmic Pharmacology

---

### Main Points

1. Principles, Complications, and Actions in Ophthalmic Pharmacology
  - a. General principles of ophthalmic pharmacology
  - b. Complications and actions of ophthalmic drugs
  - c. Autonomic medications and the body's nervous system
2. Ophthalmic Medications
  - a. Mydriatic and cycloplegic medications
  - b. Anti-glaucoma/intraocular pressure lowering medications
  - c. Ophthalmic anesthetic medications and stains
  - d. Anti-allergic, anti-inflammatory, and anti-infective ophthalmic medications
  - e. Ophthalmic health enhancing products

---

In the health care professions, medications are “tools” that are used frequently to test and treat patients. When used appropriately, like any other tool, they are a fantastic asset. To use drugs appropriately, health care professionals must familiarize themselves with the general principles, complications, and actions of the medications involved. Additionally, a true professional should also be educated on those drugs specific to his or her specialty.

In the world of pharmacology, there are many drugs unique to eye care. As an ophthalmic technician, you’ll administer these specific medications; therefore, it’s essential you understand their uses, effects, and complications. Some technicians believe it’s the doctor’s job to know about ophthalmic medications. But, these technicians fail to realize they are the doctor’s backup and need to be well- trained on ophthalmic medications.

You, the technician, administer the medications on most occasions. It’s your responsibility to educate your patients about the effects of prescribed medication and the possible reactions. You’re the one explaining the how, when, and why about the medication in order to get the best results with the fewest side effects. You’re an important link in the safe and effective use of ophthalmic medications. This lesson will provide you with a cursory knowledge to help you understand the many aspects of ophthalmic pharmacology.

[Click here to begin Lesson 4.](#)

# Principles, Complications, and Actions in Ophthalmic Pharmacology

We use drugs to test the eyes, diagnose problems with the eyes, and treat various eye conditions. Different medications make the pupils big or small, stimulate or paralyze accommodation, and decrease aqueous production or help increase aqueous outflow from the eye. They can also reduce swelling or stain tissue cells. If there is a treatment or procedure involving the eyes, there is typically a medication to help out.

To test, diagnose, and treat your patients accurately, you'll need to use medications. The following lessons give you the knowledge to understand the numerous medications used in military eye care— how they're maintained, how they work, how they're administered, and some of their side effects.

## General Principles of Ophthalmic Pharmacology

Before discussing specific medications and some of their side effects, it's valuable to have some general knowledge about them. This includes information on how to maintain medications within your clinic, basic medication principles (e.g., tolerance, tonicity, sterility, stability, and penetration), and various delivery methods to patients (e.g., topical application, continuous release delivery, and systemically). Knowledge of the basic principles helps in your understanding the subtle differences in medications and why your doctor may choose one drug over another, despite both performing the same basic action.

## Maintaining Ophthalmic Medications

Since missions vary from base to base, the medications your clinic maintains may vary from another clinic's medications; therefore, the procedures required to maintain these medications may also vary. This could be due to variants in the types of medications stocked or storage capabilities.

The medications maintained by your local pharmacy and the policies and procedures of your local military treatment facility (MTF) are adopted by the pharmacy and therapeutics (P&T) function of the medical staff and approved by the MTF commander. The decisions of the P&T function will dictate what medications, and in what quantities, are carried within the clinic. This determines what's on the authorized drug list (ADL). You should always check with your local pharmacy personnel to get specific drug maintenance instructions for the medications stocked within your clinic.

While there may be slight variances in drug maintenance procedures clinic to clinic, there are some basic inventory and infection control practices that all clinics must follow. The checklist below encompasses these general principles. The checklist includes items that must be assessed or inspected, at least on a monthly basis.

As stated previously, your local policy may have additional requirements. Always contact your local pharmacy section for detailed information on your clinic's specific medications. AFI 44-102, *Medical Care Management*, and AFI 44-108, *Infection Prevention and Control Program*, are also beneficial resources.

CLINIC INSPECTION CHECKLIST		
DATE		
		REMARKS
1. Stock Levels a. Ensure quantities do not exceed the maximum allowed on the ADL.		
2. Security a. A single lock is sufficient for non-controlled medications. b. If applicable, a double lock is required for controlled items.		
3. Uniformity of containers and adequate labeling to include pre-packaged meds from pharmacy a. Ensure lot #, manufacturer, and expiration date are visible and in date. b. Medications expiring first should be placed in a position to be used first.		
4. Refrigeration Storage Conditions (if applicable) a. The medication storage refrigerator's temperature should be monitored/documented daily. b. Ensure only medications are stored in the refrigerator. c. The temperature must be between 36-46°F.		
5. Deteriorated or Outdated Drugs a. Multi-dose vials must be dated when opened & used within 28 days (unless the manufacturer specifies a different expiration date). 1. Opened multi-dose vials should be labeled with the expiration date which is 28 days after initial use (unless the manufacturer specifies a different expiration date). b. When only a month and year of expiration are provided for a drug, the drug may be used until the last day of that month. c. Sterile irrigation solutions are used for one		

CLINIC INSPECTION CHECKLIST		
DATE		
		REMARKS
patient only and are disposed of appropriately. They are not dated or saved for later use, even on the same patient.		
6. Separation of internal from external medications (if applicable) a. Ensure internal and external medications are divided, preferably on different shelves or compartments.		
Inspection completed by:		
Printed Name: _____		
Signature: _____ Date _____		
NCOIC/OIC Review (if applicable):		
Printed Name: _____		
Signature _____ Date _____		

## Tolerance

Tolerance is the ability of a drug to be an effective ophthalmic medication without an ill effect on eye tissues. Irritation of a medicine leads to reduced patient compliance no matter how effective the drug.

Let's say a patient is taking Betoptic for glaucoma. The medication may burn a little when the patient first puts the medicine into his or her eyes. Some people may hardly notice the irritation, while others may find it to be very uncomfortable. This is to say tolerance levels vary. In our example, the patient can't tolerate regular Betoptic, so the doctor may prescribe Betoptic-S, which may be more tolerable.

A big factor in a medication's tolerability is the potential of hydrogen (pH) of the drug. Drugs with a pH of 7 are neutral. Above 7 is more alkaline and can be irritating. Below 7 is more acidic, which may be more tolerable. Remember, our tears are slightly alkaline and they tend to neutralize acid, making slightly acidic medications easier to tolerate. Normal ranges of pH in ophthalmic solutions run from 3.7–10.5. The eyes best tolerate neutral or slightly acidic medications.

## Tonicity

Tonicity refers to the concentration of a certain chemical in a solution. Our tears have a pH of about 7.4, and a concentration of 0.9 percent sodium chloride (NaCl). Ophthalmic products are generally designed to approximate this pH and NaCl level. When ophthalmic medications stay within a range of  $\pm 0.2$  percent of

our tears' normal NaCl level of 0.9 percent (i.e., between 0.7–1.1 percent NaCl), they are considered to be isotonic, and thus, comparable to our tears' natural tonicity.

What does this mean? These drugs do not cause the eye tissues to absorb fluid, nor do they pull fluid from the eye tissues. Isotonic medications do their job without affecting the fluid level of the eye tissues.

However, if a medication has a concentration of NaCl of 1.2 percent or greater, it's hypertonic, or hyperosmolar, meaning the medication draws fluid away from the eye tissues.

Hypertonic solutions reduce corneal edema (swelling caused by too much fluid absorption of the cornea). Two examples of hypertonic solutions are Adsorbonac and Muro 128. Another hypertonic solution you may hear of is Osmoglyn, which contains glycerin. People having an acute angle-closure glaucoma attack are sometimes made to drink this solution (provided they are not diabetic). Osmoglyn pulls fluid from the body (and the eye) in an effort to reduce IOP.

If a solution has a lower concentration of NaCl (0.6 percent or lower), it's considered to be hypotonic. These solutions or medications act to encourage absorption of fluid into the eye tissues. An example of this is Hypotears, a type of artificial tear solution prescribed for a dry-eye patient to encourage the tissues of the eye to retain more moisture and slowdown the evaporation of fluid from the eye. Using a hypotonic solution is one way to do this.

***NOTE: Not all artificial tears are hypotonic solutions.***

## Sterility

Ophthalmic products come sterilized and sealed by the manufacturer. But what about product sterility after a patient breaks the seal? Bacteriostatic additives, known as preservatives, are frequently added to prevent microorganisms from growing after the container is opened. Benzalkonium chloride, chlorobutanol, and organic mercurials (mainly thimerosal and phenylmercuric acetate) are commonly used preservatives in ophthalmic drugs.

Because of allergic sensitivity problems to preservatives, manufacturers have tried to find less aggravating preservative products. Two are sorbic acid and sodium edentate, which seem to be less irritating to most people.

For those who still can't tolerate any preservatives in their ophthalmic solutions, many manufacturers now make non-preserved sterile saline. Although this prevents allergic reactions, once the solution is opened, there is an increased risk of microorganisms developing. Two ways to slow the development of microorganisms is to keep non-preserved saline refrigerated and avoid touching the dispensing portion of the container to anything.

Preservative-free drugs are typically used in eye surgeries to reduce irritation to open tissues. For eye surgery, individual sterile dose units are used.

Once a medication is opened, any guarantees of sterility are gone. We discussed *Pseudomonas aeruginosa* in a previous lesson. If this organism finds its way into a solution, it can destroy an eye within 48 hours. To avoid contamination after the seal is broken, it's essential the dispensing portion of the bottle not come in contact with anything except the inside of the cap covering it. If an eyelash touches an eyedropper tip, throw the bottle away. Lashes carry a disproportionate amount of bacteria and other microorganisms which quickly contaminate the medication. Continued use on other patients is unethical. You are trying to help people who come to your clinic, not pass on infectious organisms.

Determining the shelf life of a medication is no easy task, so it's always best to err on the conservative side. Refrigeration helps to inhibit bacterial growth. It also helps to maintain the stability of the drops and prevents them from degrading into other components. But refrigeration does not stop bacterial growth, it only slows it down. Disposing of medications when the bottle starts to look old or the solution has changed color goes a long way in preventing microorganisms from growing to harmful levels. Keep in mind, non-preserved medications need to be disposed of much sooner than preserved medications. Your local pharmacy personnel are your best source to help you determine the shelf life of the specific medications used in your clinic.

## Stability

Stability is the tendency of a solution to maintain its original pH level, effectiveness, and form (i.e., liquid solutions shouldn't have crusty stuff in the cap). Virtually all ophthalmic medications are heat- or light-sensitive and can deteriorate over a short period of time when not stored properly.

Notice most topical eye medications are contained in opaque containers and many have a statement on the bottle recommending refrigeration or at least storage within certain temperature parameters.

The exposure to excessive heat and light can cause medications to oxidize. You can see this as a darkening or browning of the medicine. Have you ever taken the cap off a bottle of drops and noticed the threads were a little brown? This is oxidation, and the medication should not be used, even if it hasn't been over 90 days since the bottle was opened.

## Penetration

Penetration is dependent on how the medication is being administered. A drug injected directly into the bloodstream penetrates a lot faster than one taken orally. In an eye clinic, the vast majority of drugs are topically administered via drops directly in the eye.

Topical medication penetration is affected by many different factors. One factor is tears washing away the drop. This shortens the contact time of the drug on the cornea, consequently reducing penetration of the medicine into the eye. To increase the penetration or effectiveness of an eye drop change the following:

- Contact time with the cornea
- Dosage (amount of drug used)
- Frequency (number of times used)
- Viscosity (molecular friction or thickness of the solution)

It may seem obvious, but drugs penetrate the cornea better if dropped directly on the cornea. When a drug is administered to the eye and first touches the cornea, it's at its greatest concentration. After being administered, the medication dilutes when it spreads out and mixes with the tears. If the drop must work its way to the cornea (i.e., in the lower conjunctival sac), it isn't as concentrated or effective as it is if the drop makes contact with the cornea right out of the bottle.

Topical medications penetrate the eye via the cornea and enter the anterior chamber of the eye. They don't get much beyond the crystalline lens, so using a topical steroid to treat a posterior uveitis is pretty much an exercise in futility.

Also, the cornea acts as a barrier to many drops by virtue of the lipid (fat) content of the epithelium, which functions as a barrier to all medications not soluble in fat. Assuming a medication is soluble in fat and makes



it through the epithelium, it must be water soluble to penetrate the remaining layers of the cornea. Drug manufacturers must consider all this when formulating their medications.

---

## Medication Delivery Methods

Ocular medications can be administered in several different ways. Each method has advantages and disadvantages. The medication's delivery method depends on the desired outcome, type of drug administered, and the eye condition being treated.

Primary methods of ocular medication delivery are topical application; continuous release delivery; subconjunctival, sub-tenon's, retrobulbar, and intravitreal injections; and systemically. The delivery methods you'll most likely encounter in your clinics are topical application, continuous release, and systemic application. Of those, the most common method used is topical application, so let's start there.

## Topical Application

As stated earlier, topical drugs are administered directly in the eye. Topical medications are chemically designed in four major forms:

- **Solutions** – are one or more substances dissolved in a liquid medium. They work well, but have minimal contact time with the eye.
  - **Suspensions** – are drops containing finely divided drug particles suspended in a liquid medium. Since the drug is not dissolved into the fluid (the little particles settle at the bottom of the bottle), drugs in suspension must be shaken before use. If not adequately shaken, the drug is not evenly distributed and is not as effective.
  - **Ointments** – (abbreviated ung in prescription form) are drugs suspended in a petroleum base. They are a good delivery method as they prolong a drug's contact time with the cornea. On the down side, they smear the cornea with "goo" and blur vision. Because of this, patients are instructed to use ointments just before bed.
  - **Continuous release delivery** – is "sandwiched" in a membrane. The membrane is placed inside the lower conjunctival sac, where it dissolves throughout the day, releasing medication to the eye. Continuous release delivery is actually a separate system but is included here since it occurs topically.
-

Below is the procedural process for topical application. Click the blue "start" button to learn the procedure.

# **Introduction**

## **Topical application**

You have probably instilled drops into patients' eyes many times since you arrived at your clinic.

The following is a review of the steps in properly administering medications topically:

## Step 1

Wash your hands.

## Step 2

Triple check the medication you're going to instill to ensure it's what the doctor ordered.

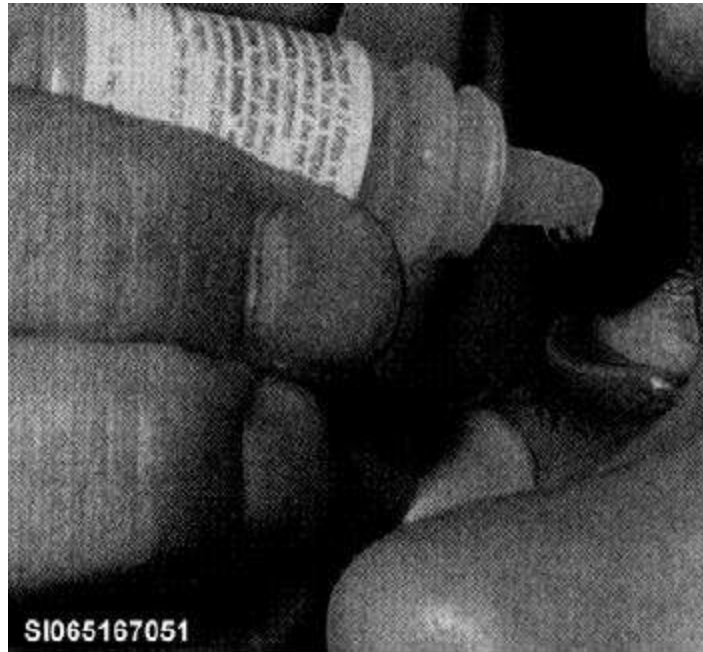### Step 3

Advise the patient of what you're going to do.

#### Step 4

Recline the patient or gently tilt the patient's head back. Always ask the patient about neck or back problems before tilting his or her head. Do not tilt a Down's syndrome patient's neck due to the high risk of cervical fracture.

### Step 5



With one hand, hold the upper eyelid, and with a finger of the other hand (the one holding the little bottle of medication), pull down gently on the lower eyelid (fig. 4-1).



## Step 6

Have the patient look down.

## Step 7

Keep the bottle about ½" above the eye. This should be high enough to avoid contamination by the patient's eyelashes in the event the patient inadvertently blinks, while still allowing good control of where the drop goes. Now, squeeze the bottle to dispense a drop in the eye.

Ideally, the drop hits just above the upper limbus, causing minimal reaction by the patient (since the very sensitive cornea isn't hit directly), but allowing a good percentage of medication to flow across the cornea before it gets diluted by tears.

## Step 8

Advise the patient not to squeeze his or her eyes tightly closed nor dab his or her eyes with tissue. Squeezing and dabbing eliminates some of the medication from the eye, minimizing the medication's effectiveness.

### Step 9



Once the drop is in the eye, plug the punctal area by gently squeezing in the nasal canthus for about 1 minute (fig. 4-2). You're squeezing in the right place if you feel a little bump under your fingertips.

## Step 10

If the medication is to be put in both eyes, quickly instill the drop into the second eye, and then, perform punctal occlusion to both eyes at the same time.

### CAUTION:

Just a reminder from the previous lesson, keep the eye dropper tip well away from the eye. This ensures that even if the patient blinks, the lashes won't touch it. If the dropper tip comes in contact with the patient's eyes, lids, or lashes, the bottle is contaminated. If the dropper becomes contaminated, once finished with the patient, throw the dropper and bottle away. Do not use it on another patient.

## Summary



The reason you must plug the puncta is to minimize systemic absorption of the medicine by the patient. Essentially, you want the eye to absorb all the medicine. You don't want the puncta to suck up the drug and pass it through the canaliculi, into the lacrimal sac, and go down the nasal lacrimal duct into the throat.

Eye medications swallowed can affect a patient's heart rate and breathing. You don't want this to happen, so perform punctal occlusion for about one minute after instillation of an eye drop.

Attempting to instill an ophthalmic drug into a child's eyes can be challenging. A good method to minimize most problems you have when placing drops in a child's eye is to lay the child back and ask the child to close both eyes. Put one drop of the ophthalmic drug in each medial canthal area. Have the child blink once or twice, and the task is done with little or no fuss. Don't forget to do the punctal occlusion to minimize systemic absorption.

Instilling an ointment is essentially the same, except the ointment is squeezed into the lower conjunctival sac until a  $\frac{1}{4}$ " strip is administered (fig. 4-3). Punctal occlusion is unnecessary, and as with drops, do not allow the medication dispenser to touch the patient or it's considered contaminated.

---



Complete the content above before moving on.

## Continuous Release Delivery

A medication device placed in the eye that lasts for a week is a big benefit to patients who have trouble keeping up with their drops. The most common medication device is the Pilocarpine Ocusert, which permits continuous delivery of medication 24 hours a day for seven days.

Pilocarpine is a glaucoma medication sandwiched in a soft, pliable, dissolvable membrane. It's inserted in the lower conjunctiva by the patient and gradually releases its medication throughout the week.

There are also ocuserts for patients with chronically dry eyes. One product, Lacrisert, provides a continuous release of hydroxypropyl cellulose, which supplies lubrication to the patient's eye over a period of time.

Another way to have a continuous release delivery is to perform a subconjunctival, sub-tenon's, or retrobulbar injection with a medication designed to stay in the injection area and release or absorb into the body over a period of three to seven days. This is very useful in cases of posterior uveitis where a steroid is needed to reduce choroidal or retinal inflammation. For the patient to gain full benefit of the medicine, it must be steadily time released.

## Systemic Administration

Systemic medications are drugs affecting the body's whole system, not just one part. When you take an aspirin, it doesn't just go to your head for your headache. It goes throughout your body so the pain-killing and anti-inflammatory effects occur everywhere blood goes, so the effects of a systemic medication are experienced throughout the body. These medications can be given orally or by injection.

In the eye clinic, you need to be aware of the inadvertent systemic absorption of medications by patients when you give eye drops. If you don't perform the punctal/canaliculi plugging of the lacrimal system for at least one minute after administering eye drops, the lacrimal system carries the medication down to the patient's throat, and the patient swallows it, which puts the medication in the patient's system, not just the

eye (where you wanted it). This can have some hazardous complications. Phenylephrine can stimulate the heart rate. Beta-blockers can slow down the heart rate and breathing.

Avoid letting topical medications get into the body systemically when administering medications in the clinic. Additionally, advise the patients of the consequences of not performing the punctal/canaliculi plugging of the lacrimal system for at least one minute after administering eye drops. Medication taken orally can have a wide variety of effects on patients as well.

However, sometimes systemic absorption of medications is what you want. For example, to reduce eye pressure to a manageable level, a patient with acute angle-closure glaucoma may be prescribed, a 500-milligram (mg) tablet of Diamox, to be taken by mouth. This oral, systemic delivery provides the effect needed quicker than a topical medication. Another example is if a patient has an eye infection because of a systemic infection, the patient is given oral antibiotics to manage the infection everywhere it's present.

There are times, when a tablet or fluid given orally may not provide the desired effect. In these cases, give the systemic medication by injection. A systemic injection occurs in one of the following ways:

- Subcutaneously (sub Q)—under the skin
- Intramuscularly (IM)—in a muscle
- Intravenously (IV)—into a vein
- Intravitreal—into the eye

Doing a fluorescein angiography (FA) is a good example of when a systemic injection is used. A liquid solution of fluorescein (5–25 percent concentration) is injected into a vein in the patient's arm, while an eye technician views the patient's retina through a fundus camera equipped with a special filter. In 5–15 seconds, the fluorescein dye reaches the arteries and veins of the eye, and the technician begins taking photographs to document the circulation of blood flow.

Another example of using a systemic injection is when there is inflammation or infection in the posterior part of the eye or orbit (e.g., cellulitis or posterior uveitis). A topical medication that cannot penetrate to the affected tissue is of no use, so the best treatment is to get the medication directly to the affected region. An oral medication might work, but then, it also has some effect on the rest of the body. So, an injected delivery method is most effective in a case like this.



# Complications and Actions of Ophthalmic Drugs

Giving people medications may seem routine, but there could be negative consequences. Not all people are tolerant of all medications. If given a drug they can't tolerate, a patient may have an allergic or toxic reaction. As an eye technician administering drugs to people on a daily basis, it's important you understand and recognize what is occurring if a patient does have a reaction. You also need to understand how drugs affect the body's autonomic nervous system (ANS), to include the sympathetic and parasympathetic divisions.

## Allergic Reaction

An allergic response is the most frequent type of drug reaction. Signs and symptoms vary from moderate swelling and redness (most common) to convulsions and death (less common). Because of the wide range of symptoms possible, recognition of a drug reaction is based on the degree and type of change the patient has as a result of the administration of a drug.

Allergic reactions usually follow repeated application of a medication, since the patient must be exposed to the agent to develop a hypersensitivity to it. Thus, a delay in time occurs between the reaction to a particular drug and the development of a hypersensitivity state. This delay, referred to as the induction period, can be days, weeks, months, or years.

What this means is a patient may not have had an allergic reaction to a medication previously, but prior exposure to the drug may have heightened the body's sensitivity to it and the patient may have a reaction on the day you administer the medication. People can also develop allergic sensitivity to things besides medication. You've probably heard of people who are allergic to latex (rubber) or develop a skin rash due to an allergic sensitivity to certain types of tape used on them.

The most common sign of an allergic reaction is redness and swelling. Some patients may complain of irritation or burning from a medication. If you notice these signs, stop instilling the drug and get a doctor for assistance. Recline the patient; keep the patient as relaxed as possible and keep blood flowing to the head to prevent him or her from passing out.

A simple allergic reaction may become quite serious, so you'll need assistance in case it gets worse than a little redness or swelling. Atropine (a cycloplegic) and Neomycin (an antibiotic) are two of the more common drugs known to cause an allergic, hypersensitive response in some patients.

## Preventing a Drug Reaction

The single most effective way to avoid an adverse drug reaction in a patient is to take a good case history. Inquire about any drug sensitivities experienced in the past. If the patient had a reaction to sulfa drugs, it's foolish to administer sulfacetamide to cure conjunctivitis. A patient with an anterior chamber intraocular lens placed in the eye may not react well to drops constricting or dilating the pupil excessively. Pupillary movement could displace the lens or cause the iris to become irritated from rubbing against the lens, possibly causing an iritis.

Find out if the patient is currently taking any other medications. If so, it's important to avoid using a drug that could cause a reaction with the other medication. If in doubt, it's always good practice to check with the doctor before administering anything.

Another wise move to avoid negative drug reactions is to look closely at the drug label. Read and re-read the drug label to ensure it's the proper drug to administer. Then, read it a third time just before administering the drug. Check the following items prior to administering a drug:

- **The actual drug name.** Mydracyl is a trade name for tropicamide, which is a cycloplegic, not a simple mydriatic.
- **The manufacturer's expiration date.** If the date stamped on the bottle or tube is JUNE 2017; do not use on 01 JULY 2017!
- **The drug percentage.** Phenylephrine is phenylephrine, right? Wrong. The 2.5 percent dosage is a whole lot safer than the 10 percent dosage. You could literally kill someone by using the wrong type. If in doubt, double check with the doctor.
- **The word ophthalmic (for use in the eyes).** Some drugs you use on the eyes are also made for use on other parts of the body. For example, the antibiotic erythromycin is used on cuts and burns. If the tube doesn't say ophthalmic on it, the medication is not used in the eyes. Only ophthalmic-quality drugs should be put in the eyes.
- **The date the medication was opened.** If someone has already removed the manufacturer's seal and opened the drug, this person should have put the date the container was opened on the label. If a drug has been opened, but there is no date on it, throw it away. If it has been over 90 days since the drug was opened, throw it away. If the manufacturer's date has passed, but the drug was only opened 20 days ago, throw it away. If the drug container looks old or the solution discolored, throw it away.

Be aware of the precautionary information contained with a drug. For example, it's not advisable to use mydriatics and cycloplegics on patients with extremely narrow anterior chamber angles. Using an anesthetic every few hours for an eye abrasion delays healing and can soften and damage the cornea more.

Be aware of the precautions for the drugs you are administering to your patients. Finally, be sure you know and understand your doctor's instructions before you administer medications, and only use the amount the doctor has requested.

## Autonomic Medications and the Body's Nervous System

To understand the autonomic drugs, you really need to understand the body's nervous system, which controls our muscles and senses. The nervous system is composed of two main parts:

- The central nervous system (CNS), which is the brain and spinal cord.
- The peripheral nervous system (PNS), which are all the nerves peripheral to the brain and spinal cord

To understand the autonomic drugs, you need to focus on the PNS, which has two divisions:

- The ANS – controls unconscious, involuntary, automatic functions of the body (e.g., protection, processing nutrition, elimination of waste, and regulatory functions [i.e., heart rate]). It takes care of the things we don't think about. These are things that “just happen” in the body to keep us alive and functioning correctly.
- The somatic nervous system – feels and controls conscious actions, unconscious reactions, and reflexes. It's made up of the sensory and motor nerves.

## Autonomic Nervous System

When you use medications in the eyes or systemically, you're trying to have an effect on the ANS, which functions on two levels:

The sympathetic nervous system – represents the system working when we are alarmed or threatened. It's the nervous system kicking in when the body is trying to decide to “fight or flight.” It causes the pupils to dilate (so more can be seen), the ciliary muscle to relax (good for distant vision), and the heart rate to increase (in case you need to act quickly).

- The parasympathetic nervous system – seeks to relax the body to conserve energy. It functions when we're in our normal routine state of living.

- The parasympathetic nervous system constricts the pupils, causes the ciliary muscle to contract (good for near vision), and keeps the heart rate at a low level.

We use certain drugs to affect a specific nervous system. Sympathomimetic drugs (e.g., epinephrine and phenylephrine) mimic the effects of the sympathetic nervous system. Parasympathomimetic drugs (e.g., pilocarpine, eserine, and Miochol®), on the other hand, mimic the certain effects of the parasympathetic nervous system.

One way for a drug to work is to stimulate the system desired. Think of two people having a tug-of-war. Using this analogy, a mimetic makes the person you want to win stronger so they can out pull the other person. Another way drugs can work is to paralyze the effects of the system you don't want working. This removes the opposition for the system you do want working so you still get the desired result. These types of drugs are called sympatholytics or parasympatholytics. Think of our tug-of-war example again.

If you use a lytic drug instead of a mimetic, you paralyze the person you want to lose, and the person you want to win doesn't need to be stimulated or made any stronger. If you want to dilate a person's eyes using a lytic drug, you paralyze the nervous system controlling pupillary constriction--the parasympathetic nervous system. So if you use a parasympatholytic, you paralyze the parasympathetic system and the sympathetic system can work without opposition to dilate the pupils, even though it isn't stimulated to do so.

Some examples of parasympatholytics used in the eye are atropine, homatropine, cyclopentolate, and tropicamide. The thing to keep in mind about these drugs is you use them topically on the eye to affect a reaction from the muscles of the eye.

If a person swallows these drugs, the drugs still mimic or paralyze the sympathetic and parasympathetic nervous system, affecting the person's breathing, heart rate, and more. This is why you need to perform proper punctal occlusion after instilling eye drops. You do not want to cause a person's heart to start racing when the goal is just to dilate the pupils!

## Autonomic Drugs

The following table shows some of the more common drugs used in the clinic. The drugs are categorized by how they manipulate the body's ANS:

Autonomic Drugs	
Sympathomimetic	Neosynephrine (phenylephrine). Epinephrine. Propine (a pro-drug of epinephrine).

Autonomic Drugs	
	Iopidine.
Sympatholytic	Timoptic. Betagan. Betoptic. Thymoxamine.
Parasympathomimetic	Miochol. Pilocarpine. Carbachol.
Parasympatholytic	Atropine. Homatropine. Cyclogyl. Mydriacyl.

In a clinical setting, the primary ophthalmic uses of medications affecting the ANS are for regulating bodily actions (e.g., pupil size, aqueous production and outflow, and accommodation). Intelligent use of these autonomic drugs allow for the proper examination of the eye and effective treatment of many eye disorders such as iritis and glaucoma.



Complete the content above before moving on.

**Self-Test Questions.** After you complete these questions pertaining to the general principles of ophthalmic pharmacology, you may check your answers at the end of this module.

1. What is a big factor in a medication's tolerability for the patient?

Type your answer here

---

SUBMIT

2. What term applies to drugs that stay within a range of  $\pm 0.2$  percent of our tears' normal NaCl level?

Type your answer here

---

SUBMIT

3. What kind of patient benefits from a hypotonic solution?

Type your answer here

---

SUBMIT

4. What are two ways to slow down the development of microorganisms in ophthalmic medications?

Type your answer here

SUBMIT

5. What type of drugs are typically used in eye surgeries to reduce irritation to open tissues?

Type your answer here

SUBMIT

6. What are ophthalmic medications sensitive to?

Type your answer here

---

SUBMIT

7. What is one indication a medication is oxidizing?

Type your answer here

---

SUBMIT

8. Name the four ways to increase the penetration of an eye drop.

Type your answer here

---

SUBMIT



9. The cornea acts as a barrier to which type of medications?

Type your answer here

---

SUBMIT

10. What are the main types of medication delivery?

Type your answer here

---

SUBMIT

11. In what forms are topical medications available?

Type your answer here

---

SUBMIT

12. Once a solution or drop is instilled in the eye, how do you minimize systemic absorption by the patient?

Type your answer here

---

SUBMIT

13. How long does the Pilocarpine Ocusert deliver its medication?

Type your answer here

---

SUBMIT

14. In what two ways can a systemic medication be given?

Type your answer here

---

SUBMIT

15. What does sub Q mean relative to injections? IM? IV?

Type your answer here

---

SUBMIT



Complete the knowledge check questions before moving forward.

**Self-Test Questions.** After you complete these questions pertaining to ocular adnexa, you may check your answers at the end of this module.

1. What is the most frequent type of drug reaction? What is the range of signs and symptoms of this reaction?

Type your answer here

---

SUBMIT

2. Can you assume that if a patient was given a drug before without a reaction the individual will not have a reaction if given that drug again?

---

☐

Yes

☐

No

SUBMIT

3. What should you do if you put Atropine in a patient's eye and notice some redness and swelling occurring?

Type your answer here

---

SUBMIT

4. What can toxic chemical reactions cause?

Type your answer here

---

SUBMIT

5. What is the single most effective way to avoid an adverse drug reaction in your patient?

Type your answer here

---

SUBMIT

6. What things should you check before instilling a medication into a patient's eyes?

Type your answer here

SUBMIT



Complete the knowledge check questions before moving forward.

**Self-Test Questions.** After you complete these questions pertaining to ocular adnexa, you may check your answers at the end of this module

1. What makes up the CNS?

Type your answer here

SUBMIT

2. What are the two divisions of the PNS?

Type your answer here

SUBMIT

3. What two levels or divisions make up the ANS?

Type your answer here

SUBMIT

4. Explain the difference between a mimetic and a lytic.

Type your answer here

SUBMIT



Complete the knowledge check questions before moving forward in the lesson..

A close-up photograph of a human eye. A thin white horizontal line is positioned above the eye. The text 'Ophthalmic Medications' is overlaid in yellow.

# Ophthalmic Medications

## Ophthalmic Medications

There are many medications available for use in the eye. There are drugs to dilate the eyes, paralyze the focusing mechanism of the eyes, decrease the intraocular pressure (IOP of the eye, kill pain, reduce allergic



reactions, fight off infections, and reduce inflammation. There are also stains used to find out what is wrong with the eye and allow tests to be performed.

All these medications are important to the eye care professional who needs to diagnose and treat patients correctly. Some of the more technical aspects as to how and why these drugs accomplish what they do may not be as essential to you as they are to the doctor. Still, you need to be informed about what the drugs do and when they shouldn't be used.

You act as a backup for your doctor when you see him or her prescribe something that doesn't seem right. If a diabetic person came in with acute glaucoma, the doctor may tell you to give the patient Osmoglyn to lower the pressure. You should hold off doing this for just a moment while you discreetly remind the doctor the patient is diabetic. You are not necessarily questioning the doctor's judgment, but, during a busy day with many medical and administrative things going through the doctor's mind, he or she may very well have missed seeing the word diabetic in the record.

You're definitely involved in administering ophthalmic medications and answering questions about them. With that in mind, you need to have a thorough understanding of the medication you're administering and their associated precautions. Your knowledge can keep you and your doctor out of trouble and help your patient's well-being.

## **Mydriatic and Cycloplegic Medications**

Mydriatics and cycloplegics are used every day in an eye clinic. They facilitate examination of the eyes and are prescribed to treat some eye disorders (e.g., iritis). In this lesson, the drugs covered have the medication generic name with their common trade names in parentheses. This should help you relate what you are reading to medications you may already be using.

### **Mydriatics**

Mydriasis is the dilation of the pupils, so, logically, a mydriatic drug is used to dilate pupils. The main reason the eyes are dilated is to allow the doctor to perform a thorough exam of the posterior portion of a patient's eyes. A big pupil allows a wider field of view and gives the examiner a chance to see the vast majority of the retina, rather than the very small amount seen in an undilated eye. Mydriasis is also useful in allowing you to take fundus photographs of the macula, optic nerve, and any retinal anomalies present.

The most common plain or simple mydriatic is phenylephrine, but there are others, such as epinephrine and cocaine.

Avoid using mydriatics in patients with extremely narrow anterior chamber angles, since dilation can cause angle-closure glaucoma. Always check your patient's angles before using any mydriatic drug on a patient who has not been checked out previously and approved for dilation.

---

**Listed below are some common medications used for mydriasis. Click on each (+) sign to learn the dosage amounts, preparations, action, contraindications, and storage.**

---

### **Phenylephrine hydrochloride (Neo-Synephrine; AK-Dilate)** —

This mydriatic is used daily in an eye clinic. You have probably seen and used it many times. In addition to dilating the pupils, it's also a vaso-constrictor, so a patient with bloodshot eyes suddenly looks fine after the drop is administered. Phenylephrine is most often used in conjunction with the cycloplegic Mydracyl (which is covered later). You should know the following specific information about phenylephrine:

- **Dosage:** Instill one or two drops in each eye.
- **Preparation: Solution,** 2.5–10 percent. (2.5 percent is the most common percentage used).
- **Actions and uses:** Mydriasis without cycloplegia. It dilates the pupil within 30 minutes of instillation and lasts 20 minutes to three hours. Phenylephrine is the mydriatic drug of choice. It's a sympathomimetic drug.
- **Contraindications:** It can cause acute angle-closure glaucoma if used in patients with narrow anterior chamber angles. If systemically absorbed, it can cause increased blood pressure, headache, and even

death. This is why most doctors usually avoid the 10 percent version and prefer the 2.5 percent drops. The 2.5 percent version has fewer side effects and complications, but provides virtually the same mydriatic effect.

- **Storage:** Phenylephrine Hydrochloride Ophthalmic Solution, 2.5 percent, per the product package insert, requires refrigeration between 2 degrees (°) centigrade (c) and 8°C (36° Fahrenheit [F] – 46°F). Regarding short-term stability data, the data supports that an unopened bottle stored at room temperature remains stable up to 39 days. The stability assessment supports that once the bottle is opened, the product may be kept at room temperature for up to 14 days, as long as the bottle is re-sealed by firmly re-applying the cap after each use. The product must be discarded after 14 days if left at room temperature, per the Bausch & Lomb's Pharmacovigilance Specialist.

## Epinephrine (Eppy-N) —

Though not used much anymore, this drug is more popular in the ER and surgery. While it's a mydriatic, its primary use is in the treatment of glaucoma (for which it is not used much anymore either). The information you should know about epinephrine is:

- **Preparation:** Solution, 0.25–2 percent.
- **Dosage:** Instill one drop in each eye for dilation purposes. To treat glaucoma, most doctors normally start patients off with one drop, four times a day.
- **Action and uses:** Treats glaucoma (reduces IOP) by decreasing aqueous production. Also dilates pupils, increases blood pressure, affects cardiac rhythm, relieves bronchial spasm, and decreases swelling. Epinephrine yields a brief mydriasis upon instillation with some vasoconstriction (shrinking of the blood vessels), making the sclera of the eye look white and clear. Epinephrine is a sympathomimetic.
- **Contraindications:** Do not use on patients with heart or vascular problems. The medication raises blood pressure and can cause arrhythmias (abnormal heart rhythms). Chronic use can lead to a rebound effect of vasodilation, making the eye(s) look red and irritated (hyperemia).

## Cocaine —

Cocaine is primarily a strong anesthetic (numbing) agent, but it also causes a mild mydriatic effect. It's most often used to establish the diagnosis of Horner's syndrome, which is caused by damage to the sympathetic nerves of the head. In Horner's syndrome, the patient has one pupil smaller than the other, especially in dim

light. The three classic signs of Horner's syndrome are ptosis, miosis, and anhidrosis—dry skin—on one side of the face.

A drop of ophthalmic quality cocaine (5–10 percent) is put in the suspected eye, followed by another drop in one minute. If the pupil fails to dilate or dilates very poorly, the diagnosis of Horner's syndrome can be made. The cocaine test confirms or denies the presence of Horner's syndrome. Without it, the diagnosis cannot be confirmed. Any diagnosis of Horner's syndrome made without the use of cocaine is based on clinical criteria alone and is presumptive. If the cocaine does dilate the smaller pupil, its smallness is probably just a congenital asymmetry of pupil size called physiological anisocoria.

## Cycloplegics —

These drugs cause mydriasis like mydriatics, but they also cause cycloplegia, which is paralysis of the ciliary muscle. Remember, the ciliary muscle controls focusing of the light rays entering the eye by changing the shape of the crystalline lens.

Cycloplegics are used to dilate the pupils to facilitate examination of the fundus. In iritis patients, they prevent ciliary spasm and pain. Additionally, they are used to prevent a patient (usually a suspected hyperope) from constantly accommodating during a refraction.

Cycloplegics are also used to perform entrance eye exams on flyers to find out what their true refractive error is. Again, this is accomplished by paralyzing the focusing mechanism of the eyes (temporarily) while the doctor refracts the patient. Cycloplegics almost always come in bottles with red caps.



Complete the content above before moving on.

**Listed below are some common  
medications used for cycloplegics. Flip  
each flash card to learn the dosage**

## amounts, preparations, action, contraindications, and storage.

---

Tropicamide (Mydracyl;  
Opticyl)

You need to know the following information about tropicamide:

- Dosage: Instill one drop in each eye. Repeat upon the doctor's order.
- Preparation: Solution, 0.5–2 percent (most common usage is 1 percent).

• Contraindications: Avoid

Cyclopentolate (Cyclogyl)

You need to know the following information about cyclopentolate:

- Preparation: Solution, 0.5–2 percent (1 percent is most often used).
- Dosage: Instill one or two drops in each eye. For flying class I and IA

Homatropine (Isopto-homatropine)

You need to know the following information about homatropine:

- Dosage: Instill one or two drops in each eye.
- Preparation: Solution, 1–5 percent (most common usage is the 1 or 2 percent solutions).

Atropine sulfate (Isopto-atropine)

You need to know the following information about atropine sulfate:

- Preparation: Solution, 0.5–2 percent. Ointment, 0.5 and 1 percent.
- Dosage: For refraction in children, instill one or two drops of 0.5–1 percent



Click on all of the flashcards above before moving forward in the lesson.

## Mydriatic and cycloplegic combo

With a combination of a mydriatic and a cycloplegic (Paremyd®), you have one less drop to administer.

Combination of Tropicamide 0.25 percent and Hydroxyamphetamine Hydrobromide 1 percent

(Paremyd®). You need to know the following information about Paremyd®:

- **Preparation:** Solution, 0.25.
- **Dosage:** One to two drops 15 minutes prior to fundus exam.
- **Action and uses:** Onset of action is within 15 minutes. The maximum effect is reached in about 60 minutes. Produces mydriasis and partial paralysis of accommodation. Recovery begins within 90 minutes, with complete recovery typically in six to eight hours.
- **Contraindications:** Should not be used in patients with angle-closure glaucoma or in those with narrow angles in whom dilation of the pupil may precipitate an attack of angle-closure glaucoma. This product is also contraindicated in patients who are hypersensitive to any of its components.

Overall, be patient and understanding of your patients when they are having their eyes dilated. Many experience heightened photosensitivity and lack of accommodation.

Most patients find having their eyes dilated very inconvenient. The heightened photosensitivity and lack of accommodation bother them. Some may need a note for school or work to notify others of their light sensitivity and difficulty with near work. Please keep this in mind and treat them with patience and understanding.



Complete the content above before moving on to the self-test questions.

**Self-Test Questions. After you complete these questions pertaining to the mydriatic and cycloplegic medications, you may check your answers at the end of this module.**

1. Why do you use a mydriatic drug?

Type your answer here

SUBMIT

2. What percentage of phenylephrine hydrochloride (Neo-Synephrine) solution is the preferred concentration for use? Why?

Type your answer here

SUBMIT

3. What mydriatic drug is used to confirm the presence of a Horner's syndrome?

Type your answer here

SUBMIT

4. Name the three classic signs of a Horner's syndrome.



Type your answer here

---

SUBMIT

5. List the four cycloplegics and explain for what purpose each is primarily used.

Type your answer here

---

SUBMIT

6. What bothers most patients about being dilated?

Type your answer here

---

SUBMIT



Complete the knowledge questions above before moving forward in the lesson.

## Anti-glaucoma/Intraocular Pressure (IOP) Lowering Medications

There are many drugs used to treat high IOP. Notice we didn't just say glaucoma because glaucoma has many causes or risk factors, with high IOP being just one of the most easily identified, and thus far, treatable causes. Remember, a person with a high IOP is not automatically diagnosed with glaucoma. Other physical signs (e.g., optic nerve head changes) need to be present. Most significantly, a VF test needs to be conducted prior to a glaucoma diagnosis.

The main focus of glaucoma treatment is IOP reduction, since it's easy to identify and treat. As you'll read below, the goal of the various medications used for glaucoma is to lower IOP. Lowering IOP reduces damage to the nerve fiber layer of the retina and the blood supply supporting it.

Slowing or stopping the progressive VF loss glaucoma patients experience is the ultimate goal of a glaucoma/IOP lowering regimen. The various IOP lowering drugs are usually categorized based on their action on the ANS. The primary categories you'll likely hear of are beta-blockers, cholinergic agents (miotics), carbonic anhydrase inhibitors, osmotics, and prostaglandins.

### Beta-blockers

Beta-blockers are used to lower IOP. Timoptic, Betoptic, and Betagan are some of the most popular drugs used today. Introduced in the late 1970s, they quickly became the initial drugs of choice for lowering IOP.

One reason beta-blockers are so popular is, on average, they reduce IOP by 25 percent. Another reason is the dose rate is only once or twice daily, instead of up to four times a day with other medication. Finally, most of the previous drugs used to lower IOP caused miosis (pupillary constriction), dim vision (due to constricted pupil size), eyebrow ache, and stimulation of accommodation (which can blur vision).

Fortunately, beta-blockers work without these side effects. However, this does not mean they are perfect, as they also have some side effects.

Beta-blockers block the beta-1 and beta-2 receptors from doing their jobs in the body. This is good because one of the jobs of the receptors involves maintaining normal production of aqueous humor. By slowing down aqueous production, the IOP is lowered. The downside is that beta-1 and beta-2 receptors also affect heart rate and breathing.

If a patient systemically absorbs a beta-blocking medication, it slows the heart rate and makes breathing difficult. Not something you want to occur when you consider the age and general health of many of your glaucoma patients.

Thus, patients with certain systemic diseases warrant special consideration by a doctor trying to decide whether the person should use beta-blockers or not. The following is a very general list of systemic conditions contraindicating beta-blocking medication usage.

- Asthma
- Heart or circulatory problems
- Chronic obstructive pulmonary disease (COPD)

Additionally, patients already on systemic beta-blockers (e.g., Inderal® for high blood pressure) should be considered high-risk candidates for use of any of the beta-blocker medications. Patients may be better off using one of the cholinergic medications, carbonic anhydrase inhibitors, or prostaglandin inhibitors instead. Some of the common side effects of beta-blockers (especially the more medication the patient systemically absorbs) are:

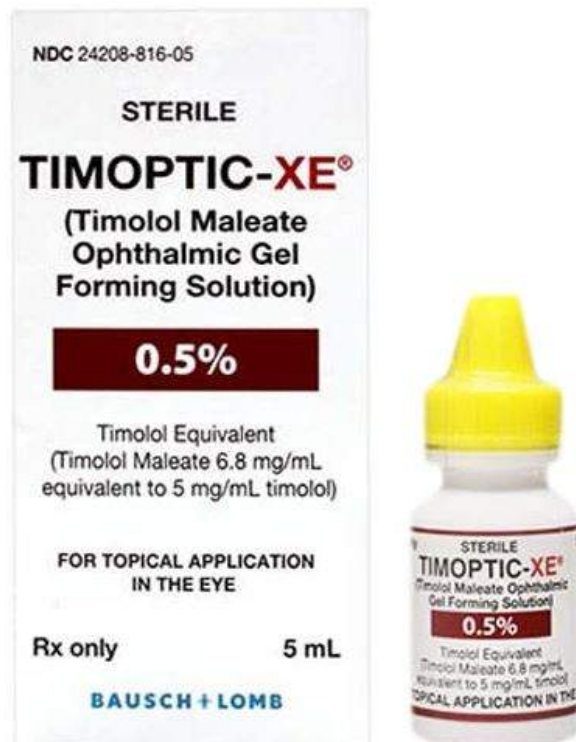- Mood changes
- Induced asthma
- Bradycardia—the slowing down of the heart rhythm (leading to low blood pressure and dizziness)

**Listed below are some commonly prescribed beta-blocker medications to lower IOP. Click on each tab to learn the dosage amounts, preparations, action, contraindications, and storage.**

**TIMOLOL MALEATE (TIMOPTIC)****BETAXOLOL HCL (BETOPTIC)****LEVOBUNOLOL HCL (BETAGAN)**

Timoptic, the first beta-blocker marketed for the treatment of glaucoma, is also the most well-known and prescribed. It's most frequently seen with a yellow label (the 0.5 percent dosage) and a yellow cap. You need to know the following information about Timoptic®:

- **Preparation:** Solution, 0.25 percent (blue label and cap) and 0.5 percent (yellow label and cap). The 0.5 percent is the most popular dosage. This drug now comes in a gel form (Gelrite), allowing for once-a-day usage and minimizing systemic absorption. Timoptic XE® is the most frequently prescribed for once-a-day dosing.
- **Dosage:** Instill one drop in each eye twice daily (24 hours). Most doctors will start a patient at a 0.5 percent dosage, while others may try a lower dosage (0.25 percent) first, to see if it works. The lower the dosage, the less severe the side effects are.
- **Action and uses:** Timoptic® slows the production of aqueous humor by blocking the beta-1 (cardiac function) and beta-2 (pulmonary function) receptors.
- **Contraindications:** Timoptic should not be prescribed for patients taking other beta-adrenergic (blocking) medications for hypertension, such as Inderal, Lopressor, or Tenormin. Additionally, patients with breathing problems (e.g., asthma and emphysema) should not be given Timoptic.



#### TIMOLOL MALEATE (TIMOPTIC)

#### BETAXOLOL HCL (BETOPTIC)

#### LEVOBUNOLOL HCL (BETAGAN)

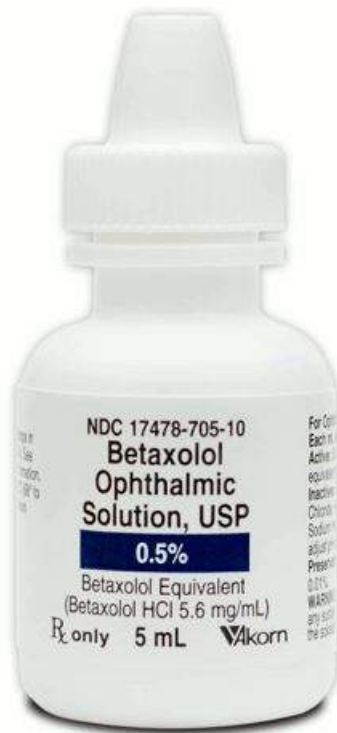Betoptic is the only beta-adrenergic blocking drug selectively blocking the beta-1 (cardiac) receptors without affecting the beta-2 (pulmonary) receptors functions. For this reason, it makes a better treatment choice for asthmatic patients. Strangely, it does not lower the IOP in patients as well as Timoptic or Betagan, yet it demonstrates an enhanced ability to prevent VF loss in patients. The reason for this phenomenon is Betoptic doesn't restrict blood flow to the micro-vasculature structures supplying the optic nerve head tissues as much as the other two beta-blocking, IOP-lowering drugs.

Whatever the reason for its unique abilities, preventing VF loss is the primary goal in glaucoma treatment. If a drug accomplishes this task, it's a valuable tool for the eye care professional and patient.

A small downside to Betoptic is it stings upon instillation and 10–20 percent of patients can't tolerate the burning. For this reason, the manufacturer of Betoptic came out with Betoptic-S, which burns less and has a slightly different formulation making it more like a time-released medication.

You need to know the following information about Betoptic®:

- **Preparation:** Solution 0.5 percent as Betoptic® and 0.25 percent as Betoptic-S®, which maintains the same effectiveness as its higher concentration sibling due to its suspension formulation.
- **Dosage:** One drop every 12 hours (twice a day).
- **Action and uses:** Blocks the beta-1 receptors, slowing the production of aqueous, and thereby, reducing IOP.
- **Contraindications:** Not recommended for patients already taking beta-blocking medications for systemic health problems. Patients with cardiac problems are higher-risk candidates for this drug. Since Betoptic doesn't block beta-2 receptors, use of this medication on patients with pulmonary (breathing) problems is not as contraindicated as the other two beta-blockers.



TIMOLOL MALEATE (TIMOPTIC)

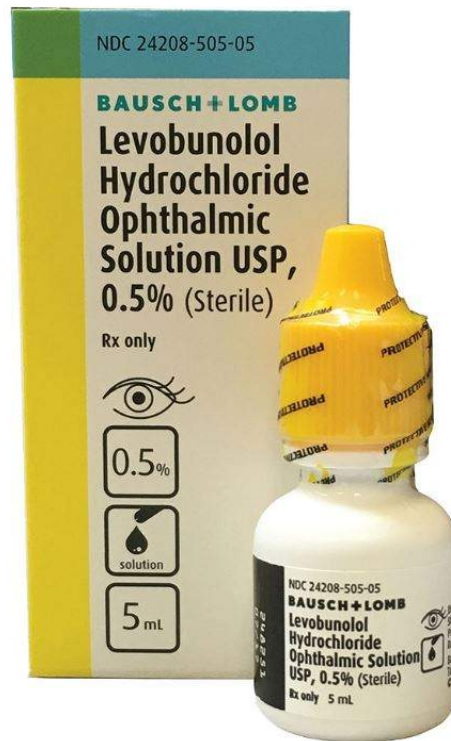BETAXOLOL HCL (BETOPTIC)

LEVOBUNOLOL HCL (BETAGAN)

Levobunolol is virtually identical to Timoptic, except it has a longer half-life than Timoptic or Betoptic, and has, therefore, been approved by the Food and Drug Administration (FDA) for once-a-day use (in the 0.5 percent dosage), instead of needing to be used twice a day. This makes it easier for the patient to comply with taking the medication as prescribed and lowers the treatment cost, since only one drop a day is used.

You need to know the following information about levobunolol:

- **Preparation:** Solution; 0.5 percent dosage (approved for once-a-day use) and the 0.25 percent dosage (for twice-a-day use).
- **Dosage:** One drop of the 0.5 percent dosage per day or two drops of the 0.25 percent dosage per day.
- **Action and uses:** Blocks beta-1 and beta-2 receptors, slowing production of aqueous humor and, thus, lowering IOP.
- **Contraindications:** Same as Timoptic.



Click on each tab before moving forward in the lesson..

## Cholinergic Agents (Direct-acting Miotics)

These drugs are the traditional medications used to lower IOP. They have fallen out of the widespread usage once enjoyed before the beta-blockers and prostaglandins came along. However, they still play a role in the management of IOP as, there are times beta-blockers alone do not lower IOP enough, or patients require specific treatment to work on the outflow of aqueous humor rather than just slowing its production.

These cholinergic drugs lower IOP by causing the longitudinal muscle of the ciliary body to pull on the sclera near the base of the iris and the trabecular meshwork. Pulling in the ciliary body causes an opening or rearranging of the trabecular meshwork, allowing the aqueous to drain from the eye faster.

Since these drugs work directly to cause contraction of the ciliary muscle, they are considered to be direct-acting miotics and are primarily used in the treatment of angle-closure glaucoma.

While the primary action desired from these miotic medications is to increase aqueous humor outflow, some secondary effects they all have are listed below:

- **Miosis**—this is a constriction of the pupil. Simple to remember: miotics cause miosis. The secondary effect miosis has on a person is a dimming of his or her vision since the amount of light entering the eye is limited when the pupil is so small. Night blindness is an understandable patient complaint.
- **Stimulation of accommodation**—this can blur a patient's distant vision, as it causes a myopic shift in people, effectively making them nearsighted.
- **Brow ache**—the stimulation of the muscles and nerves around the eyes can cause muscle spasms since the muscles are constantly working.

It should be pointed out that miotics should not be used on patients with anterior uveitis (e.g., iritis). They just make a bad situation worse. Remember, you want to dilate iritis patients!

## Pilocarpine (Pilocar; IsoptoCarpine)

While there are many miotic medications available, by far, the most popular is the drug called Pilocarpine. You need to know the following information about Pilocarpine:

- **Preparation:** Solutions, gels, Ocuserts. Dosages run from 0.5–10 percent. The most commonly used dosages are the 1-, 2-, and 4-percent drops.
- **Dosage:** One drop every six hours (one drop, both eyes, four times a day). In ointment form, application is much simpler. The patient instills a ¼"-long strip of the ointment into the lower conjunctival sac of each eyelid just before bedtime. Another benefit to the ointment is the unpleasant side effects occur during sleep, so the patient does not experience too many problems. The Ocusert method of delivery consists of putting the little gel-like disc in the lower conjunctival sac once every seven days. The unit then dissolves slowly over the week, dispensing the medication evenly over time.
- **Action and uses:** Often used in conjunction with a beta-blocker to help in lowering IOP. Pilocarpine helps aqueous outflow from the eye. Aside from the secondary effects of miosis, stimulation of accommodation, and brow ache, Pilocarpine also tends to stimulate the lacrimal gland and causes increased tearing in some patients.
- **Contraindications:** Because of the accommodative stimulation, this drug is not a good choice for patients under 40 years of age. Patients 40 years old and older, having entered their presbyopic years, are much less affected by the myopic shift in refractive error produced by Pilocarpine. Since



bradycardia (slow heart rate) can occur with this drug, patients with heart problems should be carefully managed. Finally, any miotic drug can cause significant vision problems for cataract patients, especially those with the PSC type. The patient may be able to look around an opacification of the crystalline lens when the pupils are normal size, but constricted pupils (miosis) force the patient to look through one specific portion of the lens. If this portion is opacified, the patient is going to be miserable because it's their only view of the world, and it's cloudy.

## Carbachol

You need to know the following information about Carbachol:

- **Preparation:** Solution.
- **Dosage:** 0.75–3 percent. Patients usually use one drop in each eye three times a day.
- **Action and uses:** Used intraocularly right after cataract surgery to constrict the pupil once the old lens has been removed and an artificial one put in its place. Also used in topical drop form to lower IOP like Pilocarpine.
- **Contraindications:** Same as Pilocarpine, with the additional caution to avoid its usage on patients with corneal abrasions to avoid over penetration of the medication into the eye.

## Cholinesterase inhibitors (indirect acting miotics)

These drugs also cause miosis (constriction of the pupils), but their actions are different than cholinergic drugs. They work indirectly by paralyzing the dilator muscles of the iris. With no opposition, the sphincter muscle of the iris can constrict, causing miosis.

In addition to affecting the iris, cholinesterase inhibitors also cause the eye to accommodate, just like the cholinergic agents (Pilocarpine and Carbachol), thus producing the same result as with the cholinergic agents. The main difference between these classes of drugs is in the way they work, not what they do. In general, cholinesterase inhibitors seem to be a bit stronger in action than the cholinergic drugs.

Chronic use or high doses of cholinesterase inhibitors can lead to the formation of iris cysts that can get big enough to interfere with vision. This is a bigger problem in children. The cysts usually shrink upon discontinuing the medication, lowering the dosage, or decreasing their frequency of use.

## Physostigmine salicylate (Eserine) —

You need to know the following information about physostigmine salicylate:

- Preparation: Solution and ointment. The solution is the most used form.
- Dosage: 0.25–1 percent. Patients usually use two drops in each eye four times a day.
- Action and uses: Used to lower IOP in patients with COAG. This drug's miotic effect can be reversed if needed (e.g., for a more accurate VF test or to take a fundus photograph).
- Contraindications: Same cautions as the use of Pilocarpine. It should be noted Eserine can cause conjunctivitis, allergic reactions, and spasms of the wink reflex.

## Isoflurophate —

You need to know the following information about isoflurophate:

- Preparation: Ointment.
- Dosage: 0.01–0.1 percent. Patients usually use a ¼" strip of the ointment in each eye's lower conjunctival sac just before bed.
- Action and uses: While having an IOP-lowering effect, this drug's primary use is in treating children with accommodative (convergent) esotropia. The myopic shift in vision caused by the medication allows children to accommodate (focus) less, which reduces the convergence of their eyes. Remember, three things happen during the focusing of the eyes: miosis, accommodation, and convergence. Lessen the amount a patient must accommodate and you lessen the amount the eyes converge. This drug's miotic effects last one to four weeks after the patient quits using it. Also, this drug's miotic effect cannot be reversed, so if a patient is taking this medication, and he or she needs to be dilated, the patient must stop taking the medication and wait for its effects to wear off before he or she can return to the eye clinic for a dilated exam.
- Contraindications: Same as Pilocarpine and Eserine, with the addition that it should not be used on pregnant patients.

## Echothiophate iodide (Phospholine Iodide) —

You need to know the following information about echothiophate iodide:

- **Preparation:** Solution.
- **Dosage:** 0.03–0.125 percent. Patients may take it once a day or twice a day, depending on dosage and the reason for its use.
- **Action and uses:** Used in congenital glaucoma patients and other sub-acute, but rather stubborn, cases of elevated IOP. This drug is like Isoflurophate in it's used to treat children with accommodative (convergent) esotropia, and its miotic effects cannot be reversed.
- **Contraindications:** Same as Pilocarpine, with the addition it should not be used in patients experiencing acute angle-closure glaucoma.



Complete the content above before moving on.

## Carbonic Anhydrase Inhibitors

This class of drugs enzymatically inhibits the ciliary processes' ability to produce aqueous humor. Carbonic anhydrase inhibitors are sulfonamide-based. They do not stop the production of aqueous entirely; they just reduce the amount produced. The medications listed are taken orally or topically, usually as a supplement to one of the other IOP-lowering drugs.

### Dorzolamide hydrochloride-timolol maleate (COSOPT®)

COSOPT® is the combination of a topical carbonic anhydrase inhibitor and a topical beta-adrenergic receptor blocking agent. You need to know the following information about COSOPT®:

- **Preparation:** Solution.
- **Dosage:** The dose is one drop of COSOPT® in the affected eye two times daily. If more than one topical ophthalmic drug is being used, the drugs should be administered at least 10 minutes apart because you don't want the second drop washing out or diluting the first drop.
- **Action and uses:** COSOPT® is indicated for the reduction of elevated IOP in patients with open-angle glaucoma or ocular hypertension (HTN) who are insufficiently responsive to beta-blockers (failed to achieve target IOP determined after multiple measurements over time).

- **Contraindications:** COSOPT® is contraindicated in patients with bronchial asthma, a history of bronchial asthma, severe COPD, sinus bradycardia, second or third degree atrioventricular block, overt cardiac failure, cardiogenic shock, or hypersensitivity to any component of this product.

---

## Dorzolamide hydrochloride-timolol maleate (Trusopt®) —

Trusopt® is indicated as an adjunctive (in combination with another medication) therapy to beta- blockers, or as monotherapy (by itself) in patients unresponsive to beta-blockers or in whom beta- blockers are contraindicated. You need to know the following information about Trusopt®:

- **Preparation:** 2 percent solution.
- **Dosage:** When used as adjunctive therapy with an ophthalmic beta-blocker, the dose is one drop of Trusopt® in the conjunctival sac of the affected eye, two times daily. When used as monotherapy, the dose is one drop of Trusopt® in the conjunctival sac of the affected eye, three times daily. If more than one topical ophthalmic drug is being used, the drugs should be administered at least 10 minutes apart.
- **Action and uses:** Used in the treatment of elevated IOP in ocular HTN, open-angle glaucoma, and pseudo-exfoliative glaucoma.
- **Contraindications:** Patients who are hypersensitive to any component of this product.

---

## Brinzolamide (Azopt®) —

Azopt® is a carbonic anhydrase inhibitor used to treat increased IOP caused by open-angle glaucoma. It's also used in the treatment of ocular HTN of the eye. Azopt® has a pH of 7.5 and may be used as a first line medication or a substitute for Trusopt® when patients complain of stinging and burning. You need to know the following information about Azopt®:

- **Preparation:** 1 percent suspension solution.
- **Dosage:** One drop in the effected eye three times a day for adults. Close eyes after administering and hold finger pressure in corner of each eye. The doctor determines dosages for children. Wait 10 minutes between other medications.
- **Action and users:** Used in the treatment of open-angle glaucoma and ocular HTN.
- **Contraindications:** Do not use if patient is allergic to sulfa base medicines, or has kidney or liver disease.

## Acetazolamide (Diamox®) —

Diamox® is often used when patients report to the eye clinic with acute angle-closure glaucoma. Sometimes it's used as a supplementary treatment for patients on another medication for COAG. Some ophthalmologists prescribe Diamox® preoperatively for patients who are going to have invasive eye surgeries (e.g., cataract extraction, iridotomy, or iridectomy). Another interesting, albeit not ocularly related, use for Diamox® is to treat climbers who experience altitude sickness. You need to know the following information about Diamox®:

- **Preparation:** Tablets, capsules, powder (for use in mixing into an IV-injectable form).
- **Dosage:** For angle-closure glaucoma; 500 mg tablet initially followed by 250 mg tablet every four hours. For routine treatment of COAG, 250 mg tablet twice a day. For preoperative use, 250 mg tablet every four hours.
- **Action and uses:** Used to lower IOP following an acute angle-closure glaucoma attack. Works systemically since it's taken in oral or injectable form.
- **Contraindications:** Not recommended for use by patients who are sensitive to sulfa drugs. Should be avoided in patients with kidney or liver disease. It has been shown to cause a myopic shift in prescription of some patients, so patients under 40 years of age may have some blurring of distant vision. When initially started on this medication, patients may report numbness and tingling of the hands, feet, and tongue, along with some drowsiness and fatigue. These symptoms usually diminish with time.

## Methazolamide (Neptazane®) —

You need to know the following information about methazolamide:

- **Preparation:** Tablets.
- **Dosage:** 0.25–0.50 mg. Patients take whichever dosage the doctor prescribes three times a day.
- **Action and uses:** Used to lower IOP. Can be used in conjunction with miotics and osmotics.
- **Contraindications:** Should be avoided in patients undergoing steroid treatment if possible. All other contraindications listed for Diamox® apply to Neptazane® as well, although the side effects are less likely with Neptazane®.



Complete the content above before moving on.

## Hyperosmotics

Hyperosmotics perform a unique role in lowering IOP. They draw fluid out of the body's structures, including the eye. Less fluid in the eye means lower IOP. The downside is these medications are administered systemically by IV injection or having the patient drink them; so the drugs not only draw fluid from the eye, but from the other bodily organs too. The drugs are not for chronic management of glaucoma; they are used primarily to lower the IOP quickly on patients who report to the clinic with an acute angle-closure glaucoma attack. As a one-time "let's get the patient's IOP down fast" kind of treatment, these drugs work very well.

Although another use of hyperosmotics is to lower a patient's IOP prior to an invasive eye surgery, these medications are not the drug of choice for this purpose. There are better medications available for IOP reduction with fewer side effects.

## Glycerin, Oral (Osmoglyn)

Osmoglyn is a potent (50 percent) glycerin solution the patient drinks. It has a very sweet, lime-like flavor. It quickly lowers IOP (within 15 minutes).

Osmoglyn should not be used on diabetic patients because it makes them hyperglycemic. A good substitute for diabetic patients is Isosorbide (Ismotic), which virtually does the same things as Osmoglyn, but without as many side effects.

You need to know the following information about Osmoglyn®:

- **Preparation:** Solution.
- **Dosage:** Patient drinks four to six ounces of the solution.
- **Action and uses:** Used to lower IOP in patients with acute angle-closure glaucoma. Also used prior to eye surgeries to lower IOP.
- **Contraindications:** Do not use on diabetic or dehydrated patients, nor those with heart, kidney, or liver disease. Be prepared with a receptacle because it usually causes nausea, vomiting, and

headaches.

## Mannitol (Mannitol; Osmitol)

Mannitol can be used on diabetic patients, but it's not administered as easily as the other medications. The body does not absorb Mannitol effectively if swallowed, so this drug must be injected intravenously to work. It begins lowering IOP in 30–60 minutes.

You need to know the following information about Mannitol:

- **Preparation:** IV solution (in 5–25 percent concentrations).
- **Dosage:** Depends on what percentage (concentration) of medicine is being used and the patient's weight. Administered slowly over a three to five minute period to minimize systemic trauma.
- **Action and uses:** Used to lower IOP in acute angle-closure glaucoma. A non-ocular-related medication used to decrease intracranial pressure (ICP) and treatment of cerebral edema (swelling).
- **Contraindications:** Do not use in dehydrated patients or those with kidney or heart problems.

## Prostaglandin Inhibitor

There are a number of prostaglandins on the market and latanoprost is the most widely used. It reduces the IOP by increasing the outflow of aqueous humor.

## Latanoprost (Xalatan)

You need to know the following information about this relatively new glaucoma treatment medication:

- **Preparation:** It's supplied as a 2.5-milliliter (mL) solution in a 5mL container with a turquoise-colored cap.
- **Dosage:** The recommended dosage is one drop (1.5 microgram [ $\mu\text{g}$ ]) in the affected eye once daily in the evening. The dosage of latanoprost sterile ophthalmic solution should not exceed once daily, since current evidence indicates more frequent administration may decrease the IOP-lowering effect. In other words, too much is not a good thing. IOP levels start reducing approximately three to four hours after administration, and it reaches maximum effectiveness after 8–12 hours. Latanoprost may be used concomitantly (at the same time) with other topical ophthalmic drug products to lower IOP. If more than one topical ophthalmic drug is used, the drugs should be administered at least five minutes apart.

- **Action and uses:** Studies suggest the main mechanism of action is increased uveoscleral outflow. Use Latanoprost to reduce elevated IOP levels in patients with open-angle glaucoma or ocular HTN.
- **Contraindications:** Known hypersensitivity to latanoprost, benzalkonium chloride, or any other ingredients in this product.

## Travoprost (Travatan®)

Travoprost is also a synthetic prostaglandin used in the treatment of open-angle glaucoma and ocular HTN. It works well in conjunction with beta-blockers. Wait five minutes between instillation of other medications. You need to know the following information about Travoprost:

- **Preparation:** Supplied in a 5mL bottle in a 0.004 percent concentration.
- **Dosage:** One drop in the effected eye once a day in the evening.
- **Action and uses:** Same as for the other medications already discussed in this section.
- **Contraindications:** May cause light sensitivity and discoloration of iris and eyelid tissue. Beware of usage with kidney and liver disorders.



Complete the content above before moving on to the self-test questions.

**Self-Test Questions. After you complete these questions pertaining to the anti-glaucoma/intraocular pressure lowering medications, you may check your answers at the end of this module.**

1. How do beta-blocking drugs (e.g., Timolol Maleate [Timoptic]) work?

Type your answer here

---



SUBMIT

2. When is Betaxolol HCl (Betoptic) preferred over the other beta-blockers?

Type your answer here

SUBMIT

3. What are the advantages of Levobunolol HCl (Betagan)?

Type your answer here

SUBMIT

4. When is a cholinergic agent used?

Type your answer here

---

SUBMIT

5. What are the secondary effects of miotic medications?

Type your answer here

---

SUBMIT

6. Which patients should not be given miotics?

Type your answer here

---

SUBMIT

7. Which cholinergic agent is available in Ocusert form?

Type your answer here

---

SUBMIT

8. Why is Carbachol contraindicated in patients with corneal abrasions?

Type your answer here

---

SUBMIT

9. What can chronic use or high doses of cholinesterase inhibitors lead to?

Type your answer here

---

SUBMIT

10. Which cholinesterase inhibitor can be reversed?

Type your answer here

---

SUBMIT

11. What two things do Isoflurophate and Echothiophate Iodide have in common, besides being miotics?

Type your answer here

---

SUBMIT

12. Which category of IOP-lowering drugs is sulfonamide-based?

Type your answer here

---

SUBMIT

13. Which medication is often used on patients who report to the eye clinic with acute-angle closure glaucoma and can be used as a supplementary treatment for COAG?

Type your answer here

SUBMIT

14. What is a contraindication of Methazolamide (Neptazane) that does not apply to Acetazolamide (Diamox)?

Type your answer here

SUBMIT

15. What is the primary use of the hyperosmotics?

Type your answer here

---

SUBMIT

16. List the contraindications for Glycerin (Osmoglyn).

Type your answer here

---

SUBMIT

17. How is Mannitol administered to patients?

Type your answer here

---

SUBMIT



Complete the content above before moving on to the next part of the lesson..

## Ophthalmic Anesthetic Medications and Stains

Nobody likes pain. Even the most hardcore person can be brought to tears by an abrasion or cut to the cornea. Try doing an IOP check using the tono-pen without numbing the eye first; the patient lets you know very quickly how much pain you caused. Even worse, the prospect of having an ophthalmologist cut into an inflamed hordeolum (stye) without numbing the area first is a tearjerker for most of us. Since no one wants to experience eye pain, we have anesthetics.

Anesthetics deaden the afferent (sensory) nerves so they can't tell the brain there is pain occurring. The two main types of anesthetics used in eye clinics are topical and injectable. Since you'll be dealing almost exclusively with topical anesthetics in your clinic, we'll start with topicals.

### Topical Ophthalmic Anesthetics

Always put a topical anesthetic into a patient's eye before putting in other eye drops that may irritate the eye by themselves. Also, instill an anesthetic before performing applanation (Goldmann) tonometry where the cornea actually is touched by a small probe and when performing a Schirmer II tear test. Additionally, instill an anesthetic prior to initial RGP CL fittings.

Topical anesthetics can also be used to allow the doctor to examine a patient who experienced an eye injury or for an FB removal. Another use of a topical anesthetic is for the placement of a Morgan Lens on an eye having been chemically burned so irrigation can be performed. The anesthetic also relieves any blepharospasm caused by the chemical injury.

Anesthetics are very useful, but, there are some things you should keep in mind. Never use an anesthetic on someone with a corneal injury without getting approval from the doctor. The use of a topical anesthetic on the cornea lowers its ability to heal itself. One or two drops may not seem like that big of a problem, but let the doctor make the call.

Never give a patient a bottle of corneal anesthetic. It's not a medication patients should be allowed to self-administer. If they use it several times over the course of a day or two, they'll have bigger problems than the original source of their discomfort. The anesthetic causes a softening of the epithelial cells. Continued use causes the soft, loose cells to slough off. Now the corneal epithelium is gone (eroded) in places and the Bowman's layer is exposed; this is an invitation to infection, possibly developing into a corneal ulcer. Additionally, applying too much anesthetic can actually cause a toxic reaction in the cornea, causing cell damage. Be very cautious when using it.

After administering an anesthetic to a patient's eye, warn them not to rub the eye for the next 20 minutes. The patient cannot feel the cornea and could actually do some damage by rubbing too hard. Also, if a foreign substance gets in the eye, the patient might grind the substance into the cornea, causing quite a bit of damage.

---

Listed below are the three of the more common topical anesthetics you'll come across in your eye clinic are: proparacaine, benoxinate (with fluorescein), and tetracaine.

---

## Proparacaine (Alcaine; Ophthaine; Ophthetic)

Proparacaine is the anesthetic of choice for most eye care professionals. It has minimal sting upon instillation and very few side effects. It's a good choice for most clinical needs. You need to know the following information about Proparacaine:

- Preparation: Solution (0.5 percent).
- Dosage: One or two drops, as needed.
- Action and uses: Numbs the cornea. Takes about 20 seconds to take affect and lasts about 20 minutes or less.
- Contraindications: When used properly, very few complications. Can cause some transient corneal swelling. It's the least irritating of the topical anesthetics. Remember, never give a bottle of anesthetic drops to a patient, or allow him or her to self-medicate.
- Storage: The recommended storage conditions for Alcon's Alcaine is to store at 2°C–8°C (35°F–46°F). This medication is assured to remain stable throughout the labeled expiry period. Stability studies indicate that when proparacaine hydrochloride is stored at room temperature, the freshly manufactured product remains within specifications for only one month. Storage at temperatures



above the recommended refrigerated conditions results in the increased rate of formation of the major degradant, 3-amino-4-propoxybenzoic acid. Proparacaine is typically light yellow in color initially. Additional yellow discoloration is a sign of oxidative degradation of the active ingredient, proparacaine hydrochloride. Discard if the solution becomes a darker amber color. Per the Alcon Pharmaceutical Product Specialist, "We do not promote this product to be stored at room temperature, nor can we guarantee this product if not stored as recommended."

## **Benoxinate with Fluorescein (Fluress or Flu-oxinate)**

Benoxinate is an anesthetic very similar to Proparacaine, but, unlike Proparacaine, it's not commercially available in a form all by itself. It's only found mixed with fluorescein dye, which makes it well suited for performing Goldmann applanation tonometry.

The cornea must be anesthetized when performing an applanation tonometry, since a small plastic probe touches the eye. The corneal tear film needs to have fluorescein mixed in it so the target can be seen by the examiner when the plastic probe rests on the cornea. The target showing up when the fluorescein is on the eye allows the examiner to actually get a reading of the patient's IOP.

You can see it's very convenient and effective to have the anesthetic and dye mixed into one simple- to-use solution. This is the reason Fluress and Flu-oxinate are the medications of choice when performing applanation tonometry.

On another note, liquid forms of fluorescein provide a good culture media for the formation of pseudomonas aeruginosa, which is a nasty infectious bacterium; however, when the liquid fluorescein is mixed with the anesthetic benoxinate, the mixture takes on substantial bactericidal properties, minimizing this risk of infectious organism growth. This means Fluress and Flu-oxinate are just as safe to use as any of the other anesthetic medications. You should know the following information about Benoxinate with fluorescein:

- Preparation: Solution (0.4 percent benoxinate with 0.25 percent fluorescein sodium).
- Dosage: One drop in each eye for applanation tonometry. One drop in the affected eye when examining a corneal abrasion. Use two drops in the affected eye when examining and removing FBs.
- Action and uses: Used to anesthetize and stain the cornea, most often to perform applanation tonometry. Can be used to identify corneal abrasions and to numb the eye allowing removal of FBs. Causes anesthesia of the cornea in about 20 seconds and lasts for 20 minutes or less.
- Contraindications: None. Quite safe to use. Very few people even have the slightest allergic reaction to this medication. Stings only slightly more than Proparacaine upon administration.

- Storage: Fluorescein Sodium and Benoxinate Hydrochloride Ophthalmic Solution USP, 0.25 percent/0.4 percent, per the product package insert, requires refrigeration between 2°C–8°C (36°F–46°F). Per guidance from the Bausch & Lomb's Pharmacovigilance Specialist, it can sit for up to one month maximum at room temperature opened or unopened.

## Tetracaine (Pontocaine)

Tetracaine is equal in potency to Proparacaine. Some feel it has a deeper anesthetic action and prefer it for this reason. It does not share Proparacaine's popularity, because it has more pronounced side effects. It burns and stings more on instillation. It's also known to cause allergic reactions in some patients.

An effective anesthetic, but it seems to be slightly harsher than the other two we've already discussed. You should know the following information about Tetracaine:

- Preparation: Solution (0.5 percent) and ointment (0.5 percent as base). The solution is by far the most commonly seen application.
- Dosage: One to two drops, as needed, to affect anesthesia of the cornea. Avoid prolonged use of this drug.
- Action and uses: Used just like Proparacaine. Takes effect in about 20 seconds and lasts for 20 minutes or less.
- Contraindications: Avoid using it in patients who have reported reactions to topical anesthetics previously. Mild irritation and transient corneal edema could occur. Not the best choice in children or patients with very sensitive eyes due to the burning sensation upon instillation.

## Ophthalmic stains

Ophthalmic stains are used in a variety of ways. They can show the eye care professional problems not visible with the naked eye or even the slit lamp. Their use as a diagnostic tool is what makes them so invaluable.

---

Listed below are the most widely used stains are sodium fluorescein, rose bengal, and lissamine green—each has distinct roles.

---

## Sodium Fluorescein

Sodium fluorescein is an orange-yellow stain available in a dry strip or liquid form. In dry strip form, it's marketed as Fluor-I-strips. In liquid form, it's simply called fluorescein, and is quite susceptible to contamination by the *Pseudomonas aeruginosa* bacteria. The exception to this occurs when liquid fluorescein is mixed with the topical anesthetic, Benoxinate. This mixture is marketed as Fluress or Fluoxinate, and resists contamination quite well. In this form, it's very convenient for use in applanation (Goldmann) tonometry.

Because of lingering wariness of the contamination possibilities of liquid fluorescein, the dry, filter paper strips impregnated with fluorescein (Fluor-I-strips) are the preferred dispensing method. The following is a list of common uses for sodium fluorescein:

- Stains eye for applanation tonometry so precise IOP measurements can be made using the Goldmann applanation tonometer. This is a very common use of fluorescein in the eye clinic.
- Tool to aid the fitting of gas permeable CLs. The dye shows if the lens is too tight, too loose, or making irregular contact.
- Shows defects in the corneal epithelium. If the corneal epithelium has a defect, the fluorescein pools in the affected areas. It's great for use on patients who have had a corneal abrasion.
- Take fundus photographs of the blood circulation through the eye. Commonly called FA and done in the ophthalmology clinic to detect a wide variety of retina, choroid, and circulatory problems. The dye is actually injected intravenously and liquid fluorescein is used exclusively.
- Can detect whether or not the eye has a penetrating injury. If the eye is leaking aqueous humor, the fluorescein is dispersed from the area, showing the location of the injury (a positive Seidel). A negative Seidel means the fluorescein isn't dispersed, indicating no leakage of ocular fluid).
- Used to study lacrimal patency. Simply put, if the dye is put on the eye, it should wash out with the rest of the tears and go down the throat and nose. This is called the Jones primary dye test, or Jones I. If it doesn't, then there is something wrong with the patient's tear drainage system. Then, the dye may actually be injected through the puncta to determine if the problem is a partial blockage or complete obstruction. This is known as the Jones secondary dye test, or Jones II.

**NOTE: Do not use standard fluorescein on a person wearing soft CLs!**

With so many uses, fluorescein is used quite a bit in the clinic. Fluorescein is best seen by means of ultraviolet (UV) or cobalt blue light, which causes it to fluoresce. This type of light is available on a slit lamp or in a Burton lamp; some penlights even come with a special slip-on filter that works, too.

There is a high-molecule fluorescein that can safely be used with soft CLs because it does not penetrate the pore structure of the lenses and, consequently, doesn't ruin them. It's called Fluorexon and is marketed as Fluoresoft. It represents another step forward in the flexibility of fluorescein as a diagnostic tool.

## Rose Bengal

Another stain used in the clinic is rose bengal. It's a red dye attracted to devitalized or dead epithelial cells of the cornea and conjunctiva. It comes in liquid form and dry filter paper strips. The dry filter paper strips are impregnated with rose bengal dye and are called Rosets.

In either form, the stain is helpful in making diagnosis of keratoconjunctivitis sicca (dry eyes) and showing the corneal dendrites associated with herpes simplex keratitis. Anything causing a degradation of the epithelial cells of the eye can be seen using rose bengal. Rose bengal can sting a bit upon instillation, so it's best to anesthetize the eye prior to use.

A stain applied to the eye can serve many diagnostic purposes. The use of fluorescein and rose bengal aid immeasurably in seeing what can't be seen otherwise. They have virtually no side effects, and they don't harm patients, making them a simple, but effective, tool in detecting the extent of ocular injuries and the various abnormalities. Consequently, this helps determine appropriate treatment.

## Lissamine Green

This dye stains degenerating cells, dead cells, and mucus. Lissamine green has properties very similar to rose bengal, but does not cause irritation to the eye. Rose bengal causes significantly more pain after application in patients with certain conditions, which lasts significantly longer than the pain duration compared to lissamine green. Lissamine green stains membrane-damaged epithelial cells and the corneal stroma. Lissamine green cannot be blocked by mucin in the way mucin prevents rose bengal uptake.

## Tripan Blue Ophthalmic Solution (Visionblue®)

If you are "anti" something, it means you are against it. This also applies to medications. When a drug is anti-allergic, it fights against allergies; anti-inflammatories fight inflammation; and anti-infectives fight infection. It's this ability to counteract negative conditions that makes antidrugs very common, popular, and useful in the eye clinic.

Many of these drugs you've heard of before. Some may be new to you, and perhaps you'll see them at some point later in your career. The fact is, many of your patients are taking these various medications. So it's

extremely important to know what they are, what they do, and what problems to watch out for.



Complete the content above before moving on to the self-test questions.

**Self-Test Questions. After you complete these questions pertaining to the ophthalmic anesthetic medications and stains, you may check your answers at the end of this module.**

1. What are the two main ways anesthetics can be administered to patients?

Type your answer here

---

SUBMIT

2. Name two tests that require the use of a topical anesthetic before they can be performed.

Type your answer here

---

SUBMIT

3. In a non-penetrating eye injury case, give two reasons a topical anesthetic is needed besides merely alleviating the pain of the injury?

Type your answer here

SUBMIT

4. What is the danger of a patient using a topical anesthetic several times over the course of a day or two?

Type your answer here

SUBMIT

5. What is the reason patients are warned not to rub their eyes for 20 minutes after having a topical anesthetic instilled in their eye?

Type your answer here

---

SUBMIT

6. Name the three topical anesthetics used in the eye clinic.

Type your answer here

---

SUBMIT

7. Give two possible reasons why Proparacaine is the anesthetic of choice for most eye care professionals.

Type your answer here

---

SUBMIT

8. Because Benoxinate is not commercially available in a form all by itself and can only be found mixed with fluorescein, what does this make it well suited for?

Type your answer here

---

SUBMIT

9. What are the side effects of Tetracaine (Pontocaine)?

Type your answer here

---

SUBMIT

10. What is the longest any of the topical anesthetics may last?

---

☐

10 minutes



- ☐ 40 minutes
- ☐ 20 minutes
- ☐ 60 minutes

SUBMIT

11. What is liquid sodium fluorescein susceptible to?

Type your answer here

---

SUBMIT

12. What is the preferred dispensing method for sodium fluorescein?

Type your answer here

---

SUBMIT

13. Give the six uses for sodium fluorescein.

Type your answer here

---

SUBMIT

14. What causes fluorescein to fluoresce?

Type your answer here

---

SUBMIT

15. What color dye is Rose Bengal? What is it attracted to?

Type your answer here

---

SUBMIT

16. What problem can Rose Bengal aid in diagnosing?

Type your answer here

---

SUBMIT

17. What should be instilled before using Rose Bengal?

Type your answer here

---

SUBMIT



Complete the self-test questions above before moving forward in the lesson.

## Anti-allergic, Anti-inflammatory, and Anti-infective Ophthalmic Medications

If you are “anti” something, it means you are against it. This also applies to medications. When a drug is anti-allergic, it fights against allergies; anti-inflammatories fight inflammation; and anti-infectives fight infection. It’s this ability to counteract negative conditions that makes antidrugs very common, popular, and useful in the eye clinic. Many of these drugs you’ve heard of before.

Some may be new to you, and perhaps you’ll see them at some point later in your career. The fact is, many of your patients are taking these various medications. So it’s extremely important to know what they are, what they do, and what problems to watch out for.

### Anti-allergic Drugs

These drugs are used to combat the problems occurring when the eyes react to substances they don’t like. When an undesirable substance gets in your eyes, your body produces antibodies attaching to mast cells. When this substance is encountered again, the mast cells are ready to fight the substance off this time.

The mast cells rupture and release histamine, prostaglandins, and leukotrienes. These chemicals cause the blood vessels to dilate and leak fluid. The nearby tissue absorbs this fluid, causing it to swell. The release of histamine causes your eye to itch; consequently, you rub your eye. Histamine and swelling are the body’s way of combating foreign substances it doesn’t like.

A person experiencing an allergic reaction usually exhibits some redness, swelling, and itching. This is considered a type I allergic reaction. While this is the most typical reaction, there are those rare cases where some people actually get hives and experience respiratory problems. This severe type of allergic reaction is a medical emergency and should be treated in the ER. Since severe reactions are not the norm for eye clinics, we limit our focus to type I allergic reactions and even milder situations.

**Listed below are anti-allergic drugs. Click on each (+) sign to learn more information.**

## **Decongestants** —

These topical medications may be helpful in dealing with allergies and inflammations that are producing more redness, itching, and discharge than just simple tired or irritated eyes.

Nonprescription decongestants come in roughly three levels of strength, two of which are known as decongestants. The third will be discussed in the portion of this lesson on antihistamines. The weakest decongestants are good choices for mild allergic conjunctivitis cases. They are available over the counter (OTC) and contain one of four medications:

- Oxymetazoline—OcuClear
- Phenylephrine—Relief or Prefrin
- Tetrahydrozoline—Muriel Plus or Visine
- Naphazoline—Allerest, Degest 2, or Vasoclear

The next stronger category of decongestants is more helpful at managing redness, mucus overproduction, and itching associated with mild to moderate allergic conjunctivitis. The drugs used are combined with zinc because it has been found to help block the itching and break up mucus. This combination of decongestant and zinc is referred to as a decongestant/astringent combination, and are also available OTC.

- Phenylephrine and Zinc Sulfate—Zincfrin
- Naphazoline and Zinc Sulfate—Vasoclear-A

## **Antihistamines** —

The third, and highest strength (without a prescription), category of decongestants is classified as antihistamines. Although they once were available by prescription only, the Food and Drug Administration (FDA) has approved them for OTC sales. Their concentrations have not been changed from when they were a prescription medication, so patients should be cautioned not to overdo it with the use of these drops.

The antihistamines listed in this lesson are a vasoconstrictor/antihistamine combination. They are used when itching is dominant and mucus production is mild. The drugs work primarily on counteracting the histamine mast cells that the body is producing.

With histamines being one of the primary producers of the itching, these drugs usually work quite well; however, when the primary agent causing the itching is the prostaglandins and leukotrienes, these antihistamine drugs don't work nearly as well.

The following drugs contain an antihistamine, to act against the itching and irritation caused by the body's release of histamine, and a vasoconstrictor, to "get the red out."

- Naphazoline and Pheniramine—Naphcon-A; Opcon-A
- Naphazoline and Antazoline—Vasocon-A

Another antihistamine medication that is becoming more popular is Levocabastine. This medication is the first (and only) pure antihistamine to make it into topical ophthalmic form. It's very good at managing acute allergic conditions caused by histamine. Livostin is the trade name and comes as an ophthalmic suspension, so shake it well before using it.

## Mast Cell Stabilizers

Mast cell stabilizers are only available by prescription. They are used to prevent the release of histamine, prostaglandins, and leukotrienes from sensitized mast cells. If these chemicals are not released, an allergic reaction cannot occur (theoretically). The nice thing about these drugs is they prevent the release of all three chemicals the mast cells contain, not just the histamine.

Mast cell stabilizers contain cromolyn sodium (Crolom) or lodoxamide tromethamine (Alomide). The problem with this class of medication is they should ideally be used prior to an allergic reaction, but people don't come in to the eye clinic until after they have had an episode. The mast cells have already released their symptom-causing chemicals by this point.

These drugs are best used in controlling chronic allergic problems. If a person has a seasonal allergy to particular pollens showing up every spring, he or she should come in to be treated for the allergic problem the first time it occurs. The doctor can then put the patient on one of the mast cell stabilizers to prevent the allergic reaction from recurring during the rest of the problem pollen season.

This seasonal allergic conjunctivitis is often called vernal conjunctivitis, which is what mast cell stabilizing drugs are FDA approved to treat. Another popular use of the mast cell stabilizing drugs (Crolom; Alomide) is for patients (especially CL wearers) who have a condition called giant papillary conjunctivitis (GPC). This looks like big, red bumps inside a patient's eyelids. The inflammation is treated initially with an anti-inflammatory, and then the patient is given the mast cell stabilizers to control the problem long term.



Complete the content above before moving on.

## Anti-inflammatory Drugs

Inflammation usually shows as a swelling of tissue, often accompanied by redness, warmth, pain, and loss of function of the affected tissue or organ. Inflammation is not a desirable situation. It can be caused by many problems, but is most often seen due to traumatic injury or infection. None of this is desirable, especially when it occurs around the eye. Inflammation in or around the eye can cause changes in IOP, miosis, increased permeability of the blood vessels, neo-vascularization (new blood vessel growth), and pain. Thankfully, there is a vast array of medications available to combat inflammation.

Of course, the long-term solution to inflammation is to cure the infection or treat the injury causing the inflammation. In the meantime, anti-inflammatory drugs help treat the patient in need.

There are two basic categories of anti-inflammatories—non-steroidal anti-inflammatory drugs (NSAID) and steroids. Of the two, the NSAIDs are the preferred medications due to fewer side effects, but, when it's time to really manage some serious inflammation, the steroids are available.

## Non-steroidal Anti-inflammatory

NSAIDs, though not as potent as steroids, can be effective in decreasing ocular symptoms of allergies and inflammation. The benefit of using a NSAIDs over a steroid is that they have a significantly reduced complication rate. These drugs work to reduce inflammation by inhibiting prostaglandin synthesis (reproduction).

Prostaglandins are powerful, natural chemicals causing inflammation. If prostaglandins can be moderated and controlled, so can much of the inflammation. NSAIDs do not have any effect on the leukotrienes, which also play a part in the inflammatory process. Despite this, the NSAIDs have a positive and useful role in eye care. The following table describes the NSAIDs currently being used:

Various NSAIDs and Their Description	
NSAID	Description
Diclofenac sodium (Voltaren™)	Voltaren™ is probably the most powerful anti-inflammatory of the NSAIDs group. It's used most often by cataract surgery patients for a few days after their operation. Voltaren™ doesn't lead to IOP increases as most steroidal drugs do, but it's effective enough to do the job. It has gained popularity as doctors try to minimize their use of steroids on patients with mild inflammatory conditions.
Flurbiprofen (Ocufen™) and Suprofen (Profenal®)	These are popular medications eye surgeons often administer to patients undergoing invasive eye surgeries. They're used to prevent miosis (constriction of the pupil) during surgery. Think about a cataract surgery. The pupil must be fully dilated to get access to the crystalline lens. The doctor is sliding instruments in and out of the eye, causing irritation to the iris. Irritation causes inflammation, which leads to miosis. To prevent this, Ocufen™ or Profenal® can be used to combat the inflammatory response, keeping the pupil dilated.

Various NSAIDs and Their Description	
NSAID	Description
Ketorolac Tromethamine (Acular®)	Acular® is most commonly used to control inflammation in patients suffering from seasonal (vernal) allergic conjunctivitis. It's mild and does a good job, avoiding the need for long-term steroid use in these cases.

## Steroids

For eye diseases, steroids are used primarily to reduce swelling, redness, cellular reaction, and scarring. Steroids can be a terrific tool in treating acute inflammatory problems. The adverse ocular and systemic side effects associated with topical steroids are rarely a problem when they are used for short periods of time and at the proper dosage.

The systemic use of steroids for more severe inflammation in ocular regions not reachable by an eye drop need not cause a problem either. Patients just need to be monitored closely and they need to understand the importance of not deviating from the prescribed regimen. Keep the following factors about steroid use in mind and ensure your patients understand them:

- Never just stop using a steroid. Steroid usage should be tapered down, and then discontinued. Abruptly stopping the use of a steroid can cause a rebound effect (i.e., inflammation worse than before the treatment was started).
- It's very important patients make follow-up appointments. The steroid dosage needs to be monitored, as does the health of the eye. Simple steroid use makes people more susceptible to infections. Patients on steroids need to be monitored closely. This is important.
- Patients should call or come in if they notice any unusual pain, redness, or discharge from their eyes. These could be indications the dosage is too high or low, or an infection is starting. Patients should not ignore these signs.



Steroids are generally given topically for issues concerning the anterior of the eye and systemically for disorders of the posterior segment of the eye or for acute allergic reactions of the eyelids. Topical steroids are used in the treatment of severe allergic conjunctivitis, episcleritis, superficial punctate keratitis (SPK), iritis, cyclitis, and herpes zoster keratitis.

Zoster is emphasized because steroids work well in combating this type of virus, but should be avoided in herpes simplex keratitis—they seem to actually make herpes simplex much worse instead of better. So, don't make the generalization that steroids are okay to use on all cases of herpetic keratitis, because they're not. Zoster = okay; simplex = no way.

If an inflammatory problem is occurring deeper in the orbit, like posterior uveitis or optic neuritis, a steroid may still be used, but it must be delivered systemically. The patient may take a pill, or the doctor may choose to inject a steroid in the affected area. A pill causes greater systemic effect throughout the body—a major consideration. A sub-tenon or retrobulbar injection targets the specific area where the inflammation is actually located, limiting systemic absorption. Both are useful and the method of delivery depends on the type of problem occurring and dosage required.

## **Contraindications and Hazards of Steroid Use**

In general, steroids are not to be used in patients who have a fungal disease or an active Herpes simplex virus (HSV). Steroids can be used on minor bacterial infections, but only when they are mixed with an antibiotic. Finally, steroids, in general, have been found to cause an increase in IOP with chronic use.

Some are more likely than others to have this effect. Though a concern, most routine use of topical steroids to control inflammation does not last long enough to make this an issue. As a precaution, any steroidal use beyond two weeks should be accompanied by an increase in IOP checks to ensure a problem does not develop. The following table lists some of the possible consequences of excessive steroid use:

Consequences of Excessive Steroid Use		
Ocular effects		Systemic effects
<i>From local application</i>	<i>From prolonged systemic use</i>	
Glaucoma	Decreased resistance to infection	Water and salt retention
Proliferation of bacteria	Delayed wound healing	Mental disturbance
Overgrowth of fungi	Papilledema	Hypertension
Proliferation of viruses (especially herpes simplex)	Edema of face and eyelids	Sweating
Decreased wound healing	Cataracts	Generalized weakness
Cataracts	Glaucoma	Acne Thrombophlebitis Bleeding problems Menstrual irregularities Delayed wound healing Demineralization of bones Wasting of skeletal muscles Growth retardation in children Decreased resistance to infection

**NOTE:** *Virtually all of these side effects are quite rare when the proper dosage of topical steroid is used in a short-term manner as prescribed by the doctor.*

One hazard to keep in mind about steroids is they suppress the body's natural immune response to infective organisms and can be especially dangerous to use on anyone with even a hint of fungal infection. The danger of fungal overgrowth is very real and must be considered carefully by a doctor thinking of prescribing a steroid. Also, steroids should not be used if the corneal epithelium is compromised since the steroid delays healing. This leaves the cornea vulnerable to compromise by infectious organisms for a longer period of time.

There are a large number of different steroids and a wide array of medications available. Realistically, however, there are only three steroids--prednisolone, dexamthasone, and fluorometholone--used frequently in the eye clinic. As you can see, all these steroidal drugs end with "-one" (pronounced "own"). Just by knowing the name of the drug, it's a little easier to determine if someone is taking a steroid.

---

**Listed below are some common steroid medications. Click on each (+) sign to learn more information.**

## **Prednisolone**

Prednisolone is the current steroid of choice for most ocular inflammations. It has the greatest anti-inflammatory effectiveness of all the topical ophthalmic steroids. This does not mean it's the strongest anti-inflammatory. The concentrations available allow it to outperform the more potent drugs because they must be sold at lower percentages to minimize their side effects.

Prednisolone is good for most conditions where a steroid may safely be used. It's available in concentrations ranging from 0.125–1 percent. Prednisolone drugs at the 0.125-percent level are good where mild adnexa inflammation control is needed (e.g., early allergic conjunctivitis). They are marketed under the following names:

- Pred Mild
- Econopred
- Inflamase Mild

These mild concentrations are not used too frequently. The stronger 1-percent concentration is much more clinically useful, being used to treat such things as corneal inflammations (keratitis), episcleritis, iritis, and similar conditions. Some of the more common 1-percent versions of prednisolone are:

- Pred Forte
- Econopred Plus
- Inflamase Forte

All these medications can be found in solution or suspension form. Patients who are given the suspension variety of medication should be reminded to shake their medication well before using it so they get the proper concentration of the steroid. Solutions don't need to be shaken, but it won't hurt the medication if shaken.

## Dexamethasone —

Dexamethasone, at the same concentration, is six times stronger than prednisolone. The catch is it's sold in lower concentrations than prednisolone. It's a strong anti-inflammatory, but has a greater propensity to increase IOP with use longer than two weeks.

For this reason, it's not the first choice of most eye care providers. It's useful however, in treating blepharodermatitis (inflammation of the skin of the eyelid) and is used as a supplemental therapy in acute anterior uveitis. It's available as a solution, suspension, and ointment. It's available in concentrations of 0.05–0.1 percent. Besides being marketed as dexamethasone, it's also called:

- AK-Dex
- Maxidex
- Storz-Dexa
- Decadron Phosphate

## Fluorometholone —

This class of steroids has good to excellent anti-inflammatory properties, but its real claim to fame is its diminished propensity to cause an increase in a patient's IOP with continued use. Of all the steroids available for ophthalmic use, this class is the least likely to cause an increase in IOP. This makes it a desirable choice when treating long-term inflammations (those lasting three to four weeks or more). These long-term conditions include SPK, episcleritis, pingueculitis, and some cases of ocular allergy. It does not penetrate very well, so it's ineffective on an iritis patient.

Fluorometholone is about 8–10 times more potent than prednisolone, yet it's marketed at such reduced concentrations that, prescription prednisolone is still more effective when used at its maximum available concentration. Fluorometholone is available in concentrations of 0.1 and 0.25 percent, but the higher concentration doesn't seem to yield any significant clinical improvement over its weaker version, so it's prescribed less often. Fluorometholone is made as an ointment, suspension, or solution. You have probably seen fluorometholone marketed under one of the following brand names:

- FML
- Flarex
- Flour-Op
- FML Forte

- FML S.O.P.

As you can see, steroids have a positive role to play in treating some cases of ocular inflammation. They are not the initial drug of choice due to their potential side effects, but, when they are prescribed, they work well in reducing inflammation.



Complete the content above before moving on.

## Steroid-antibiotic Combinations

Considered primarily a steroid, these combination drugs also include an anti-infective agent. As you've already learned, steroids are used as an anti-inflammatory for such conditions as severe allergic conjunctivitis, episcleritis, SPK, iritis, and so forth. In cases where the inflammatory response is secondary to compromised eye tissue (i.e., chemical keratitis with significant epithelial compromise), treating patients with a combination of steroids for the inflammation and antibiotics to ward off or treat infection is prudent.

There are several ophthalmic drugs on the market with steroid-antibiotic components; however, two medications are prescribed more often than all the rest--dexamethasone alcohol with tobramycin (TobraDex® by Alcon) and prednisolone with sodium sulfacetamide (Maxitrol®).

TobraDex®

TobraDex® is the drug of choice for moderate to severe conditions. It provides excellent coverage against most of the common ocular pathogens.

Maxitrol®

Maxitrol® is used to treat a host of mild to moderate nonspecific inflammatory conditions. Since Maxitrol® contains sulfacetamide and is preserved with thimerosal, a good case history for drug allergies is warranted. This class of medication carries with it all the warnings and



Complete the content above before moving on.

## Anti-infective Drugs

Everything you touch has microorganisms on it. There are microorganisms on your body right now. Some are bacteria, some are fungus, and some are viruses. Just because a microorganism is a bacterium, fungus, or virus doesn't mean it's necessarily bad. We have many microorganisms that are essential to our body. Think of them as the little bird riding around on top of the hippopotamus. The bird keeps the hippo clean by eating bugs on the hippo. In return, the hippo gives the bird a safe place to live and provides it a ready food source. It's a symbiotic relationship.

There are microorganisms in this category also. They actually live on us and help us in a variety of ways. The problems occur when a bad bacteria, fungus, or virus invades our body tissues. These bad microorganisms are harmful and must be exterminated. Your body has a good immune system to do just that, but sometimes microorganisms are just too tough for our body to handle, or the body is in a weakened state and can't fight back effectively. This is where anti-infective drugs come into play. There are three basic anti-infective drugs: antibiotics (for bacteria), antifungals, and antivirals.

## Antibiotics (Antibacterial)

Antibiotics are drugs with the capacity to inhibit growth of bacteria or actually kill bacteria. Bacteriostatic antibiotics act by inhibiting bacterial growth and prevent bacteria from reproducing. When a bacteriostatic agent is used, the number of bacteria present becomes static and no more are produced. They die off naturally or the body's immune system starts wiping out any remaining bacteria. Bacteriocidal antibiotics actually kill bacteria.

Bacteria often are classified by how they show up when gram stained by medical laboratory personnel. If a bacteria culture stains blue, it's considered a gram-positive bacteria. If a bacteria culture stains red, then it's considered gram-negative. It matters whether a bacterium stains gram-positive or -negative because it helps the doctor pick an antibiotic appropriate to the type of bacteria. Certain antibiotics are more effective on gram-positive bacteria; some are better on gram-negative.

Some of the more common bacteria causing an eye infection are the same bacteria routinely present on the eyelids and conjunctiva—staphylococcus epidermidis and staphylococcus aureus. They are gram-positive bacteria and are usually not harmful to us; however, if the eye becomes compromised in some way or our normal immune system is weakened, these bacteria can cause problems.

Think about "staph lid disease." It's caused by staphylococcus bacteria getting a bit too aggressive or numerous, usually due to poor lid hygiene. When people don't clean their eyelids well, they leave too much excreted protein and dead skin around. The bacteria thrive on this extra food supply, and they can get out of control and cause trouble.

Staph is not the only bacteria infecting the eye, but they are some of the most common. Since they are gram-positive bacteria, generally the best treatment is with a gram-positive targeting antibiotic.

The following table gives some of the more common gram-positive and gram-negative bacteria you may hear about:

Common Gram-Positive and Gram-Negative Bacteria	
Gram-positive Bacteria	Gram-negative Bacteria
<i>Staphylococcus aureus</i>	<i>Hemophilus influenza</i>
<i>Staphylococcus epidermidis</i>	<i>Klebsiella pneumoniae</i>
<i>Streptococcus pneumoniae</i>	<i>Neisseria gonorrhoeae</i>
<i>Hemolytic streptococci</i>	<i>Chlamydia trachomatis</i>
	<i>Pseudomonas aeruginosa</i>

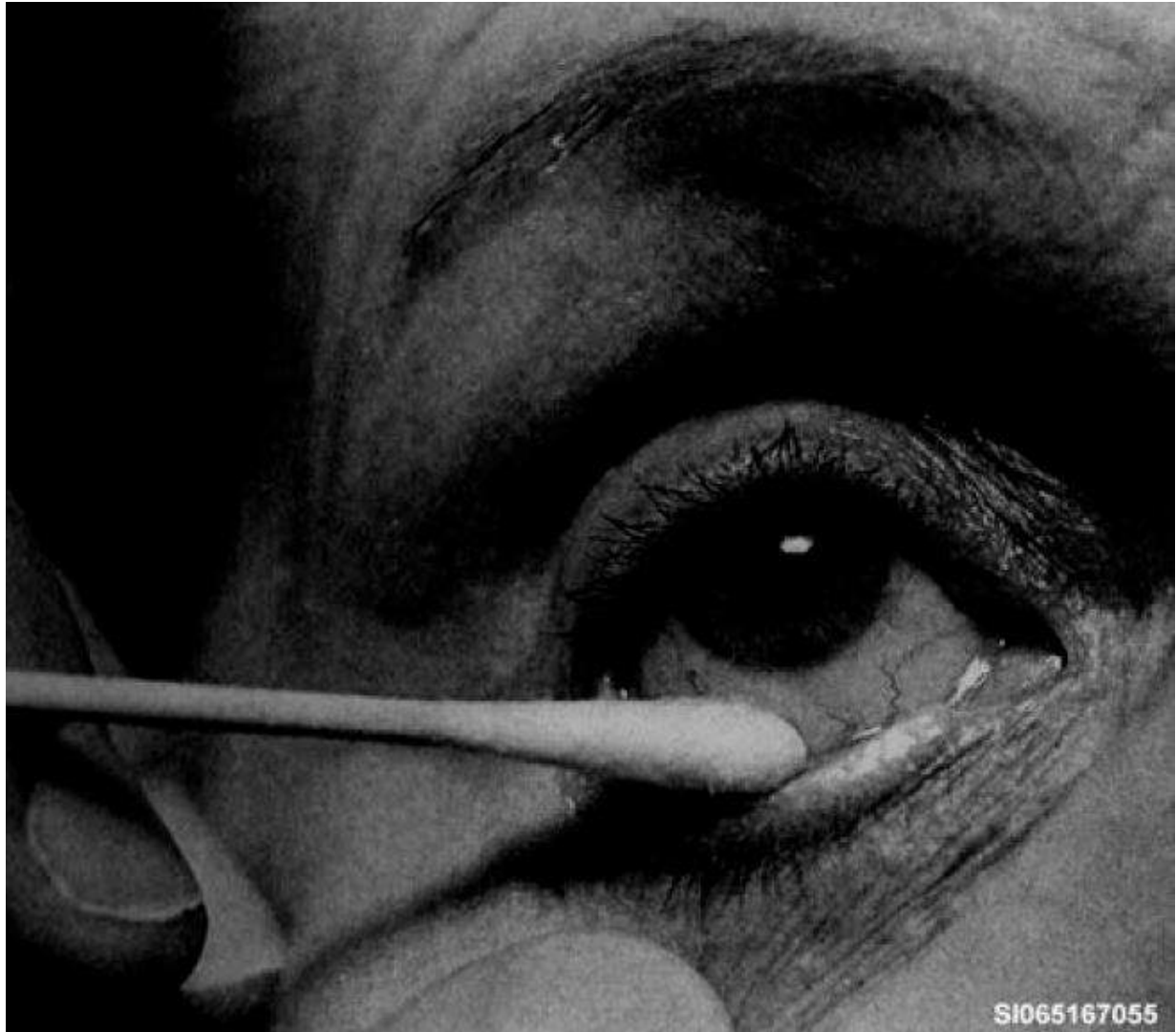

Figure 4-4. Taking a sample of eye flora for lab testing.

Ideally, the appropriate antibiotic should only be selected once the specific type of bacteria present is established. Laboratory personnel then test various drugs against the bacteria to determine the most appropriate course of treatment. This takes time though. The bacteria must be cultured for 24–48 hours before it can be positively identified, and then tested against various antibiotic agents. With early



treatment being so important in fighting off an infection, most doctors start the patient on a broad-spectrum antibiotic that fights many different types of bacteria.

This is often called the “shotgun” approach to treating an infection, but until the specific bacteria is known and what types of drugs affect it, it’s the best approach. The goal is always to use the right drug on the right bug. It just takes a day or two before the correct drug can be identified through laboratory testing on the cultured microorganism.

Broad-spectrum antibiotics attack some gram- positive and some gram-negative bacteria. Unfortunately, they don’t counter them all, which explains why doctors take samples of the flora from the eye when a person presents with an infection (fig. 4–4).

They need to know what bacteria are present in case the broad-spectrum medicine they start with doesn’t work. It’s important to target the specific infection with the correct drug as soon as possible. There are bacteria, such as *pseudomonas aeruginosa* (gram-negative), that can penetrate a compromised cornea in as little as 24 hours.

If some signs are missed when examining a patient where *pseudomonas* might be the causative organism, those few days spent waiting for the laboratory report to come back before starting the appropriate drug could mean the patient losing an eye.

Using just any antibiotic on an infection won’t cut it. Use the patient’s signs and symptoms to get an initial impression of what’s causing the infection. A broad-spectrum antibiotic targeting a suspected organism must be prescribed. The doctor can then wait for the laboratory results to choose a new treatment if necessary.

You can see the importance of patients coming in for a “red eye.” A patient with acute signs of infection must have a swabbed sample of his or her eye discharge sent for laboratory testing. This is usually done if there is no response to initial treatment. The laboratory testing also needs to include a test to determine which of the available antibiotics actually fights the infection. With this information, patients can be treated aggressively and effectively.

With bacteria, fungi, and viruses becoming more resistant to broad-spectrum anti-infectives, doctors need to be more specific and diligent in their choices of medications. Bacteria seem to be especially adept at becoming resistant to medications. This occurs most often when patients are told to use an antibiotic for two weeks or until the bottle is empty. Instead, they take the medicine for a week (or only use half the

bottle) until things seem to clear up. While they may feel better and think the infection is gone, the bacteria are more than likely just on the ropes, and not knocked out yet. Those remaining can now make a comeback, and they become resistant to that medication next time.

As a technician, you can help your doctor underscore the need for patients to take the antibiotic medication exactly as it's prescribed; no matter how good the eye starts to feel in a few days.

What if a person gets a bacterial infection inside the eye or in the tissue surrounding the eye? Topical antibiotic drops are not going to work. These patients require systemic antibiotic treatment and hospitalization. They may be given pills, injections, or combinations of both.

Conditions such as endophthalmitis or orbital cellulitis are very, very serious. Endophthalmitis can lead to massive destruction of intraocular tissues, and blindness or the removal of the eye (enucleation). Orbital cellulitis can lead to cerebral meningitis, possibly causing death.

Obviously, bacteria needs to be taken seriously. Since these severe cases are really beyond the purview of your role in the eye clinic, we do not go into the systemic antibiotics in this lesson; however, you'll look at the topical antibiotics prescribed periodically by your doctor for patients with external, bacterial infections (e.g., blepharitis [staph lid disease], conjunctivitis, corneal ulcers, and keratitis).

**Listed below are some common topical antibiotics. Click on each (+) sign to learn more information.**

### **Bacitracin (AK-Tracin)**



Bacitracin only comes in an ointment form. It's bactericidal and works by destroying the cell walls of bacteria. It's effective against most gram-positive organisms. Since it's not sold in solution form, it enjoys limited popularity; however, it's very popular in treating the staphylococcal form of blepharitis (staph lid disease).

## **Sulfacetamide (Isopto-Cetamide; Sulamyd; Bleph-10; AK-Sulf)**

Sulfonamides are bacteriostatic agents. They are most commonly used in the treatment of childhood bacterial infections caused by streptococcus pneumoniae and haemophilus influenzae. They are available in solution and ointment form, and come in 10 and 30 percent concentrations. For children who are not very cooperative with drops, the 10 percent ointment makes an effective choice. The 30 percent concentration burns more and has more side effects with scarce increase in effectiveness.

The advantages of the sulfa drugs are they work on gram-positive and -negative organisms, and are inexpensive; however, they have many disadvantages. Quite a number of patients are allergic to sulfa drugs, and they do not work well against staphylococcal organisms (which are very common) or pseudomonas (which are very dangerous). Additionally, sulfa does not work well on infections producing a lot of discharge (mucopurulent infections) because the mucous discharge prevents sulfa from being able to kill the bacteria.

## **Erythromycin (Ilotycin®; AK-Mycin®)**

Erythromycin (often abbreviated E-Mycin) is a bacteriostatic agent effective on many gram-positive bacteria and some gram-negative bacteria. It's only available as an ointment, somewhat limiting its use. Many people think E-Mycin is E-Mycin; they grab the same erythromycin they use on cuts and feel they can use it in the eye when it's infected.

This is a good time to remind you so you can remind your patients, there is a huge difference between the "cuts and scrapes" variety of erythromycin and the ophthalmic version of erythromycin—differences such as the concentration of the medicine and additional ingredients in the gel of the medicine. The "treat myself" patient can really do more harm than good by failing to use only ophthalmic quality drugs in the eyes.

E-Mycin is used most often as a prophylactic (preventative) antibacterial when a pressure patch is used on a corneal abrasion. It's also frequently used on sutures and surgical wounds in the eyelid after blepharoplasty (eyelid) surgery. Another popular use is on newborns as a prophylaxis against gonorrhoeae and chlamydial infections possibly picked up during birth.

## **Moxifloxacin (Vigamox®)**

Vigamox® is a fluoroquinolone broad-spectrum antibiotic that fights gram-positive and -negative bacteria. It's very popular due to its effectiveness against a wide range of bacteria. It's an excellent choice against

streptococcus, staphylococcus, and haemophilus types of bacterium. It's also the newest of the antibiotics on the market.

### **Gentamicin (Garamycin®; Genoptic®)** —

Gentamicin is a broad-spectrum antibiotic (effective against gram-positive and -negative bacteria) that is bactericidal. It's available in ointment and solution form, making it a fairly popular choice for treating a wide range of infections. Gentamicin is also effective against pseudomonas, making it an attractive choice when the specific bacteria have not been pinned down. Gentamicin is available generically, which keeps its cost relatively low, making it a likely purchase by the hospital pharmacy folks.

### **Tobramycin (Tobrex®; AK-Tob®)** —

Tobramycin is essentially the same as Gentamicin. It has minor differences in its chemical make-up, making it slightly more effective and slightly less toxic than Gentamicin. It's bactericidal and broad-spectrum, and available in ointment and solution form. It also can be fortified by your pharmacy and is excellent in killing pseudomonas. It isn't replacing Gentamicin because Tobramycin costs more; since the two drugs are so similar, most pharmacies prefer to use the less expensive drug.

### **Polymyxin B** —

Polymyxin B is very good at killing the pseudomonas aeruginosa bacteria. It's bactericidal and effective on the gram-negative bacteria. It's only available in ointment form in the United States, but it's sold in solution form in Canada. Polymyxin B is frequently mixed with other antibiotics to come up with a very effective, broad-spectrum medication.

When mixed with Bacitracin (a gram-positive killer), it's called Polysporin®; it's used to treat blepharitis (due to staph infection) when Bacitracin is not available. Bacteria are not very resistant to Polymyxin B, and toxic and allergic reactions to it are rare, making it a good choice in managing infections where an ointment is suitable.

## Neomycin —

Neomycin is a broad-spectrum, bactericidal drug. It's effective against gram-positive and -negative organisms with the exception of pseudomonas. Unfortunately, it's not currently available in a form all by itself. It's combined with Polymyxin B, and Bacitracin (ointment form) or Gramicidin (solution form) to make the drug Neosporin®. This combination with other antibacterial makes for a very wide spectrum killer of bad bugs. It isn't commonly used because its toxicity causes a hypersensitive reaction in about eight percent of patients within 12 hours to five days. The reaction usually presents itself as redness, eyelid swelling, and SPK. When this occurs, it becomes a case of the "cure becoming worse than the disease" and needs to be discontinued. For this reason, and the fact newer, less toxic, and more effective antibiotics are now available, it's not prescribed very often anymore.

## Trimethoprim —

Trimethoprim is a bacteriostatic medication that is broad-spectrum in its effect, with one exception. It does not affect the pseudomonas bacteria. Because of this, it's only marketed in a form where it's mixed with Polymyxin B, which does kill pseudomonas. In this mixed form, the medication is called Polytrim® and makes an excellent choice for treating children and adults for bacterial conjunctivitis. Adverse effects are rare, making it a safe choice also.

## Fluoroquinolones —

This category of antibiotics represents the most clinically effective bactericidal drugs. They actually work to disrupt the deoxyribonucleic acid (DNA) of the bacteria, bringing about swift death. Bacterial resistance is very low against these drugs. There are many different medications in this category that are made into topical eye drop form: Ciprofloxacin HCl (Ciloxan®), Ofloxacin (Ocuflox®), and Norfloxacin (Chibroxin®). Newer generation medications include Levofloxacin, Gatifloxacin, and Moxifloxacin.

These drugs are used for treating moderate to severe external bacterial infections. The most common use thus far has been in the aggressive treatment of corneal ulcers caused by bacterial organisms. All three drugs are practically identical from a clinical perspective, but the one getting the most usage is Ciloxan®. Ciloxan® is the preferred medication even though Ocuflox® remains in the tear film for a longer time than its virtually identical sibling medications.



Complete the content above before moving on.

## Antivirals

Viruses are some of the nastiest microorganisms around. They cause colds, flu, measles, small pox, herpes, Human Immunodeficiency Virus/Acquired Immunodeficiency Syndrome (HIV/AIDS), and so forth. These viruses are not curable. This is why viruses are so frustrating to the medical professional and the patient infected by them. Viruses are the smallest organisms and can be seen only with an electron microscope or fluorescence microscopy; however, it's rare a doctor needs these devices to make a diagnosis of a viral infection.

Viruses are not like bacteria and fungi in the way they infect and reproduce. Bacteria and fungi are next to the cells they are infecting or are found in the fluid around the eye. Viruses infect by actually penetrating inside the cell. To kill a virus without killing the cell provides a most difficult challenge.

There are three general categories of viruses you'll encounter in the eye clinic: adenovirus (ADV), HSV, and Herpes zoster virus (HZV) (varicella). None are easy to deal with. ADV usually causes a red, watery conjunctivitis. It infects the glands of the body and patients usually have swollen lymph glands, an upper respiratory infection (URI), a fever, and the cornea may be marginally involved. There is no drug treatment for ADV, so it's just a case of letting it run its course. Patients can treat their symptoms, but not much else.

HSV and HZV, on the other hand, can be treated with some medications. These viruses tend to settle in the nerves of the body, not the glands. Of the two, HSV is the more visually threatening. It invades the cells of the corneal epithelium, causing dendritic (branch-like) ulcers, which expose the lower corneal layers. This sounds very painful, but the virus is usually found in the ophthalmic branch of the 5th CN, so the cornea is pretty desensitized already. This loss of corneal sensitivity is a classic sign of HSV.

HZV more commonly affects the skin, but can get in the eyes, so a person with HZV (shingles) must be monitored closely for possible eye involvement showing itself as conjunctivitis, keratitis, or iritis.

Topically applied drugs used to treat viral infections include Idoxuridine (IDU), Vidarabine, and Trifluridine. Acyclovir or valtrex are good systemic antiviral medications and can be taken systemically if they are not available in topical form. Antivirals can be toxic to healthy tissue with extended use. Because of this side effect, it should be discontinued after two-weeks of treatment. Carefully monitor and manage patients on antivirals.

**Listed below are some common antivirals. Click on each (+) sign to learn more information.**

### **Idoxuridine** —

IDU is a topical treatment for viral infections.

### **Vidarabine (Vira-A®)** —

Vidarabine is an antiviral ophthalmic ointment used to fight HSV and HZV so the cornea can heal itself. Patients put the ointment in the eye at night, and let the medication do its work through the extended contact with the cornea.

### **Trifluridine (Viroptic®)** —

Another antiviral agent used to treat HSV and HZV is Trifluridine. It's the standard by which newer topical antivirals are measured. It stops viruses from replicating by inhibiting their DNA synthesis. This makes this drug more effective than IDUs or Vidarabine, while also being less toxic.

Viroptic® comes as a solution, making it a convenient and effective choice in the battle against viral destruction of the cornea. Viroptic® penetrates the cornea well and works on 97 percent of corneal ulcers

caused by viral infection. All this makes it the drug of choice of the antivirals.

### Acyclovir (Zovirax®)

Acyclovir is also a very good antiviral agent. It's currently only available in ointment and tablet form, and used primarily in cases of HZV. Acyclovir is taken orally in most cases, but the ointment is useful when facial lesions appear ready to rupture. The ointment can be applied directly to lesions, hopefully preventing further destruction.

Acyclovir has fewer systemic side effects because it's taken in only by cells infected by the HZV; uninfected cells are not affected. Clinically, it has not been found to be any more effective than Viroptic®, but its less destructive nature toward uninfected cells may make it a better choice in many cases. It definitely gives the eye doctor another viable option when treating herpetic viral infections, and may be best suited in treatment of the HZV (Varicella).



Complete the content above before moving on.

## Antifungals

Fortunately, fungal infections are rare because when they do occur, they are devastating. Have you ever heard of a fungus called histoplasma? It's the cause of a condition called histoplasmosis, causing widespread retinal scarring and blindness. There are many other fungal infections, but this one you may have already heard of in your clinic.

With the increasing use of corticosteroids in treating inflammations, the occurrence of fungal infection also seems to be rising. Steroids subdue the body's natural immune response, allowing things like fungi to get a foothold. Killing off fungi can be difficult. The sooner a fungal infection can be treated, the better the chances of getting rid of it. Let's look at antifungals currently used to treat fungal eye infections.

### Natamycin or Pimaricin (Natacyn)



As of this writing, there is only one antifungal agent available commercially in the United States that is FDA approved for use on topical treatment of ocular fungal infections--Natacyn. It's available as a suspension so it needs to be shaken well before use. It's effective against a wide variety of fungi to include Candida, Aspergillus, Cephalosporium, Fusarium, and Penicillin. It's the drug of choice for fungal keratitis, but becomes less effective in fungal ulcers as it does not penetrate very well.

## Amphotericin B (Fungizone)

There are other antifungal medications around; they just weren't designed with an ocular use in mind, so some of them need to be diluted to be safe for eye use. Others are systemic medications more useful in fungal infections that have gotten to the deeper ocular structures of the eye. One such antifungal medication is Amphotericin B. This is the drug of choice for treatment of systemic fungal infections (e.g., histoplasma capsulatum and candida). It's also available in solution form where it can be diluted and used topically for external fungal infections (e.g., keratitis and ulcers).



Complete the content above before moving on to the self-test questions.

**Self-Test Questions. After you complete these questions pertaining to the anti-allergic, anti-inflammatory, and anti-infective ophthalmic medications, you may check your answers at the end of this module.**

1. The weakest decongestants are a good choice for treating what condition?

Type your answer here

SUBMIT

2. What role does zinc play when mixed with Phenylephrine and Naphazoline to form a moderate decongestant agent for the eyes?

Type your answer here

---

SUBMIT

3. Antihistamines, the strongest ocular anti-allergy (decongestant) drug available OTC, are a combination of what?

Type your answer here

---

SUBMIT

4. What does a mast cell stabilizer prevent? What problem is this drug best used to control or treat?

Type your answer here

---

SUBMIT

5. What do NSAIDs control? How do they do it?

Type your answer here

---

SUBMIT

6. What patients are most often prescribed Diclofenac sodium (Voltaren)? What is this medication's advantage over most steroids?

Type your answer here

---

SUBMIT

7. What can lead to miosis during cataract surgery? What NSAID(s) can help prevent it?

Type your answer here

---

SUBMIT

8. When is Ketorolac Tromethamine (Acular) most commonly used?

Type your answer here

---

SUBMIT

9. What concentrations does Prednisolone come in? What is each version good for treating?

Type your answer here

---

SUBMIT

10. Name the steroid that is useful in treating blepharodermatitis.

Type your answer here

SUBMIT

11. When is it appropriate to prescribe Fluorometholone?

Type your answer here

SUBMIT

12. When is using a steroid-antibiotic combination drug considered prudent?

Type your answer here

---

SUBMIT

13. What are the two basic antibiotic agents?

Type your answer here

---

SUBMIT

14. Why does it matter whether a bacteria gram-stains blue (positive) or red (negative)?

Type your answer here

---

SUBMIT

15. How long does it take for bacteria to be cultured in the laboratory and be tested against various antibiotic agents?

---

- ☐ 24 hours
- ☐ 24-48 hours
- ☐ 36 hours
- ☐ 12-24 hours

SUBMIT

16. Explain the “shotgun” approach to treating an infection.

Type your answer here

---

SUBMIT

17. Which bacteria can penetrate a compromised cornea in as little as 24 hours?

Type your answer here

---

SUBMIT

18. What is a common cause for bacteria becoming resistant to antibiotic medications?

Type your answer here

---

SUBMIT

19. What is an eye condition (infection) that can lead to massive destruction of intraocular tissues, and to blindness or enucleation (removal of the eye)? What



condition can lead to death?

Type your answer here

---

SUBMIT

20. For what purpose is Bacitracin commonly used?

Type your answer here

---

SUBMIT

21. Give the disadvantages of Sulfacetamide.

Type your answer here

---

SUBMIT

22. Give the three most common uses of Erythromycin (E-Mycin).

Type your answer here

---

SUBMIT

23. What two broad-spectrum, pseudomonas-killing drugs are essentially the same?

Type your answer here

---

SUBMIT

24. Which antibiotic is mixed frequently with other antibiotics to come up with a very effective, broad-spectrum medication?

---

☐

Gentamicin

- ☐ Neomycin
- ☐ Idoxuridine
- ☐ Polymixin-B

SUBMIT

25. Name two drugs that are only available in a form where they are mixed with another drug.

Type your answer here

---

SUBMIT

26. Which category of antibiotics actually works to disrupt the DNA of bacteria?

Type your answer here

---

SUBMIT

27. For what purpose is Ciprofloxacin HCl (Ciloxan) used?

Type your answer here

---

SUBMIT

28. How are viruses different from bacteria and fungi in the way they infect cells?

Type your answer here

---

SUBMIT

29. Give the three categories of viruses that you encounter in the eye clinic.

Type your answer here

---

SUBMIT

30. Which virus cannot be treated and must just “run its course?”

---

☐

ADV

☐

HSV

☐

HZV

SUBMIT

31. Why is HSV a threat to vision?

Type your answer here

---

SUBMIT

32. What is the danger in extended use of antivirals?

Type your answer here

---

SUBMIT

33. Name the four antiviral medications.

Type your answer here

---

SUBMIT

34. Which antiviral is the current “drug of choice?”

Type your answer here

---

SUBMIT

35. Which antiviral is used primarily in treating HZV?

Type your answer here

---

SUBMIT

36. What is the only FDA-approved antifungal for topical, ocular use? What fungi is it effective against?

Type your answer here

SUBMIT



Complete the self test questions above before moving forward in the lesson.



## Ophthalmic Health Enhancing Products

You may have heard various research claiming certain products can prevent or delay eye problems or disease. This lesson goes into some of these products and their purported health-promoting attributes. Most of the dry eye products listed below are FDA approved prescription medications; however, the



vitamins, herbs, and supplements listed below are not. The FDA treats these products more like special foods. As such, they aren't put through the same strict safety and effectiveness requirements that drugs are.

As you read the lesson and discuss these products with your patients, please keep in mind that dietary vitamins, herbs, and supplements are considered safe until proven otherwise. This means they are found unsafe only after they cause harm. Ensure your patients are aware of the potential risks associated with using these products.

## Dry Eye Products

A piece of dust floats through the air and lands in your eye. Your body reacts to it if it maintains contact with tissue, but you have no allergic reaction because the natural tears and blinking action of your eyes washed the offending dust particle away before it could cause a reaction. The tears are the most important first defense for the eye. They wash matter away before it causes a reaction.

In patients who are having minor allergic symptoms, a good starting point toward solving a problem may be to check their tear production. Low tear production means a reduced barrier to things irritating the eye. Patients with dry eyes often complain of their eyes feeling gritty and irritated. Since they can't stimulate more tear production, most doctors recommend using an artificial tear solution. The best kind is one that doesn't contain a preservative, which may cause an allergic reaction in certain patients.

Treatment for dry eye typically consists of using artificial tears during the day and ointment at bedtime. Some of the following preservative-free artificial tear solutions may be prescribed by your doctor:

- Refresh Plus
- OcuCoat PF
- Hypotears PF
- Dry Eye Therapy
- Restasis (available by prescription)

The nice thing about most artificial tears is they can be purchased OTC, do not harm patients, and can be used as needed. The eyes feel better; quite often, artificial tears solve mild allergic, irritated eye problems patients may experience.

Most doctors discourage the use of medications such as Relief, Prefrin, Visine “Red Out,” or any artificial tear marketed to “get the red out.” They contain phenylephrine to alleviate the redness, but there can be a rebound effect with continued use. The phenylephrine causes vasoconstriction (shrinks the blood vessels), making the eyes look clear and white. As the phenylephrine in the drops wear off, the body starts to counteract the drug’s effect with vasodilation, and the redness is worse than before the person used the drops—a vicious cycle. Patients are better off soothing their eyes with artificial tears and allowing the redness to go away naturally.

Vitamin A may offer some relief from dry eye. Additionally, the use of omega-3 capsules (fish or flaxseed oil) can also have a beneficial effect in treating the disorder.

## **Vitamin, Mineral, and Herbal Supplements**

While vitamin and mineral supplementation is not an exact science, preliminary studies have shown great promise in treating or delaying the onset of some major degenerative eye diseases (e.g., cataracts, age-related macular degeneration [ARMD], glaucoma, and diabetic retinopathy [DR]).

These eye diseases, like the aging process, are believed to be caused by an excess of free radicals. Free radicals are reactive molecules within the body that not only help break down accumulated toxins, dead cells, and waste products, but also damage healthy cells through a process called oxidation. To combat these excess free radicals and their oxidizing effects, we must reduce our exposure to them, get moderate exercise, not smoke, drink alcohol only in moderation, and eat a healthy diet containing essential vitamins and minerals, especially antioxidants.

In a perfect world, you get the vitamins and minerals you need through a well-balanced diet; however, most Americans do not abide by the dietary recommendations which include five to nine servings of fresh fruits and vegetables each day, which contain a large portion of the antioxidants needed to combat excess free radicals. This is where vitamin and mineral supplementation comes in.

The major vitamin and mineral supplements in eye health and their suspected actions can be found in the following table:

Vitamins and Supplements					
Vitamin	Action on Cataracts	Action on ARMD	Action on Glaucoma	Action on DR	Additional Action(s)/Information
Vitamin A	Prevents formation of all types	Prevents blindness from ARMD			<ul style="list-style-type: none"> <li>- Prevents blindness in developing countries caused by xerophthalmia (severe vitamin A deficiency)</li> <li>- Essential for night and color vision</li> <li>- Helps to prevent dryness in the eyes</li> <li>- Ensures proper functioning of the retina</li> </ul>
Vitamin C	Protects against light-induced cataracts	Delays onset	Decreases IOP	Protects against blood vessel damage	<ul style="list-style-type: none"> <li>- Helps with the maintenance of collagen tissue in the eyes</li> <li>- Can't be created or stored in body</li> </ul>
Vitamin D		Lowers risk of macular degeneration (MD)			
Vitamin E	Protects against light-induced cataracts	Prevents ARMD		Protects against blood vessel damage	
Carotenoids (i.e., beta-carotene, lutein, etc.)	Prevents nuclear cataract formation	<ul style="list-style-type: none"> <li>- Protects retina from free radical damage</li> <li>- Improves visual function in "dry" ARMD</li> </ul>			<ul style="list-style-type: none"> <li>- Well established cancer prevention properties</li> <li>- Supplemental beta-carotene use has been associated with a greater risk of cancer among smokers or previous smokers</li> </ul>
Zinc		Protects against ARMD			Helps body absorb vitamin A

Vitamins and Supplements

---

Vitamins and Supplements					
Vitamin	Action on Cataracts	Action on ARMD	Action on Glaucoma	Action on DR	Additional Action(s)/Information
Zeaxanthin	Reduces risk of cataracts	Protects against ARMD			Protects the retina from oxidative changes caused by ultraviolet light
Selenium		Slows progression			Helps body absorb vitamin E
Chromium			Helps to maintain balanced IOP		
Magnesium			Improves VFs and decreases peripheral vasospasms	Slows onset of severe DR	
Alpha lipoic acid	Protects against oxidative stress in crystalline lens		Enhances color VFs and visual sensitivity	Protects against neuropathy in diabetics	
Omega-3 & Omega-6 essential fatty acids (i.e., fish or flaxseed oil)	May help to prevent cataract formation	Protects against ARMD			Helps restore and maintain tear formation and eye lubrication
Acai Berry			Helps balance IOP		
Copper		Protects against ARMD			
Supplement	Action on Cataracts	Action on ARMD	Action on Glaucoma	Action on DR	Additional Action(s)/Information
Bilberry extract (from European blueberries)	Slows progression of senile cortical cataracts	Slows progression of visual loss in ARMD		Helps maintain blood vessel permeability	Reverses poor day and night vision
Riboflavin	Prevents formation of all types	Improves VA			
Ginkgo biloba	Provides protection from oxidative stress in the body, to include the eyes				

#### Vitamins and Supplements

As stated previously, vitamin and mineral supplementation is not an exact science. At this time, the benefits of supplements for eye health fall into the category of pure speculation. Ask 10 different doctors and you'll get 10 different opinions on the benefits (or lack thereof) of supplements. This is partly because the business of supplements is largely an unregulated industry. Where FDA-approved medications must

undergo years of rigorous testing before being released to consumers, megavitamins, on the other hand, touting anything from hair growth to increased sex drive can find their way to supermarket shelves practically overnight.

With that said, the best recommendation for the prevention of degenerative eye diseases is to eat a well-balanced diet rich in green leafy vegetables, take a supplement (it couldn't hurt), stop smoking (especially important for those with ARMD), wear sunglasses outdoors, and exercise on a daily basis.



Complete the content above before moving on to the last set of self-test questions.

**Self-Test Questions. After you complete these questions pertaining to the ophthalmic health enhancing products, you may check your answers at the end of this module.**

1. Why are preservative-free artificial tears preferred?

Type your answer here

SUBMIT

2. Why do doctors recommend not using an artificial tear medication that has phenylephrine as an ingredient?

Type your answer here

---

SUBMIT

3. Name the good effects of free radicals on the human body. The bad effects.

Type your answer here

---

SUBMIT

4. What do Omega-3 & Omega-6 essential fatty acids supposedly help with?

Type your answer here

---

SUBMIT

5. What's the best recommendation for the prevention of degenerative eye diseases?

Type your answer here

---

SUBMIT



This completes Lesson 4 of Module 2. You will need to go to myLearning to complete the unit review exercises (UREs).

## Module 2: Self-Test Question Answers

---



# Self-Test Question Answers

---

## LESSON 1

---

### 201: Ocular adnexa

1. Eyebrows, eyelids, eyelashes, glands, and lacrimal system.



2. Divert perspiration from the eye.

3. To spread tears across the cornea.

4. Lateral canthus, medial canthus, plica semilunaris, and caruncle.

5. (1) Levator palpebrae superioris.

(2) Muscle of Muller.

6. (1) Orbicularis oculi.

(2) Riolan's muscle.

7. The tarsal plate.

8. The bulbar conjunctiva; no.

9. Goblet cells; mucin.

10. They are surrounded by a network of super sensitive nerves that cause the lids to quickly close if debris touches the lashes.

11. Oils; tears.

12. Meibomian (oil).

13. An external hordeolum or styne can develop.

14. The palpebral conjunctiva.

15. Lacrimal gland, lacrimal canals (ducts), conjunctival sac, puncta, canaliculi, lacrimal sac, and nasolacrimal ducts.

## **202. The bony orbit**

1. Pear-shaped—big at the anterior (front) and narrow at the posterior (rear).

2. They run straight back and are parallel to each other.

3. 45°.

4. 90°.

5. (1) Sphenoid.

(2) Ethmoid.

(3) Lacrimal.

(4) Frontal.

(5) Maxilla.

(6) Palatine.

(7) Zygomatic.

6. Lesser sphenoid and frontal.

7. (1) Maxilla.

(2) Ethmoid.

(3) Lacrimal.

(4) Lesser sphenoid.

8. (1) Maxilla.

(2) Palatine.

(3) Zygomatic.

9. Zygomatic and greater sphenoid.

10. Ethmoid; zygomatic; palatine.

11. (1) Fissures (cracks).

(2) Foramina (holes).

12. Optic nerve (CN II) and ophthalmic artery.

13. Between the greater and lesser wings of the sphenoid.

14. The portion of the maxillary bone that covers the infraorbital groove/canal.

15. (1) Lacrimal sac fossa located in the lacrimal bone.

(2) Lacrimal gland fossa located behind the orbital rim of the superior, temporal portion of the frontal bone.

(3) Trochlear fossa located in the superior, nasal portion of the frontal bone.

**203. Extraocular muscles: origin, insertion, and action**

1. Straight ahead.

2. (1) SR.

(2) IR.

(3) MR.

(4) LR.

(5) SO.

(6) IO.

3. IO.

4. To the sclera on top of the eye, anterior to the equator, approximately 7.7 mm from the limbus.

5. Oculomotor nerve (CN III).

6. Abduction.

7. Trochlear pulley.

8. Intorsion; Depression.

9. Trochlear nerve.

10. SO.

11. The anterior, medial floor of the bony orbit.

12. Wraps under the eye and extends rearward and temporally, passing over the IR muscle, and up under the LR muscle, and attaches posterior to the equator on the temporal side of the eye.

13. IO.

14. Extorsion; elevation.

15. It's a formula to remember which CNs innervate which muscles. LR6 means the LR is innervated by the 6th CN, the abducens nerve; SO4 means the SO is innervated by the 4th CN, the trochlear nerve; and 3 means all the other EOMs are innervated by the 3rd CN, the oculomotor nerve.

16. Quick, voluntary, simultaneous movements of both eyes in the same direction; fixation, refixation, and rapid eye movements.

17. Slow, involuntary, parallel movements of both eyes that allow us to follow moving objects.

18. The muscle that is the prime mover for a desired direction of gaze.

19. Muscle in the same eye as the agonist that works directly against the agonist.

20. Synergistic.

21. Parallel, conjugate (conjunctive) movements often referred to as version movement.

22. Disjunctive.

23. RLR; RSR; LSO.

24. Movement of one eye.

#### **204. Eyeball anatomy**

1. Cornea and sclera.

2. 12 mm wide (horizontally) and 11 mm tall (vertically).

3. Refract light.

4. It does not contain any blood vessels.

5. 5th, the trigeminal nerve.

6. (Corneal) epithelium, Bowman's layer, stroma (substantia propria), Descemet's membrane, and endothelium.

7. Usually within 24 hours; no.

8. It's acellular (without cells), very thin, and made up of collagen fibers; very resistant to trauma and acts as a barrier to microorganisms; and scars if damaged.

9. The epithelium and endothelium.

10. Its fibers swell and get cloudy, decreasing VA.

11. One-cell layer.

12. To pump waste from the stroma and maintain the cornea's normal, dehydrated state.

13. Endothelial cells don't regenerate; the neighboring cells move over and enlarge to fill in the empty space.

14. Gives the eye support needed to maintain the structures within it, and provides an insertion point for the six EOMs.

15. The lamina cribrosa.

16. The episclera.

17. Uveal tract.

18. The amount of pigmentation built up on the front of the iris.

19. Controls pupil size, regulating the amount of light entering the eye.

20. (1) Dilator (longitudinal).

(2) Sphincter (circular).

21. Pars plicata and pars plana; the pars plicata.

22. The ciliary processes (small projections just behind the iris).

23. Relaxing.

24. The ciliary muscle contracts (works), relaxing the zonules, allowing the lens to fatten and become more curved.

25. Pars planitis.

26. Iris, ciliary body, retina, and inner sclera.

27. Ora serrata.

28. The retina.

29. (1) Optic disc.

30. Fovea centralis (foveola).

31. RPE; internal limiting membrane.

32. 10 and nine

33. To absorb excess light and serve as a nourishing and garbage collection layer for the rods and cones.

34. The rods and cones.

35. 400 nm; 750 nm.

36. Approximately 125 million; approximately 6 million.

37. Rhodopsin.

38. Photopic or fully illuminated conditions (daylight).



39. Erythrolabe; chlorolabe; cyanolabe.

40. Passes on the electrochemical message produced by the rods and cones to the retinal ganglion layer.

41. The axons.

42. The central retinal artery (CRA) and choriocapillaris.

43. Cornea, aqueous humor, crystalline lens, and vitreous humor.

44. Aqueous production and outflow.

45. About 10 mm in diameter; about +16.00D.

46. (1) Capsule.(2) Cortex.(3) Nucleus.

47. A thin vitreous membrane.

48. Provides internal support, helping the eye maintain its shape and keeping the retina in contact with the choroid.

49. Vitreous does not regenerate or reproduce itself.

## **205. Visual-pupillary pathway**

1. Afferent (sensory).

2. Ganglion cell axons from the retina.

3. Temporal ganglion cell axons from one eye and the nasal ganglion cell axons from the other eye.

4. A relay station.

5. Geniculo-calcarine tract.

6. The occipital lobe (Brodmann's area 17).

7. First.

8. Three orders; synapses occur when rods and cones send their electrochemical message to the retinal ganglion cells (within the retina), and from the LGB to the optic radiations (within the LGB).

9. Dendrite, cell body, and axon.

10. (1) Retina.

(2) Optic nerve.

(3) Optic chiasm.

(4) Optic tract.

(5) Pretectal nucleus.

(6) Edinger-Westphal nucleus (accessory CN III).

11. A motor message that exits the brain.

12. (1) CN III.

(2) Ciliary ganglion.

(3) Iris sphincter muscle.

## **206. Visual acuity and refractive status of the eye**

1. The eye's ability to distinguish object details and shape and is assessed by the smallest identifiable object that can be seen at a specified distance (usually 20 feet for distance acuity and 16 inches for near acuity).

2. How comfortably one sees.

3. (1) Region of the retina stimulated.

(2) Illumination.

(3) Spectral quality of the light.

(4) Contrast.

(5) Pupil size.

(6) Time of exposure.

(7) Patient's age.

(8) Condition of the ocular media.

(9) Presence of ametropias.

(10) Individual variations.

4. 400 to 750 nm.

5. 20/400.

6. Refractive error (e.g., hyperopia, myopia, or astigmatism).

7. They are focused perfectly on the retina without the need for accommodation or corrective lenses.

8. (1) Axial problems (length of eye is too short).

(2) Curvature problems (curve of the cornea or crystalline lens is too flat).

9. Accommodate (focus) enough to bring the light rays to a focus on the retina.

10. Complaints of eye fatigue or blurriness toward the end of the day, or their eyes fatigue quickly while reading.

11. Decreased distant vision and even worse near vision.

12. In front of the retina.

13. Minus lenses.

14. More than  $-6.00D$ .

15. An optical defect in which refractive power is not uniform in all meridians of the eye.

16. Where one meridian of the eye focuses the light rays correctly on the retina, and the meridian  $90^\circ$  away focuses the light rays too soon (SMA) or too late (SHA).

17. Compound myopic astigmatism; compound hyperopic astigmatism.

18. CMA.

19. Focuses one meridian in front of the retina and focuses the meridian 90° away beyond the retina.

20. Where the cylinder power is needed to correct the blurriness in the patient's vision.

21. Decreased DVA, decreased night vision, or needing to squint to see objects.

22. Yes.

23. It is a condition of age; decrease in our ability to accommodate.

24. About age 40.

25. Reading glasses or bifocals to replace the lost plus (+), or accommodative, power of the eye when looking at near objects.

26. +0.12D.

27. +2.50D.

28. Hold it farther away as it takes less accommodative power to see objects farther from the eyes.

29. If you live 40 years or longer, presbyopia is going to occur.

30. Yes, in facultative hyperopes.

### **207. Depth perception, color, and night vision**

1. (1) Magnification (relative size).

(2) Confluence of parallel lines to a point (perspective).

(3) Interposition of shadows (overlay).

(4) Blue-gray mistiness of objects at a great distance (distant haze).

(5) Parallax.

(6) Stereopsis.

2. Secondary.

3. Stereopsis.

4. As little as 5" of arc.

5. Patients with suppression, amblyopia, tropias, or other eye problems that limit them to only one functional eye.

6. No; they don't have binocularity and a heterotropic patient does not have SBV.

7. (1) Hue.

(2) Saturation.

(3) Brightness.

8. The wavelength of the light emitted or reflected from an object.

9. The purity of a color.

10. The fire engine red.

11. By mixing it with white.

12. The rate of transfer of light energy coming off a particular color; also to the amplitude, or amount of energy, of the light reaching our eye.

13. 500,000.

14. A mixture of red, orange, yellow, green, blue, indigo, and violet.

15. (1) Red.

(2) Green.

(3) Blue.

16. Photopic; scotopic.

17. Trichromat.

18. 92; 99.5.

19. Anomalous trichromats.

20. Green.

21. 2.6.

22. They are blue-blind and have trouble with yellow and blue.

23. Monochromat.

24. About one in 13 million.

25. X.

26. Red or green.

27. The problem is pathological (or acquired) and is being caused by some eye or systemic ailments.

28. Shift our gaze slightly to the side and use the rods of the retina.

29. 20/200 to 20/400.

30. Blue.

31. Night blindness.

---

## LESSON 2

---

### 208. Basic parts of medical terminology.

1. A letter or group of letters placed before a root word.

2. In medical terminology, they are words pertaining to the body part, tissue, or organ to which you are referring or working.



3. Letters added to the end of root words to make a whole word with a specific meaning.
4. Look at the sentence in which the word appears and from how the word with a suffix is used, it will determine its exact meaning.

### **209. Combining forms**

1. We use the vowel with the root word.
2. If a suffix begins with a vowel, do not use the -o-.

### **210. Lid disorders**

1. A very common inflammation of the eyelid margins.
2. Scrub clean the eyelid margins with a warm, moist washcloth with 10:1 ratio of diluted baby shampoo.
3. An internal hordeolum is an infection of the meibomian gland; an external hordeolum is an infection of the glands of Zeis. Both are caused by an acute infection in the sebaceous (oil) glands of the eyelids.
4. A hordeolum is a bacterial acute infection in the meibomian gland of the eyelids; the chalazion is a chronic inflammation of the gland with no infection.
5. Systemic neuromuscular problems, trauma to the eyelid, nerve palsy (paralysis), or physical muscle interference.
6. It can be fatal within just a few days if left untreated.
7. Treatment includes hospitalization, IV, and oral and topical antibiotics.

8. In perceptual cellulitis the infection is confined to the soft tissues that are anterior to the tarsal plate, unlike orbital cellulitis, which can be found posterior to the tarsal plate and involve the whole orbital cavity.

9. Overflow of tears.

10. Corneal abrasions, ulcerations, and scarring.

11. Laxity of the lower lid retractors and buckling of the upper tarsal plate border.

12. It's the turning out of the eyelid; exposure keratitis.

### **211. External tumors**

1. A malignant tumor continues to grow and invades healthy tissue if not treated, and it may or may not spread to other body systems; a benign tumor generally is nonfatal, nonmalignant, and usually localized.

2. (1) Nevus.

(2) Papilloma.

(3) Molluscum contagiosum.

(4) Xanthelasma.

(5) Keratoacanthoma.

3. Molluscum contagiosum; because toxic debris from the lesion can end up in the tears and, thus, affect the conjunctiva.

4. Xanthelasma.

5. Spreads to the rest of the body.
6. To ensure no cancerous cells are left behind.
7. Basal cell carcinoma.
8. Lymphatic.
9. The sebaceous (oil) glands.

### **212. Conjunctival and corneal disorders**

1. Itching, mild to moderate redness of the eye, and stringy discharge.
2. When one or more of the small conjunctival blood vessels ruptures, and the blood is trapped between the conjunctiva and the sclera.
3. Coughing, straining, vomiting, or vigorous sneezing.
4. A benign (harmless) thickening of the conjunctiva, usually located in the medial canthus area, but not always. It's common where people spend a great deal of time outdoors in dry, dusty environments and may be exposed to the harmful effects of UV light.
5. A growth of abnormal conjunctival tissue onto the cornea; is vascular and involves all the layers of the bulbar conjunctiva.
6. Keratoconjunctivitis sicca; an eye that has a deficiency in tears.
7. Due to lowered lacrimal production, the conjunctiva and cornea are chronically irritated, which may lead to erosions of the cornea and eventual scarring of the cornea.

8. An area of epithelial tissue loss from the corneal surface associated with bacterial, viral, fungal, or parasitic infection of the eye.
9. In patients who wear extended wear soft CLs, or had exposure to hot tubs, communal baths, or even plain tap water.
10. It can cause severe eye infections with corneal “melting” and rapid loss of the eye within days.
11. A corneal inflammation.
12. An inflammation of the stroma and appears as a disc-shaped, gray, opaque lesion.
13. The inability to fully close the eyelids.
14. A degenerative corneal disorder characterized by thinning of the cornea and development of a cone-shaped protrusion.
15. RGP CLs are a significant help in correcting vision and have been found to seemingly slow the progression of the condition; with decreased vision that cannot be corrected with RGP CLs any longer, patients may be considered as candidates for possible corneal transplant.

### **213. Eye infections**

1. Pathogenic.
2. Some discharge, grittiness, redness, and swelling.
3. Morphology.
4. Round, rod, and spiral.

5. Gram-positive.

6. Important when choosing an antibiotic to fight the infection because some drugs are good at killing gram-negative bacteria, while others are better at killing gram-positive bacteria.

7. *Staphylococcus epidermidis*.

8. Strep.

9. Gonococcal.

10. *Hemophilus aegyptius* (Koch-Weeks bacillus).

11. *Pseudomonas aeruginosa*.

12. HSV, HZV, ADV, and HIV.

13. HSV; 500,000.

14. Very insensitive; the virus affects the ophthalmic division of the trigeminal (5th) cranial nerve.

15. HSV .

16. There is a 50 percent chance of ocular involvement.

17. It's quite contagious.

18. The eye or eyes are extremely red and produce copious amounts of watery discharge; conjunctiva and corneal involvements are the main characterizations.

19. PCF.

20. Essentially nothing more than letting the infection run its course.
21. Infecting and depleting the body of its T4 helper lymphocytes.
22. 30.
23. Cytomegalovirus retinitis.
24. Only by exposure to blood and its components, and sexual contact.
25. On plant matter and dirt.
26. They breathe in a dry particle of bird feces with the fungus in it, which gets in the warm, moist lungs, and enters the bloodstream.
27. For some reason, it reactivates the histoplasmosis fungus so that it can do more damage and spread further. For a patient with a histo spot (lesion) near the macula, this reawakening could lead to blindness.
28. Aspergillus.
29. Months or even years.
30. IV administration of the antifungal drug amphotericin B; removing some of the infected vitreous to make room for injecting the drug directly into the vitreous chamber; or the patient can orally take a drug called Flucytosine.
31. It doesn't seem to occur in healthy patients.

#### **214. Inflammatory conditions and disorders**

1. The protective response that begins when body tissue is invaded by a foreign substance.
2. A general term referring to inflammation of the uveal tract.
3. (1) Anterior uveitis (iritis/iridocyclitis).  
  
(2) Intermediate uveitis (pars planitis).  
  
(3) Posterior or panuveitis (chorioretinitis).
4. Iritis is an inflamed iris; iridocyclitis is an inflammation of the iris and ciliary body.
5. (1) Any four of the following:  
  
(2) Photophobia (light sensitivity).  
  
(3) Tearing.  
  
(4) Blurred vision.  
  
(5) Constricted or irregular pupil.  
  
(6) Red eye with the injection (engorgement of the blood vessels) of the episclera most pronounced near the limbus.
6. Because the inflamed iris could come in contact with and adhere to the crystalline lens or cornea (synechia). If this occurs, an acute glaucoma attack is very likely.
7. Blurred vision or floaters without pain or photophobia. It can be very minor, causing no symptoms, and then resolving spontaneously, or quite serious, causing macular edema and significant decreases in vision.

8. Because of the close physical relationship of the choroid and retina.
9. The underlying systemic problem needs to be found and then treated until it's resolved.
10. Inflammation of the optic nerve head, which can produce vision loss as severe as light perception only.
11. Papillitis is a localized swelling at the nerve head and easily seen through ophthalmoscopy; retrobulbar neuritis is an optic neuritis occurring behind the optic disk.
12. Multiple sclerosis—a demyelinating disease.
13. Unilateral vision loss (variable), pain with eye movement, central scotoma (blind spot), color vision defects, and pupillary defects.
14. To ensure it's optic neuritis and not a more chronic, systemic neurological problem or tumor, and ensure the neuritis is resolving properly.

#### **215. Systemic medical conditions with ocular disorders**

1. By hindering the blood flow to the retina.
2. DR.
3. Chronic elevated blood sugar level in diabetic patients. Therefore, diabetics with well-controlled glucose levels have a lower incidence of DR.
4. (1) Stage 1 – background DR.  
  
(2) Stage 2 – preproliferative DR.



(3) Stage 3 – proliferative DR.

5. Microaneurysms (bulges in a blood vessel caused by weakening of the blood vessel walls), dot and blot hemorrhages, loss of capillary function, and lipid exudates (leakage from the vessels).

6. Abnormalities of the microvascular system caused by DR.

7. This essentially kills significant portions of the peripheral retina, reducing the retinal demand for oxygen, which spares the central vision area of the retina and allows the retinal vasculature to concentrate its oxygen flow to the central retina.

8. It dies or finds a way to get more oxygen.

9. Growth of fibrous tissue creates traction on the retina.

10. Arteries cross over top of the veins in the eye; if the arteries are under a great deal of pressure, they can press on the vein and block it off.

#### **216. Conditions and disorders causing sudden vision loss or vision degradation**

1. CRAO.

2. Move the embolus out of the CRA and get it down one of the arterial branches.

3. When an artery appears to be denting in a vein.

4. Dilated and engorged veins (they are full and can't drain), intraretinal and nerve fiber layer hemorrhages, swollen optic disc margins, and retinal thickening.

5. Enough force is generated (by minor trauma, eye movement, etc.) to allow vitreous fluid to begin to work its way through the tear and get under the retina.

6. Flashes of light and an increase in the number of floaters in the affected eye.
7. With a YAG laser to tack down the retina, or a cryoprobe (freezing) surgery to freeze and scar the retina back into place.
8. Remnants of the hyaloid artery that was present in the vitreous during our development in mom's womb, or from flecks of pigment that have somehow gotten into the vitreous.
9. Posterior vitreous detachment.
10. Sudden, painless loss of vision as the blood filling the vitreous prevents light from reaching the retina.
11. Tiny, opaque, calcium deposits.

### **217. Other internal conditions and disorders**

1. Opacities or cloudiness of the crystalline lens; protein clumping and fiber swelling within the lens.
2. (1) Age-related.  
  
(2) Congenital.  
  
(3) Acquired (trauma or disease).
3. By some faint whitish-gray clouding of the lens, and an increased density at the center of the lens, causing it to thicken in the middle slightly.
4. It increases the density at the center of the lens, causing it to thicken in the middle slightly, which gives the lens more power and focusing light sooner.

5. PSC.

6. During embryonic development in the mother's womb; at birth.

7. The chances of the patient developing normal vision, even after the cataract is eventually removed, are very slim.

8. Aqueous and vitreous fluid is allowed to enter the lens capsule; this fluid is absorbed by lens fibers, causing them to swell and cloud due to the metabolic imbalance.

9. Intracapsular, extracapsular, or phacoemulsification.

10. Phacoemulsification.

11. Phakic; aphakic; pseudophakic.

12. Shine a penlight in the person's eye. If you see a shimmering reflection just behind the cornea, you know the person has an anterior chamber IOL; you can actually see the lens.

13. Elevated IOP, optic disk cupping, and VF loss.

14. A mechanical blockage of the angle at the root of the iris.

15. Angle-closure.

16. The one with angle-closure glaucoma has a shallow anterior chamber and a narrow entrance into the angle.

17. The patient begins to experience pain as the pressure rises higher. The pain can vary from a feeling of discomfort and fullness around the eye or eyes to a severe, disabling pain that can radiate to the back of the head or down toward the teeth. With severe pain, the patient becomes nauseated and may even vomit. Usually, the vision is reduced to mere perception of light. The patient sees halos or rainbows around lights,

caused by the edema (swelling) of the cornea as it fills with fluid due to the excess pressure in the eye. The swollen cornea clouds slightly and begins to diffract the light entering the eye. The pupil is usually at a mid-dilated point and is pretty much stuck there while the pressure remains high. More than likely, the patient also experiences photophobia.

18. Glycerin, Timoptic, Betoptic, Pilocarpine, Diamox, or Mannitol.

19. Essentially burning a hole in the periphery of the iris with a YAG laser; provides another avenue for the aqueous humor to get from the posterior chamber to the anterior chamber and reduces the pushing forward of the iris by the fluid behind it.

20. Studies have shown that within 5–10 years of the initial attack, there is a 50–70 percent chance the patient will have another acute angle-closure attack in the other eye, so treating both eyes helps reduce another attack in either eye.

21. An obstruction of aqueous outflow through the trabecular meshwork.

22. Carry the visual signal from the eye toward the brain.

23. Because patients with relatively low IOP (21 mm Hg or lower) can still have the disease and patients with relatively high pressures (22 mm Hg or higher) can still be free of the disease.

24. VF loss.

25. Buphthalmos.

26. Be extremely sensitive to light, so much so his or her eyelids are tightly shut through the day; the eyes may tear profusely; and, most noticeably, the corneal hazing makes most parents suspect something is wrong.

27. Surgery.

28. A patient that shows signs of glaucoma (e.g., higher than normal IOP and changes to the optic disc), but no VF loss.

29. Hypotony.

30. A chronic intraocular inflammation (uveitis), wound leaks after an eye surgery, or the presence of a retinal detachment.

31. Elevated pressure within the skull.

32. A decrease in color vision, headache that is worse in the morning, vision loss for 10–30 seconds.

33. A hereditary, progressive retinal degeneration in both eyes.

34. RP is a disease of the rods.

35. Pigmentation clumps (bony spicules) forming on the retina, which is visible through ophthalmoscopy.

36. (1) Iris nevus.

(2) Choroidal nevus.

(3) Malignant melanoma.

(4) Retinoblastoma.

37. Any growth or changes in shape or size.

38. Malignant melanoma; retinoblastoma.

39. Only in the uveal tract.

40. Retinoblastoma.

41. A white pupillary reflex.

42. Eyes still having functional vision and localized tumors are given radiation therapy; in eyes no longer functioning visually or having an extremely large tumor, enucleation (removal of the eye) is the treatment of choice.

43. About 15.

44. A visual hallucination; a wave of electrical activity that spreads across the visual cortex.

45. (1) Common.

(2) Classical.

(3) Complicated.

(4) Cluster headaches.

46. Common.

47. Near fixation; periphery.

48. Complicated.

49. The incidence of permanent neurological deficits.

50. Ophthalmoplegic.

51. Basilar.

52. Any four from the following:

(1) Certain foods.

(2) Hormonal changes.

(3) Fatigue and stress.

(4) Bright lights.

(5) Loud noises.

(6) Trauma.

(7) Refractive error.

53. (1) Amsler grid.

(2) Automated VF.

---

## LESSON 3

---

### 218. War related ocular injuries

1. The source of injury.

2. Blasts (surrounding debris scattered secondary to explosion), mines, cluster bomblets, anti-tank missiles, grenades, bombs, booby-traps, bullets, and other related mechanisms.

3. Motor vehicle accidents, blunt traumas, falls, helicopter crashes, metal on metal, and other various means.

### **219. Non-war related ocular injuries**

1. Any object that is not part of the body.

2. The steel rusts in the eye and makes healing difficult.

3. Irrigation with a sterile saline solution.

4. The cornea may have been scratched.

5. Refer them to a surgeon for treatment.

6. The pressure patch could force aqueous or vitreous humor out of the eye.

7. Lay the patient on his or her back and gently transport the patient to surgical help.

8. If it goes across the visual axis (line of sight).

9. Ensure there is no FB in the eye, give the patient an antibiotic ointment, pressure-patch the patient for 12 to 24 hours (if needed), and then reevaluate the patient's eye.

10. (1) Glass.



(2) Plastic.

11. Keep the burned area moist.

12. Prolonged irrigation with sterile saline (minimum 30 minutes), or plain water if no saline solution is available.

13. Acids tend not to penetrate the eye; they make contact and burn what they touch, causing a barrier that slows or prevents further damage by the acid, so acids generally do not penetrate the underlying tissue as readily as alkalis do; and the tears of the eye have a pH on the alkali side of neutral that help prevent penetration into the eye.

14. Sodium, potassium, and ammonia.

15. Litmus (pH).

16. 7.3 – 7.7.

17. Sunburns it, degrading the corneal epithelium.

18. Infrared.

19. Cataracts, necrosis (death) of the skin, loss of lashes, and glaucoma.

20. Horizontal; it is going across (against) the levator palpebrae superioris, which can lead to permanent muscle damage and lid drooping (ptosis).

21. Prolapse of the intraocular tissues, vitreous hemorrhage, retinal detachment, dislocated lens, and various blood vessel ruptures.

22. Hyphema.

23. Besides reducing VA, they may plug up the trabecular meshwork and prevent maximum drainage of the aqueous, which could lead to a rise in IOP, inducing glaucoma.

24. Loosely cover the eye with a moist dressing to keep the ocular tissues from drying out, and get the person to a doctor immediately; do not try to “push” the eye back in the socket.

25. The drying out (desiccation) of the cornea because the lids may not be able to totally cover the eye due to the degree the eye is protruding.

26. After a blunt injury to an eye.

27. The eye is so compressed in the socket at the time of the blunt trauma that something has to give, and the weaker bones that are stressed literally “blowout” or fracture.

28. The eye is leaking out fluid.

#### **220. Purpose of eye irrigation**

1. To remove foreign objects or substances from the eye.

2. At a sink, shower, water hose, water fountain, or anywhere water is available.

3. Inability to open the eyelids due to a muscle spasm of the orbicularis oculi.

4. The use of a topical ophthalmic anesthetic.

5. Across the eye, going from the nasal side toward the temporal side; flushes the harsh chemicals away from the lacrimal drainage system, minimizing damage to it, and minimizes the amount of chemical being washed across the face.

### **221. Eye patching**

1. To keep the eyelids of the injured eye closed and help with pain control.
2. Removes the make-up and facial oils that prevent your tape from sticking to the patient.
3. Middle of the patch.
4. Minimize talking because it loosens the patch; no heavy exertion because it leads to sweating, causing the patch to loosen or fall off; no driving, if at all possible, because stereopsis (fine-tuned depth perception) is lost, as well as a substantial portion of the VF on the patched side.
5. Return to the clinic to have a new one applied; if it is after duty hours, leave the patch off and keep the eye closed as much as possible.

### **222. Ocular emergencies**

1. (1) Chemical burns.  
  
(2) CRAO.  
  
(3) Penetrating injuries to the globe.  
  
(4) Sudden loss of vision.
2. Urgent.

### **223. Emergency ocular conditions**

1. CRAO.

2. Because the symptoms for CRAO are similar to other conditions, any patient who complains of sudden vision loss in one eye must be treated as an emergency case and requires appropriate immediate prioritization.

#### **224. Urgent ocular conditions**

1. If the eye is left untreated, the cornea may eventually scar. In some cases the scarring may be severe enough to warrant a corneal transplant.

2. Retinal detachment.

#### **225. Priority ocular conditions**

1. Within the next few days.

2. Headaches may be a symptom of serious neurologic or systemic disorder. Many brain tumors are first noticed in ocular assessments.

3. Uncorrected refractive error.

---

## LESSON 4

---

## 226. General principles of ophthalmic pharmacology.

1. The pH of the drug.
2. Isotonic.
3. A patient with dry eyes.
4. (1) Keep non-preserved saline refrigerated.  
  
(2) Avoid touching the dispensing portion of the container to anything.
5. Preservative-free drugs. For eye surgery, individual sterile dose units are utilized.
6. Heat and light.
7. The medication in the bottle is brown or the threads on the bottle are a little brown.
8. (1) Increase dosage.  
  
(2) Increase frequency.  
  
(3) Increase the viscosity.  
  
(4) Increase contact time with the cornea.
9. Those not soluble in fat (can't get through epithelial layer) and those not soluble in water (can't get through the remaining layers).
10. Topical application; subconjunctival, sub-tenon's, retrobulbar, and intravitreal injections; continuous release delivery; and systemically.

11. Solutions, suspensions, ointments, and continuous release delivery.
12. Plug the punctal area by gently squeezing in the nasal canthus for about 1 minute.
13. 24 hours a day for seven days.
14. Orally or by injection.
15. Under the skin; in a muscle; into a vein.

#### **227. Complications and actions of ophthalmic drugs**

1. Allergic response; moderate swelling and redness to convulsions and death.
2. No; their previous exposure may have allowed them to develop a hypersensitivity to the drug so they may react to it this time.
3. Stop instilling the drug, recline the patient if possible, and get a doctor for assistance.
4. Death, destruction, or changes to tissue (e.g., formation of deposits or discoloration).
5. Take a good case history.
6. Actual drug name, drug percentage, the word "ophthalmic", manufacturer's expiration date, and the date the medication was opened (if the manufacturer's seal has been removed).

#### **228. Autonomic medications and the body's nervous system**

1. The brain and spinal cord.

2. (1) ANS.

(2) Somatic nervous system.

3. (1) Sympathetic nervous system.

(2) Parasympathetic nervous system.

4. Mimetics mimic certain actions of the sympathetic or parasympathetic nervous system; lytics paralyze certain actions of the sympathetic or parasympathetic nervous system.

#### **229. Mydriatic and cycloplegic medications**

1. To dilate the eyes to allow the doctor to perform a thorough exam of the posterior portion of a patient's eyes; a big pupil allows a wider field of view and gives the examiner a chance to see the vast majority of the retina.

2. 2.5 percent; it provides the desired mydriatic effect without significantly increasing blood pressure, causing headaches, or even death like the 10 percent concentration can.

3. Cocaine.

4. (1) Ptosis.

(2) Miosis.

(3) Anhidrosis (dry skin) on one side of the face.

5. (1) Tropicamide—to produce mydriasis and cycloplegia for routine fundus exams.

(2) Cyclopentolate—cycloplegic refractions for use in Flying Class 1 and 1A physical examinations.

(3) Homatropine—produces extended mydriasis and cycloplegia that may last up to 72 hours; commonly used for patients with iritis to stop ciliary spasms and prevent synechiae. (4) Atropine—for refraction in children; not used much anymore due to numerous side effects.

6. Heightened photosensitivity and lack of accommodation.

### **230. Anti-glaucoma/intraocular pressure lowering medications**

1. They slow the production of aqueous humor by blocking the beta-1 (cardiac receptors) and beta-2 (pulmonary receptors) functions within the eye.

2. For an asthmatic patient because Betoptic selectively blocks beta-1 (cardiac receptors), but not the beta-2 (pulmonary receptors), making it a better choice in patients with breathing problems.

3. It has a longer half-life than Timoptic or Betoptic, earning it FDA approval for once-a-day use, as opposed to the required twice-a-day application of the other beta-blockers; using less medication helps keep the cost down and patient's compliance in taking their medication up.

4. When beta-blockers do not lower IOP enough by themselves or patients require specific treatment that works on the outflow of aqueous humor rather than just slowing its production.

5. Miosis (constriction of the pupil), stimulation of accommodation, and brow ache.

6. Patients with anterior uveitis (e.g., iritis).

7. Pilocarpine.

8. The medication over penetrates into the eye.



9. The formation of iris cysts (especially in children).
10. Physostigmine Salicylate (Eserine).
11. Can be used to treat children with accommodative (convergent) esotropia and are irreversible.
12. Carbonic anhydrase inhibitors.
13. Acetazolamide (Diamox).
14. Methazolamide (Neptazane) should be avoided in patient's undergoing steroid treatment.
15. Lowering IOP quickly on patients who report with an acute-angle closure glaucoma attack.
16. Not for use on diabetic or dehydrated patients, nor on those with heart, kidney, or liver disease.
17. Intravenously.

### **231. Ophthalmic anesthetic medications and stains**

1. (1) Topically.  
  
(2) Through injection.
2. (1) Applanation (Goldmann) tonometry.  
  
(2) Schirmer II tear test.
3. (1) Allow placement of a Morgan Lens (if irrigation is needed).

(2) Relieve any blepharospasm caused by the injury.

4. It causes a softening of the corneal epithelial cells. The soft, loose cells slough off, exposing Bowman's layer, inviting infection and corneal ulceration. It can actually cause a toxic reaction in the cornea causing cell damage.

5. They could cause damage to the eye by rubbing it too hard or rubbing a foreign object into their cornea.

6. (1) Proparacaine.

(2) Benoxinate with fluorescein.

(3) Tetracaine.

7. (1) Very few complications with its use.

(2) It's the least irritating of the topical anesthetics.

8. Goldmann applanation tonometry.

9. It burns and stings, and has also been known to cause an allergic reaction in some patients.

10. 20 minutes.

11. Contamination by the pseudomonas aeruginosa bacteria.

12. Dry, filter paper strips impregnated with fluorescein, called Fluor-I-strips.

13. (1) Perform applanation (Goldmann) tonometry.

(2) Show defects in the corneal epithelium.

(3) Detect penetrating injuries to the eye.

(4) Fit gas permeable CLs.

(5) Study lacrimal patency.

(6) Perform FA.

14. UV or cobalt blue light.

15. Red; devitalized or dead epithelial cells of the cornea and conjunctiva.

16. Keratoconjunctivitis sicca (dry eyes).

17. An anesthetic.

### **232. Anti-allergic, anti-inflammatory, and anti-infective ophthalmic medications**

1. Mild allergic conjunctivitis.

2. Helps block the itching and break up the mucus.

3. Vasoconstrictors and antihistamines.

4. Prevents the release of histamines, prostaglandins, and leukotrienes from sensitized mast cells; chronic allergic problems (e.g., seasonal allergic conjunctivitis, often called vernal conjunctivitis).

5. Inflammation; inhibiting prostaglandin synthesis.

6. Cataract surgery patients for a few days after their operation; it doesn't lead to IOP increases like most steroidal drugs.

7. The doctor sliding instruments in and out of the eye irritates the iris, which causes inflammation that leads to miosis; Flurbiprofen (Ocufen) or suprofen (Profenal).

8. To control inflammation due to seasonal (vernal) allergic conjunctivitis.

9. 0.125 to 1 percent; the 0.125 percent is good where mild adnexa inflammation control is needed (e.g., early allergic conjunctivitis), and the 1-percent concentration is used for corneal inflammations (keratitis), episcleritis, iritis, and similar conditions.

10. Dexamethasone.

11. When treating long-term inflammations (those that can last three to four weeks or more) (e.g., SPK and some ocular allergies).

12. In cases where the inflammatory response is secondary to compromised eye tissue (i.e., chemical keratitis with significant epithelial compromise).

13. (1) Bacteriostatic.

(2) Bacteriocidal.

14. It helps the doctor pick an antibiotic appropriate to the type of bacteria because certain antibiotics are more effective on gram-positive bacteria and some are better on gram-negative.

15. 24–48 hours.

16. Involves the doctor using a broad-spectrum antibiotic that fights many different types of bacteria until the specific bacteria and what types of drugs affect it is known.

17. *Pseudomonas aeruginosa*.

18. Patients failing to use their antibiotics for the prescribed length of time; they stop when things seem to clear up and the remaining bacteria make a comeback, becoming more resistant to the prescribed medication.

19. Endophthalmitis; orbital cellulitis.

20. Treating the staphylococcal form of blepharitis (staph lid disease).

21. Many patients are allergic to sulfa drugs; it doesn't work well against staphylococcal organisms or *pseudomonas*; and it doesn't work well on mucopurulent infections.

22. (1) As a prophylactic (preventative) antibacterial when a pressure patch is used on a corneal abrasion.

(2) On sutures and surgical wounds after blepharoplasty (eyelid) surgery.

(3) On newborns, as a prophylaxis against gonorrhea and chlamydial infection.

23. (1) Gentamicin.

(2) Tobramycin.

24. Polymixin-B.

25. (1) Neomycin.

(2) Trimethoprim.

26. The fluoroquinolones.

27. Treating moderate to severe external bacterial infections; the most common use thus far is in treating corneal ulcers caused by bacterial organisms.

28. Viruses actually penetrate inside the cell they are infecting; bacteria and fungi are only next to the cell they are infecting.

29. (1) ADV.

(2) HSV.

(3) HZV.

30. The ADV.

31. It invades the cells of the corneal epithelium, causing dendritic ulcers that expose the lower corneal layers.

32. They can be toxic to healthy tissue.

33. (1) Idoxuridine (IDU).

(2) Vidarabine (Vira-A).

(3) Trifluridine (Viroptic).

(4) Acyclovir (Zovirax).

34. Trifluridine (Viroptic).

35. Acyclovir (Zovirax).

36. Natamycin or pimaricin (Natacyn); Candida, Aspergillus, Cephalosporium, Fusarium, and Penicillin.

### 233. Ophthalmic health enhancing products

1. Preservatives can cause an allergic reaction in certain patients.
2. As the phenylephrine in the drops wear off, the body starts to counteract the drug's effect with vasodilation, and the redness is worse than before the person used the drops--a vicious cycle.
3. Breaks down accumulated toxins, dead cells, and waste products; damages healthy cells through a process called oxidation.
4. (1) May help to prevent cataract formation.  
  
(2) Protects against ARMD.  
  
(3) Helps restore and maintain tear formation and eye lubrication.
5. Eat a well-balanced diet rich in green leafy vegetables, take a supplement (it couldn't hurt), stop smoking (especially important for those with ARMD), wear sunglasses outdoors, and exercise on a daily basis.

**This is the end of the answers to the self-test questions. Click  
here to exit to the module table of content.**